



Diagnostic Immunohistochemistry: Breast

Rohit Bhargava, M.D.

Magee-Womens Hospital

University of Pittsburgh Medical Center (UPMC)

Pittsburgh, PA 15213

Kolkata, India

January 5, 2018

Outline

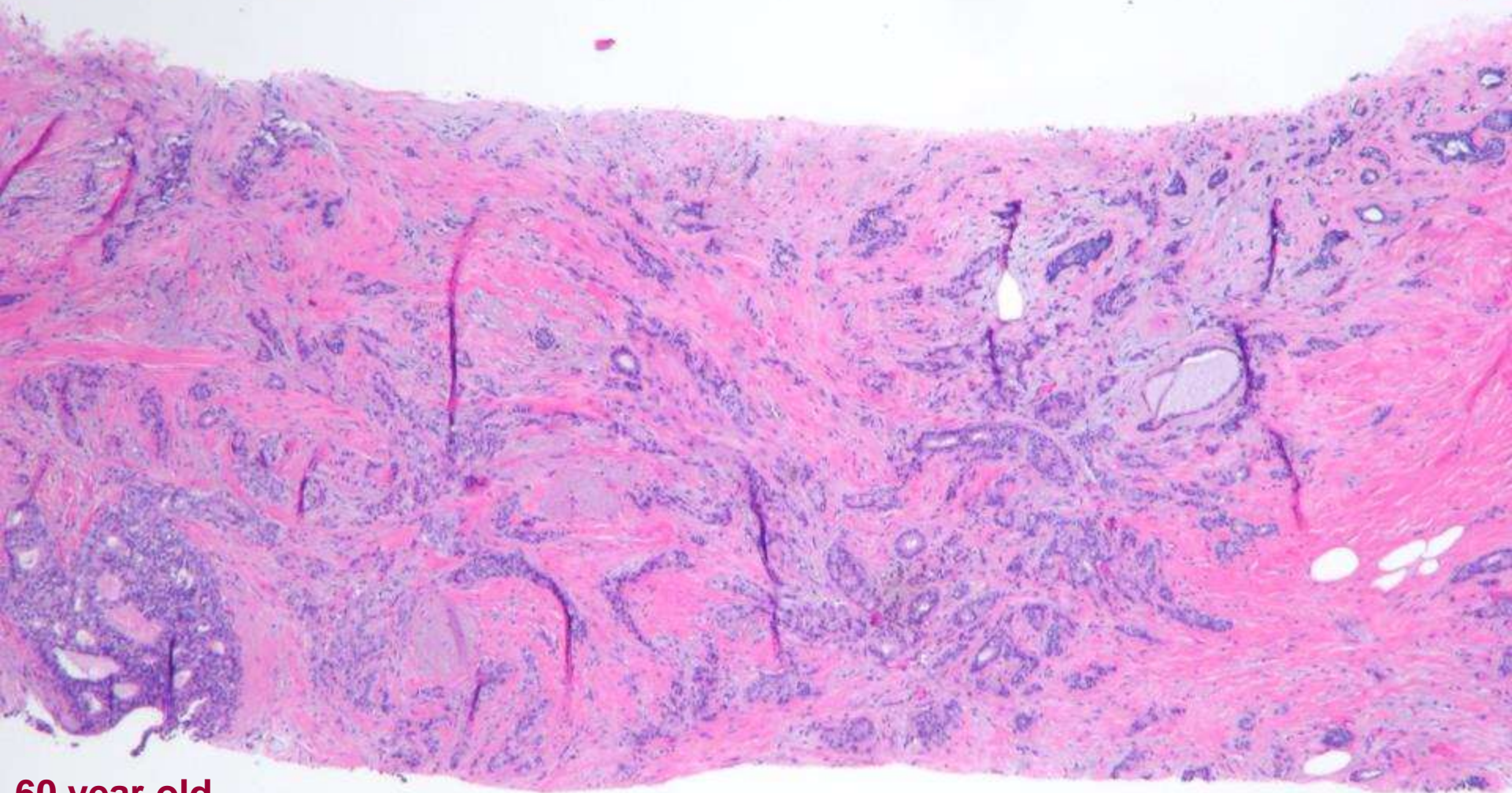
- Diagnostic Issues
 - Assessment of invasion
 - IHC to diagnose ADH
 - Papillary lesions
 - Ductal versus lobular
 - Spindle cell lesions
 - Paget's disease
 - Lymphatic space invasion
 - Breast carcinoma at metastatic sites

Assessment of Invasion

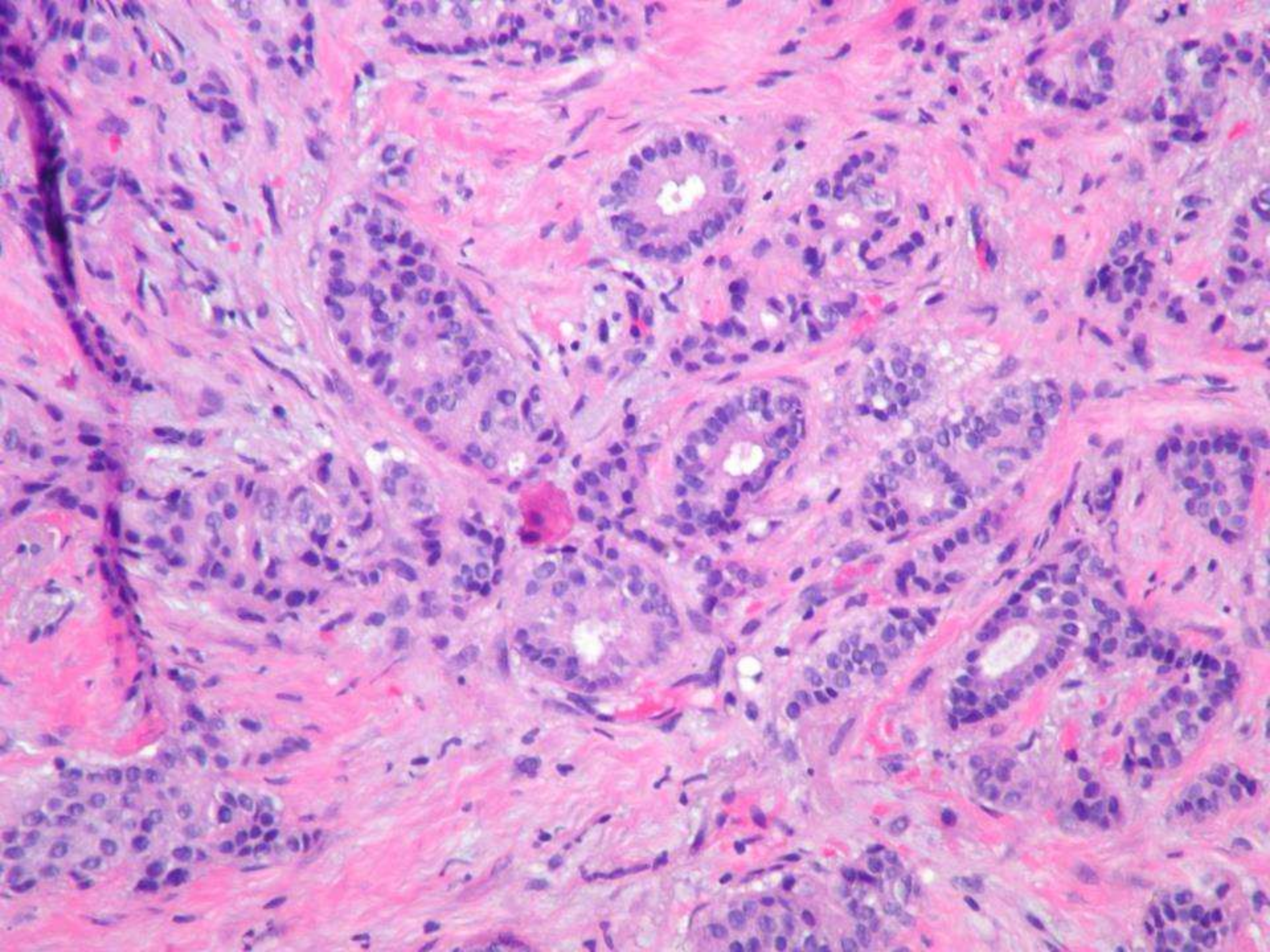
- Immunohistochemical (IHC) stains often used on core biopsy specimens
- Diagnosis of invasive carcinoma prior to definitive excision procedure changes management
- IHC stains supplement the morphologic diagnosis

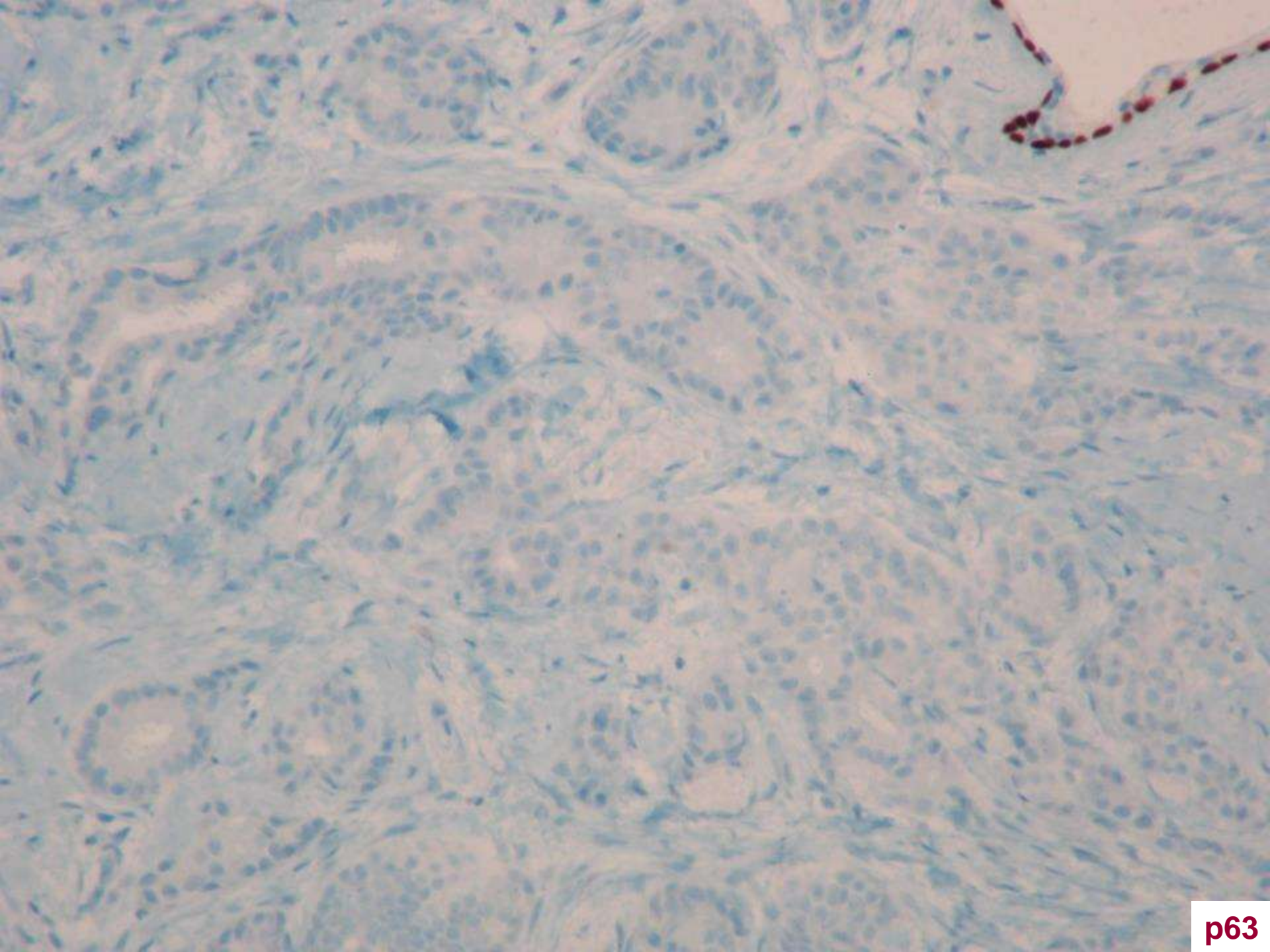
Assessment of Invasion

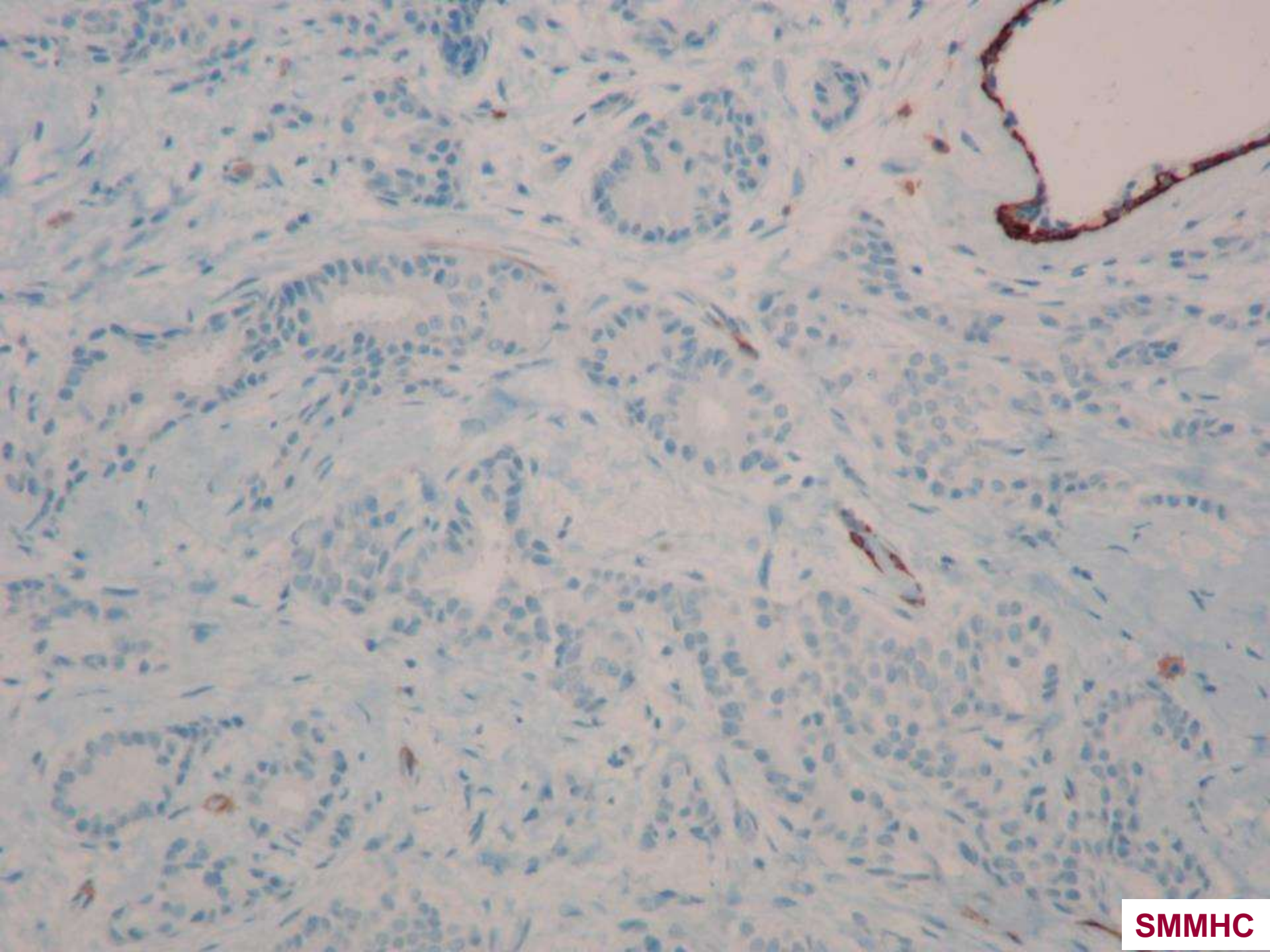
- When do we need the stains?
 - To support the morphologic diagnosis when the lesion is minute especially in a core biopsy
 - Sclerosing lesions versus invasive carcinoma
 - Cribriform DCIS versus invasive cribriform carcinoma
 - Presence of extensive inflammatory infiltrate
- Markers available
 - p63, smooth muscle myosin heavy chain, calponin, SMA, CD10, high molecular weight keratins, maspin, S100, 14-3-3sigma, nestin, p-cadherin

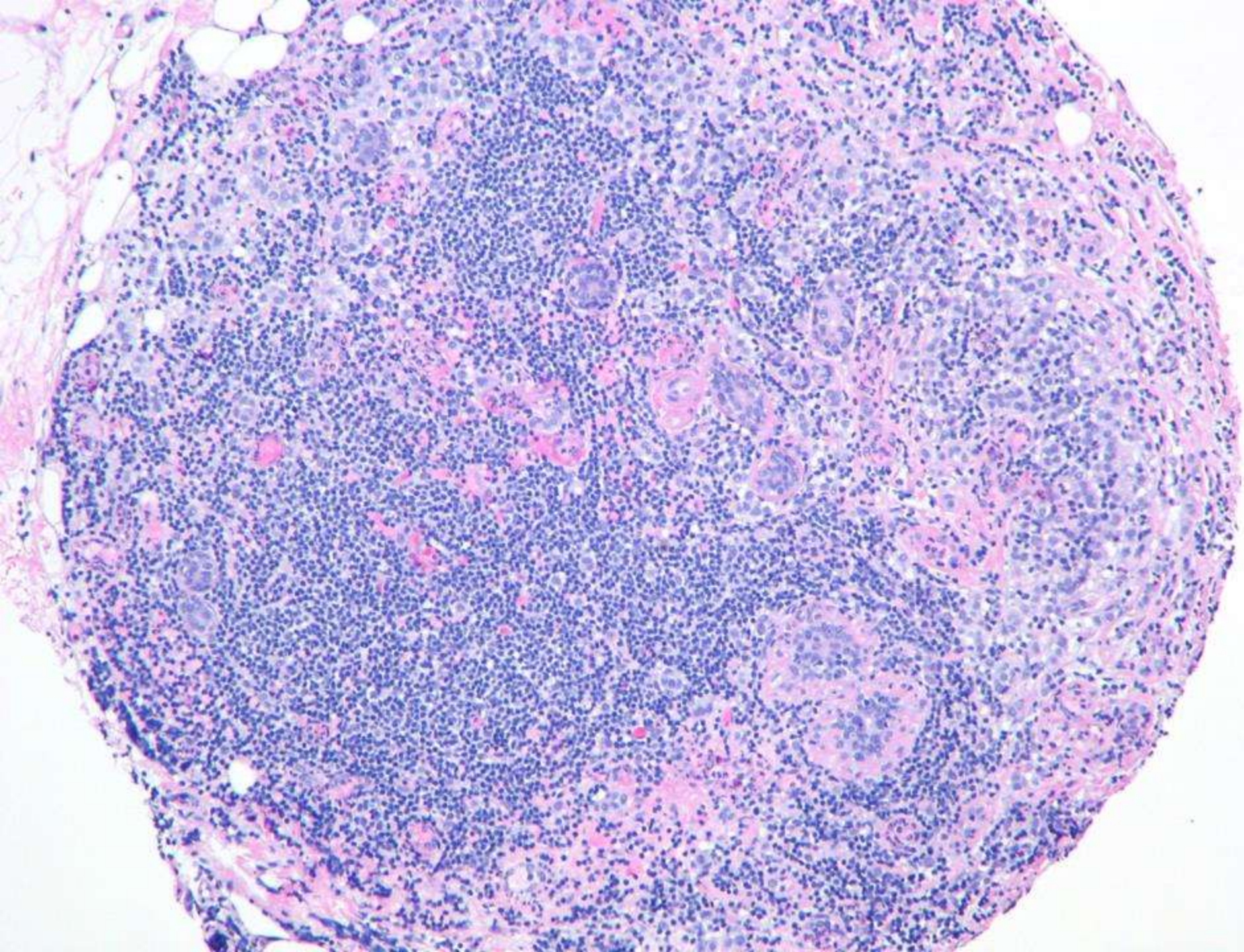


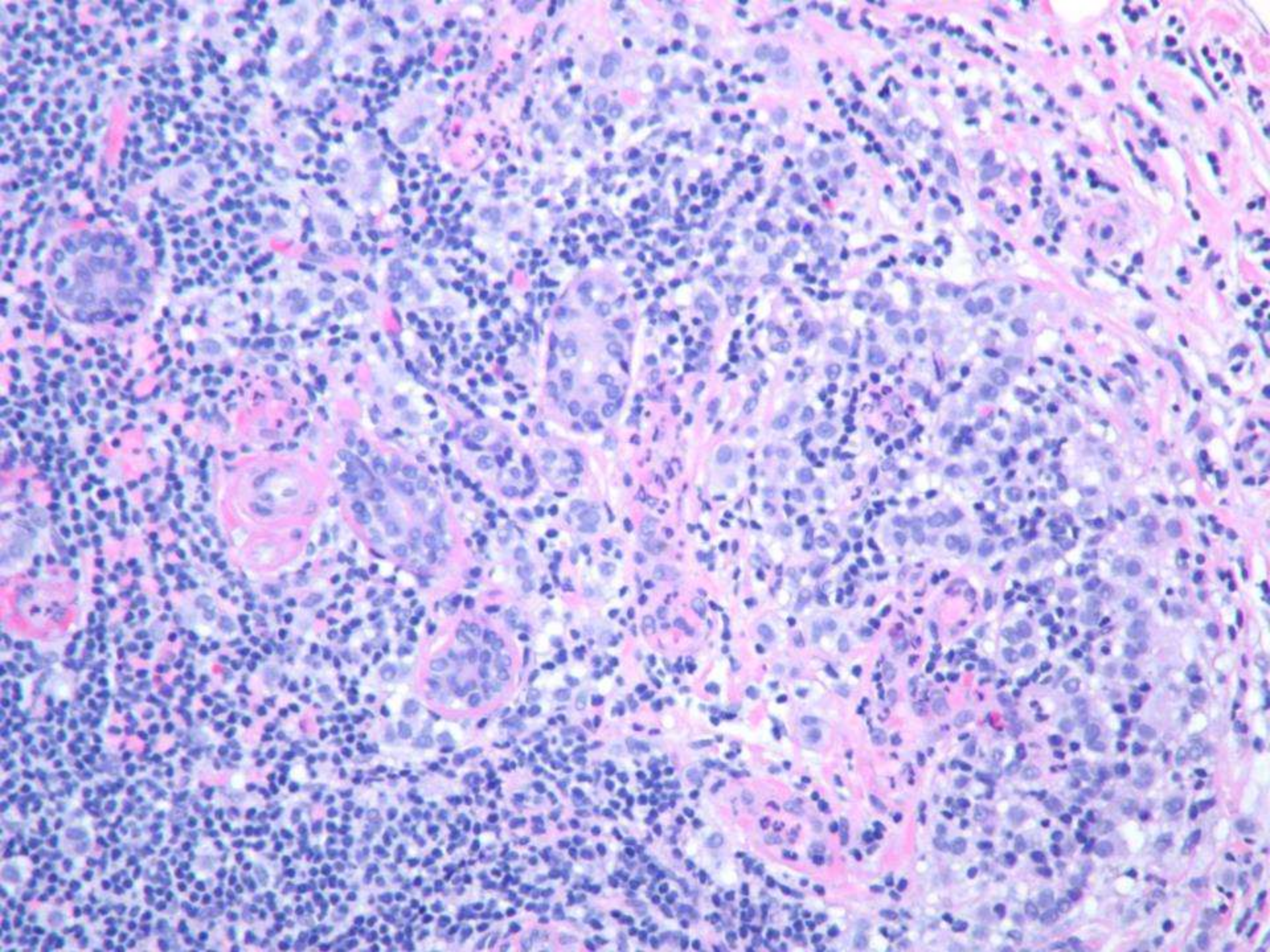
60 year old
5 mm mass
Radial scar versus carcinoma
US guided core bx

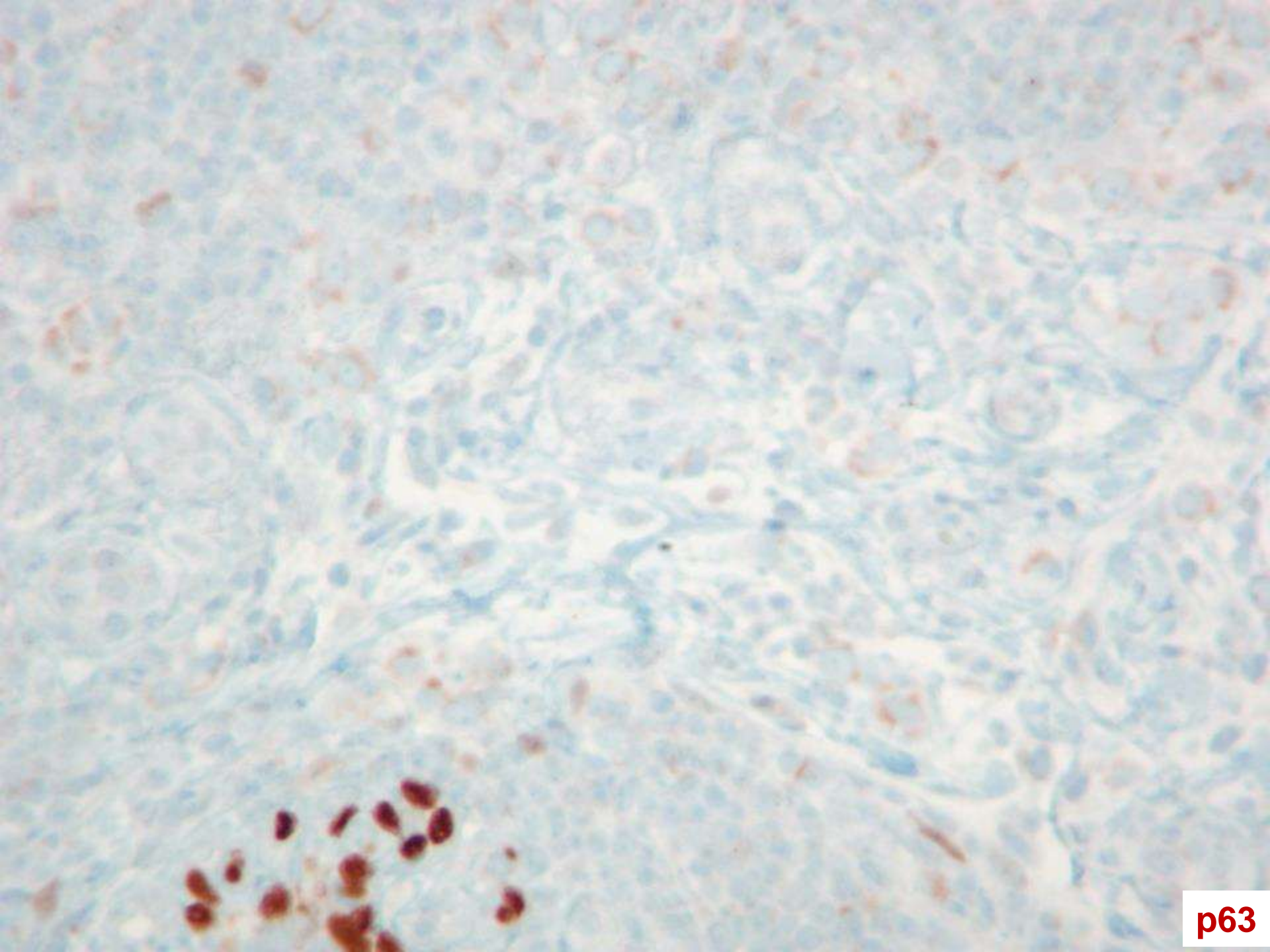


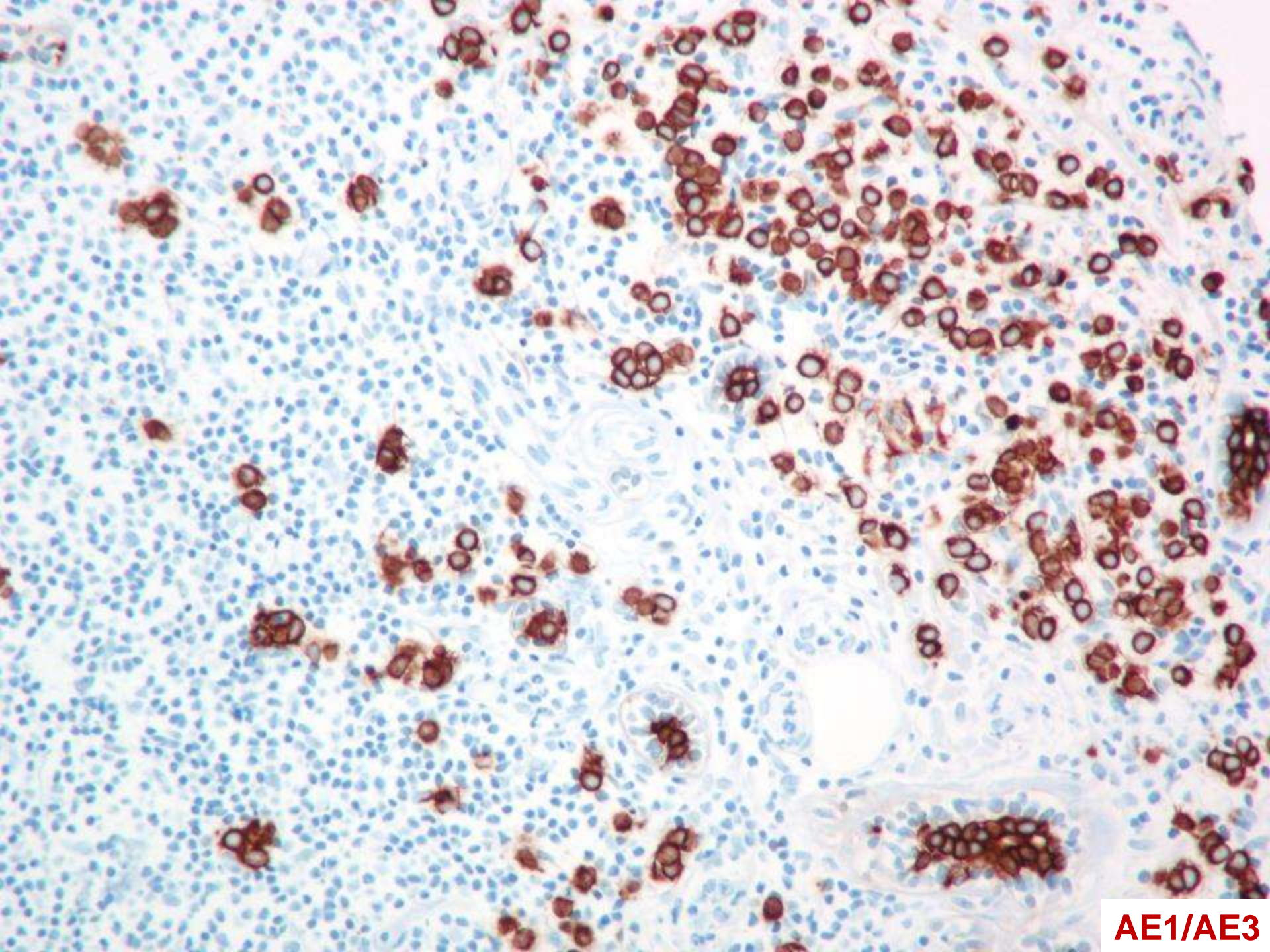






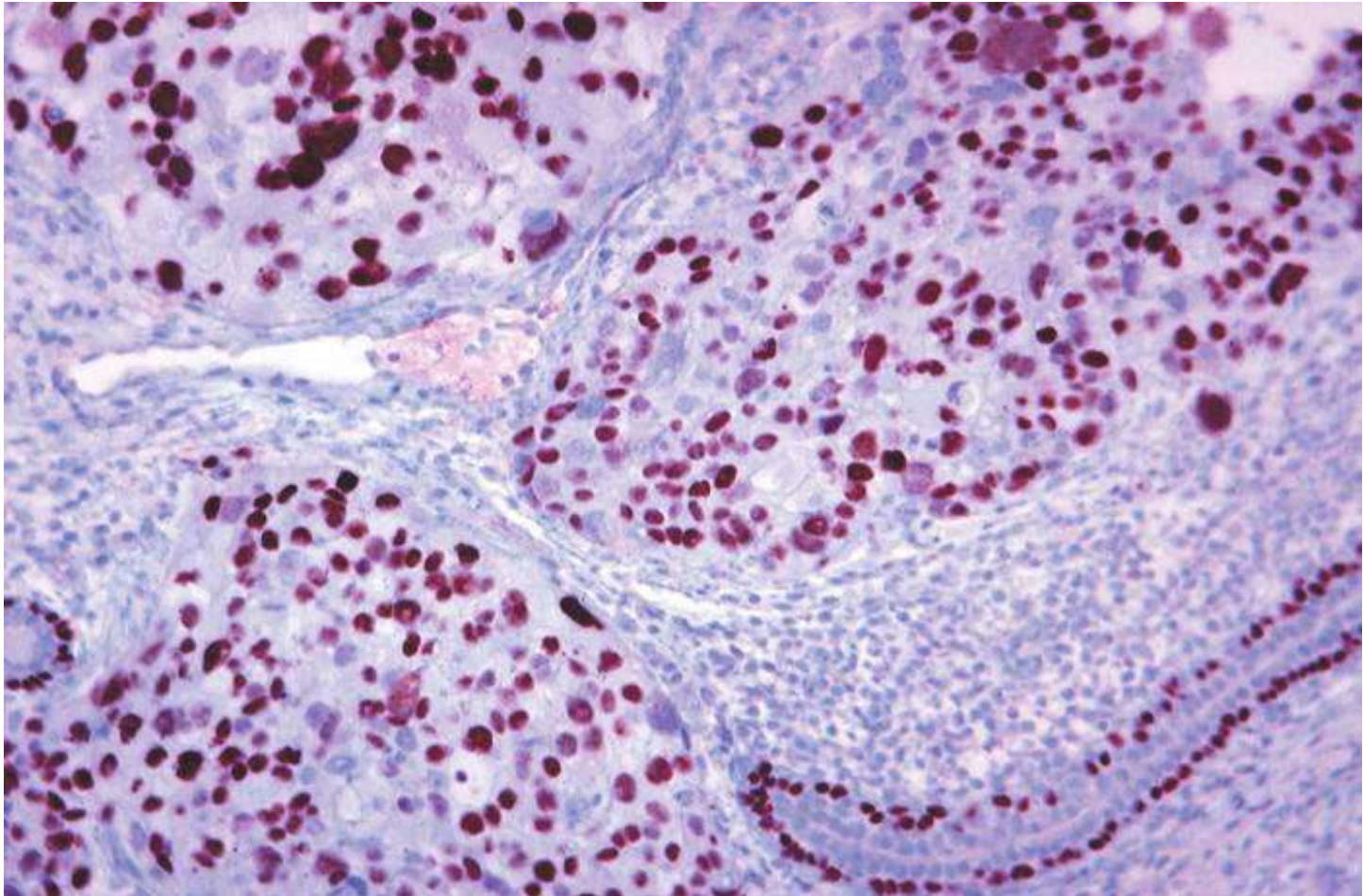






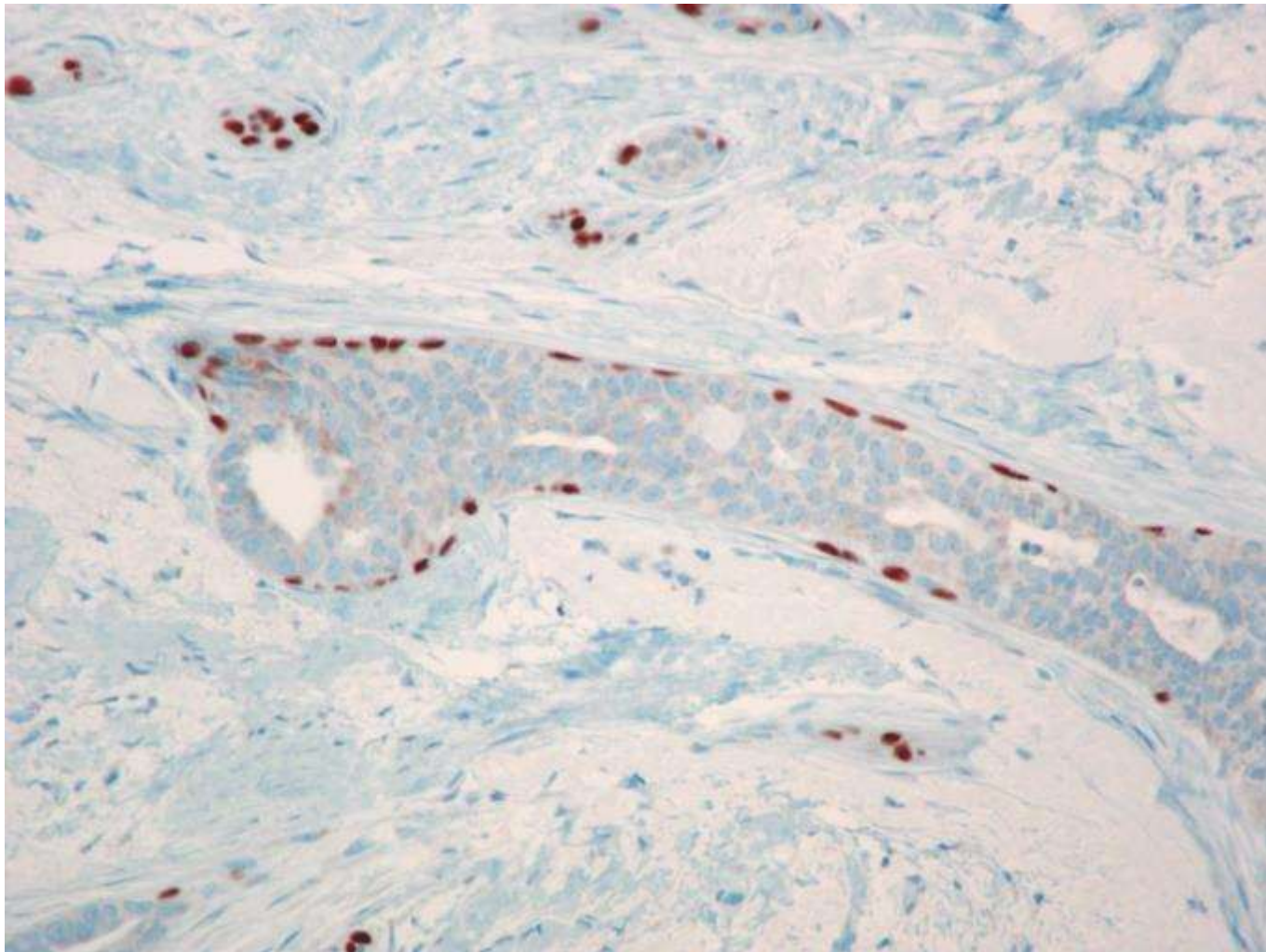
AE1/AE3

Pitfalls-p63



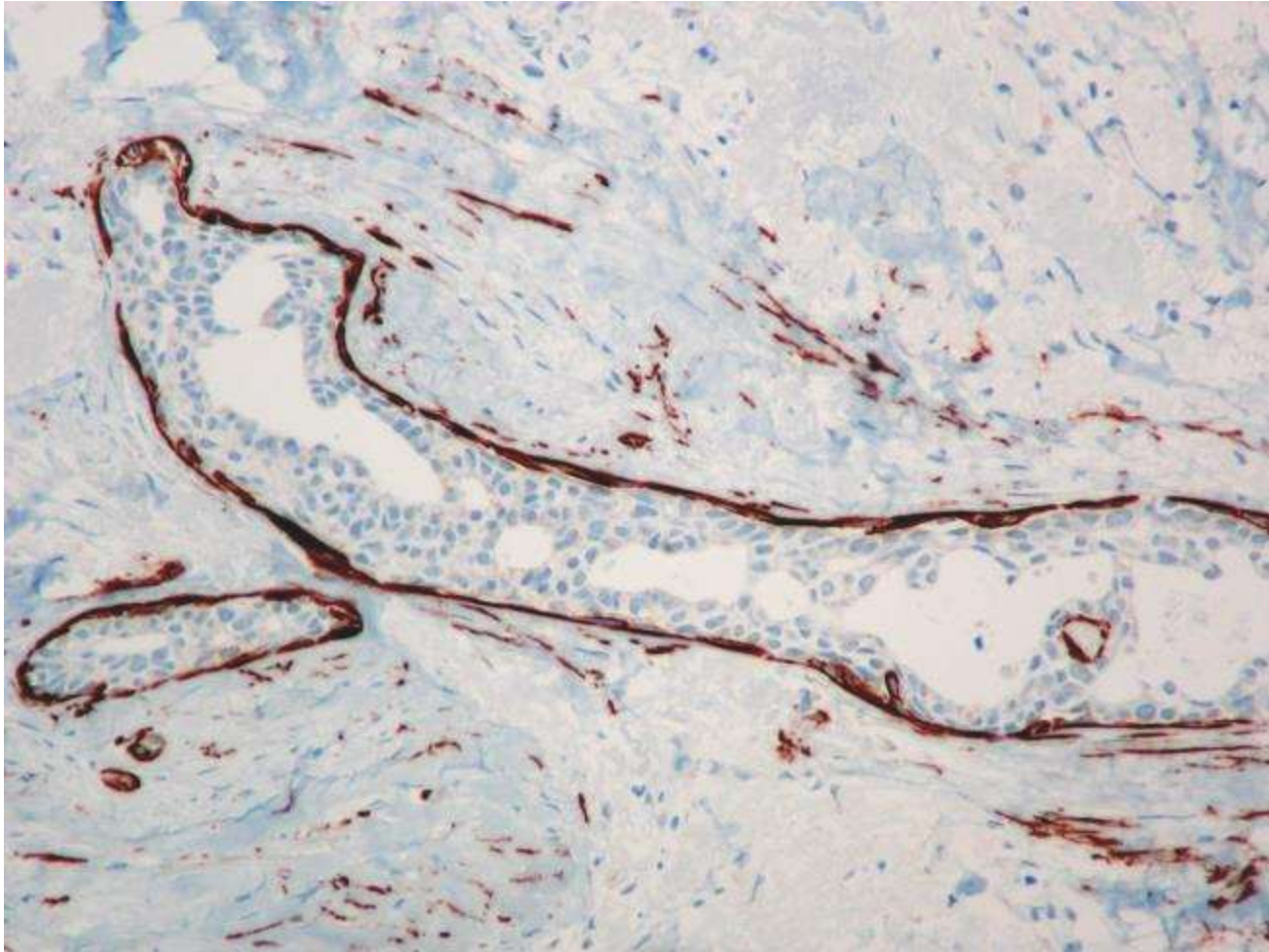
Staining of neoplastic epithelium-an extreme example

Pitfalls-p63

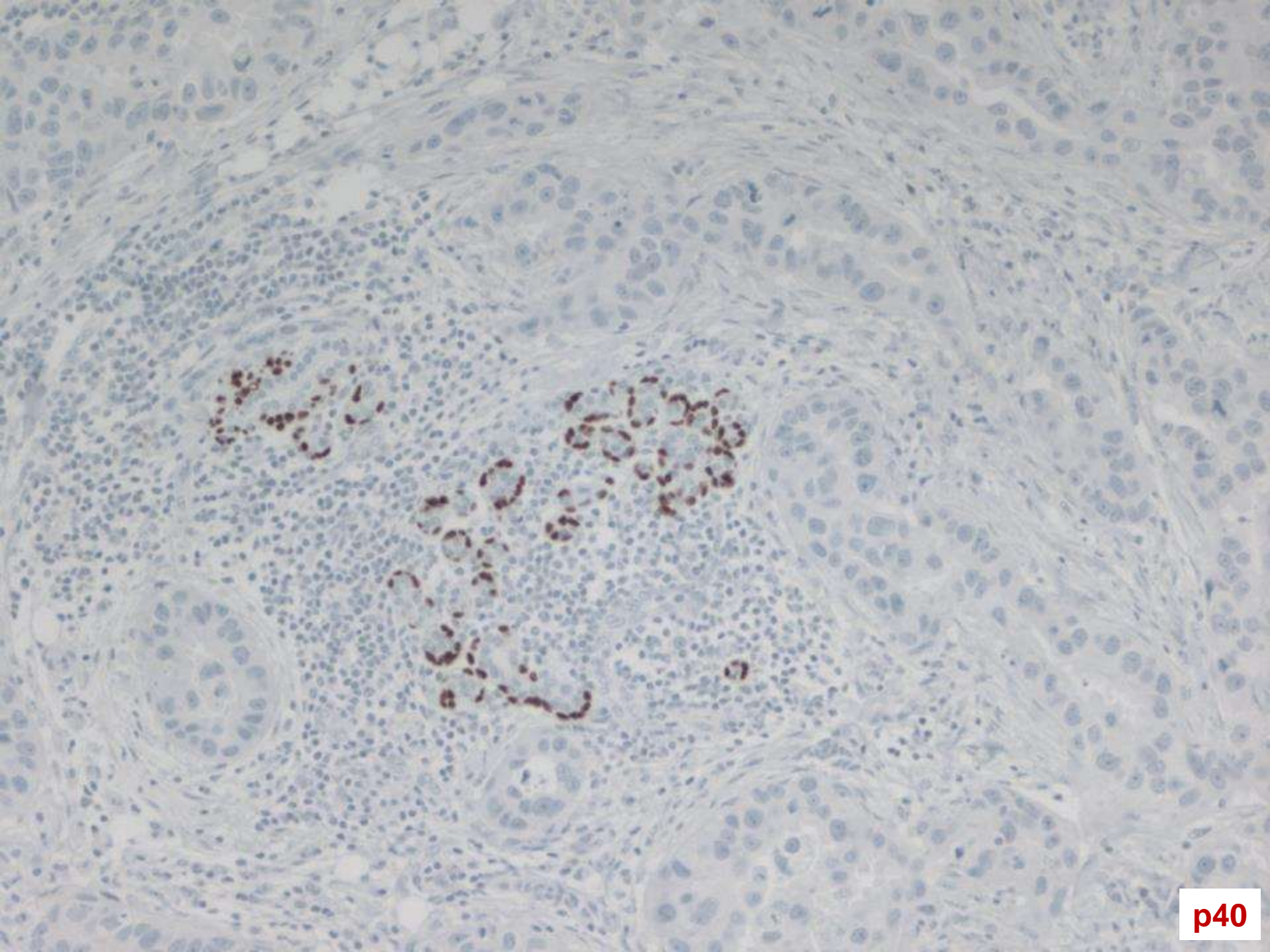


Apparent gaps in staining

Pitfalls-SMMHC



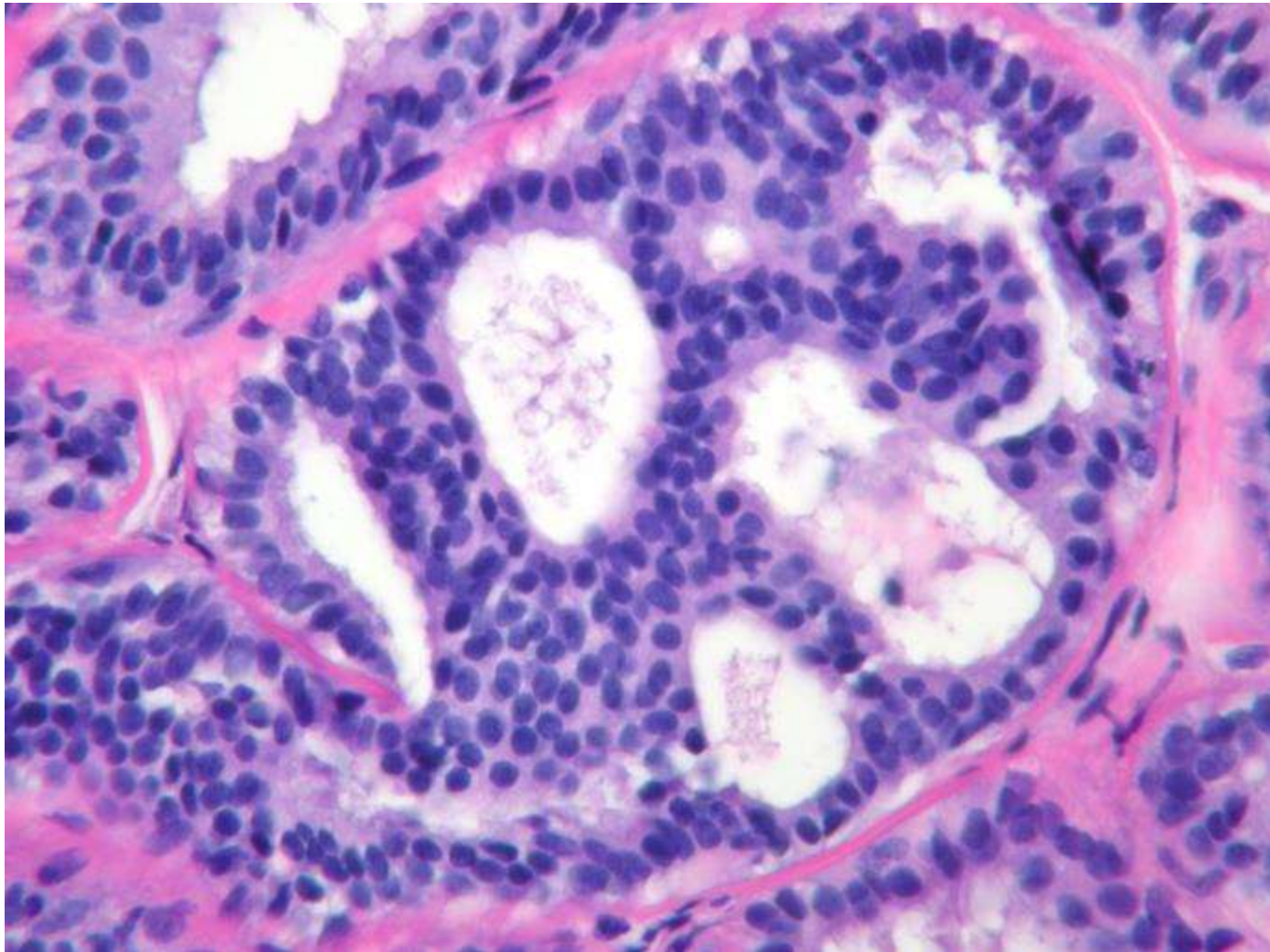
Staining of myofibroblasts

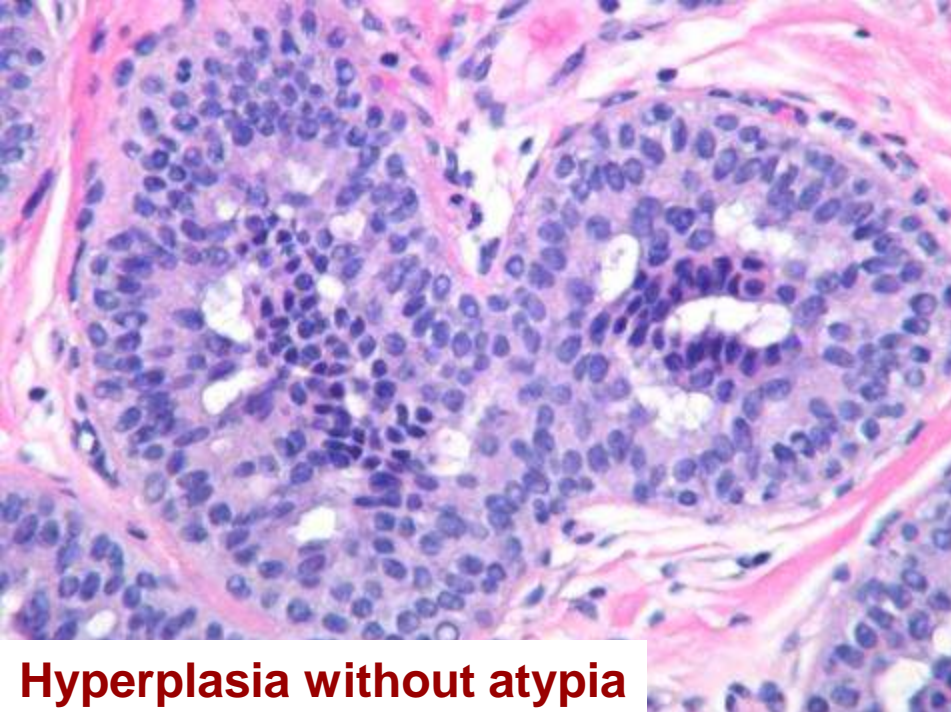


Assessment of Invasion

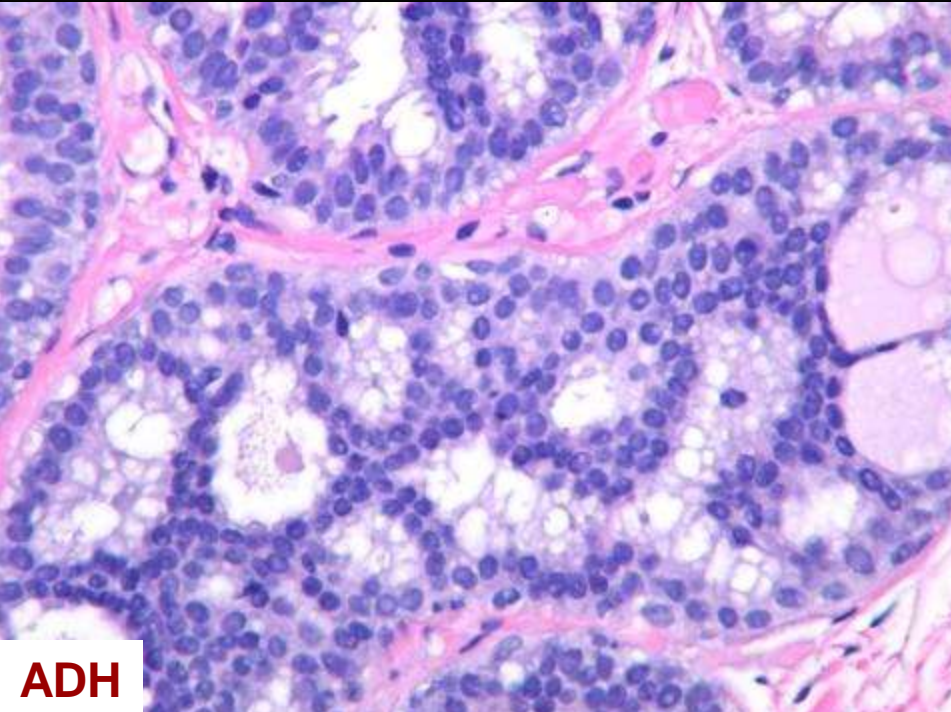
- Summary
 - Combination of p63 (nuclear) and smooth muscle myosin heavy chain (cytoplasmic) is superior to any other antibody
 - p40 staining in breast is similar to p63
 - Stains can accurately predict invasion even in core biopsies

Immunohistochemistry and ADH



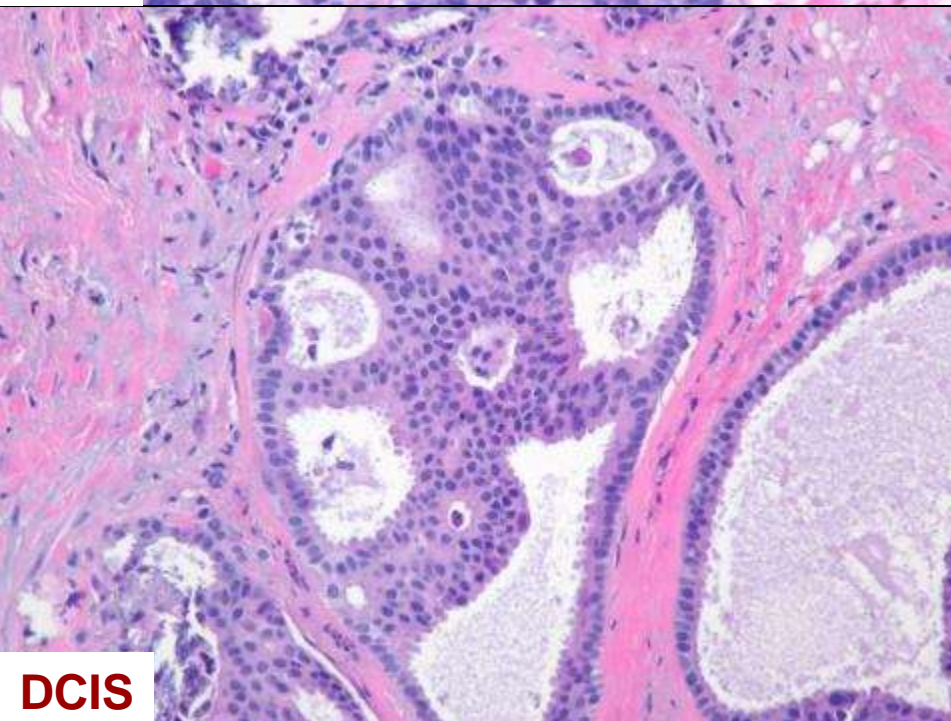


Hyperplasia without atypia

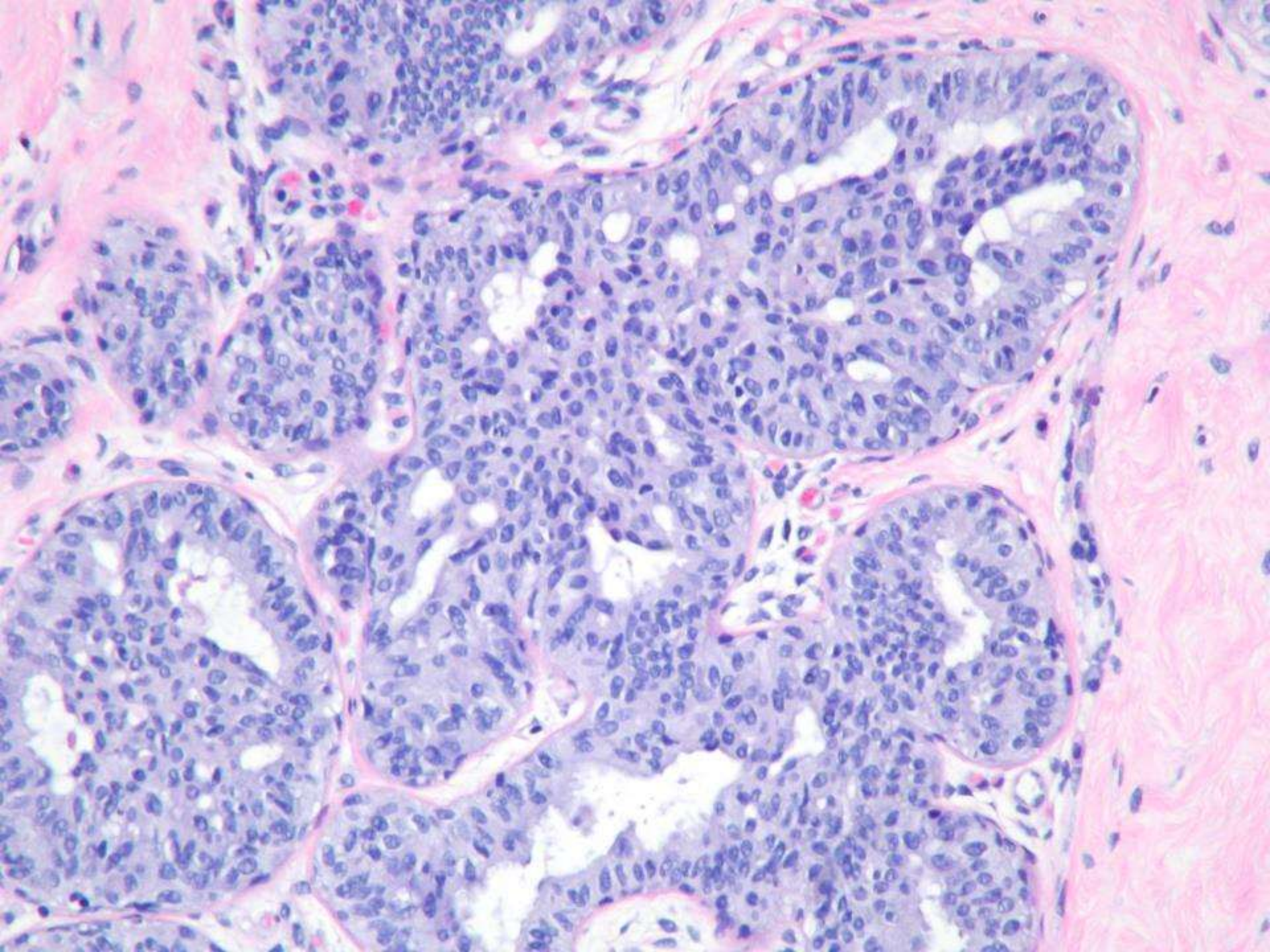


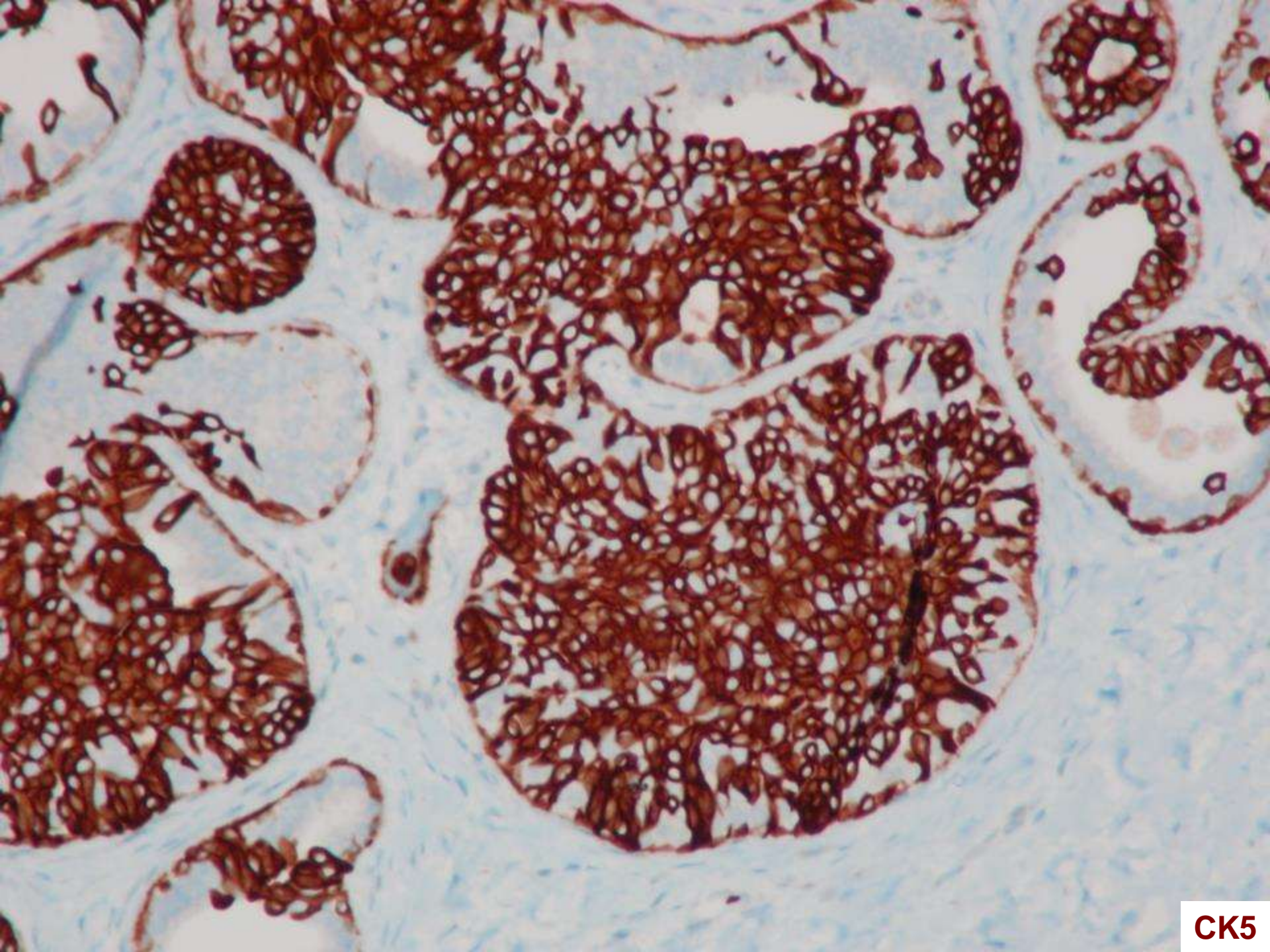
ADH

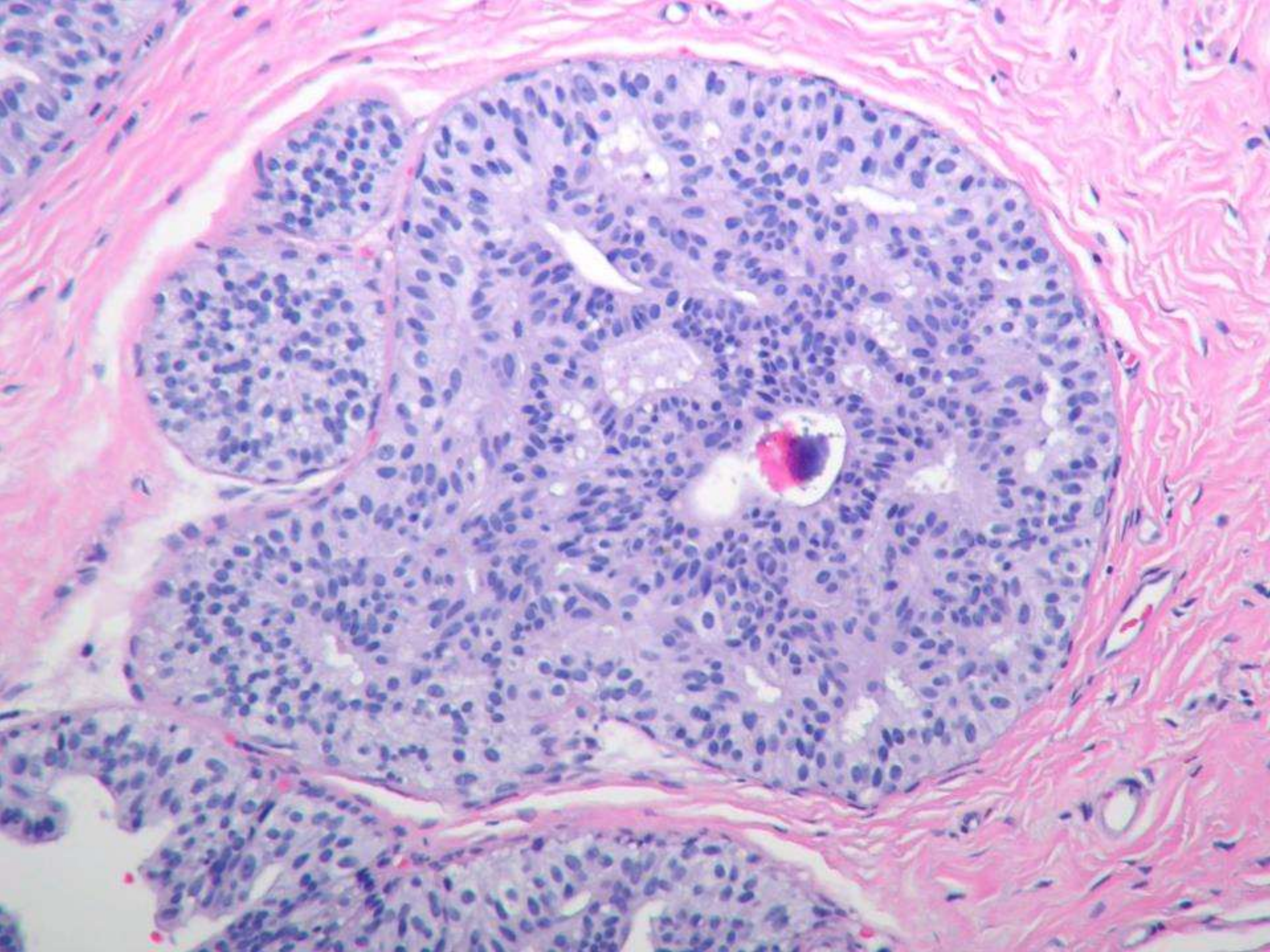
UDH: Streaming present
 ADH: Architecturally complex
 Cytologic atypia present
 Falls short of DCIS
 DCIS: Fulfills all criteria; One of the
 known architectural patterns
 cribriform, micropapillary, solid,
 papillary with or without necrosis
 Cytologic atypia also present

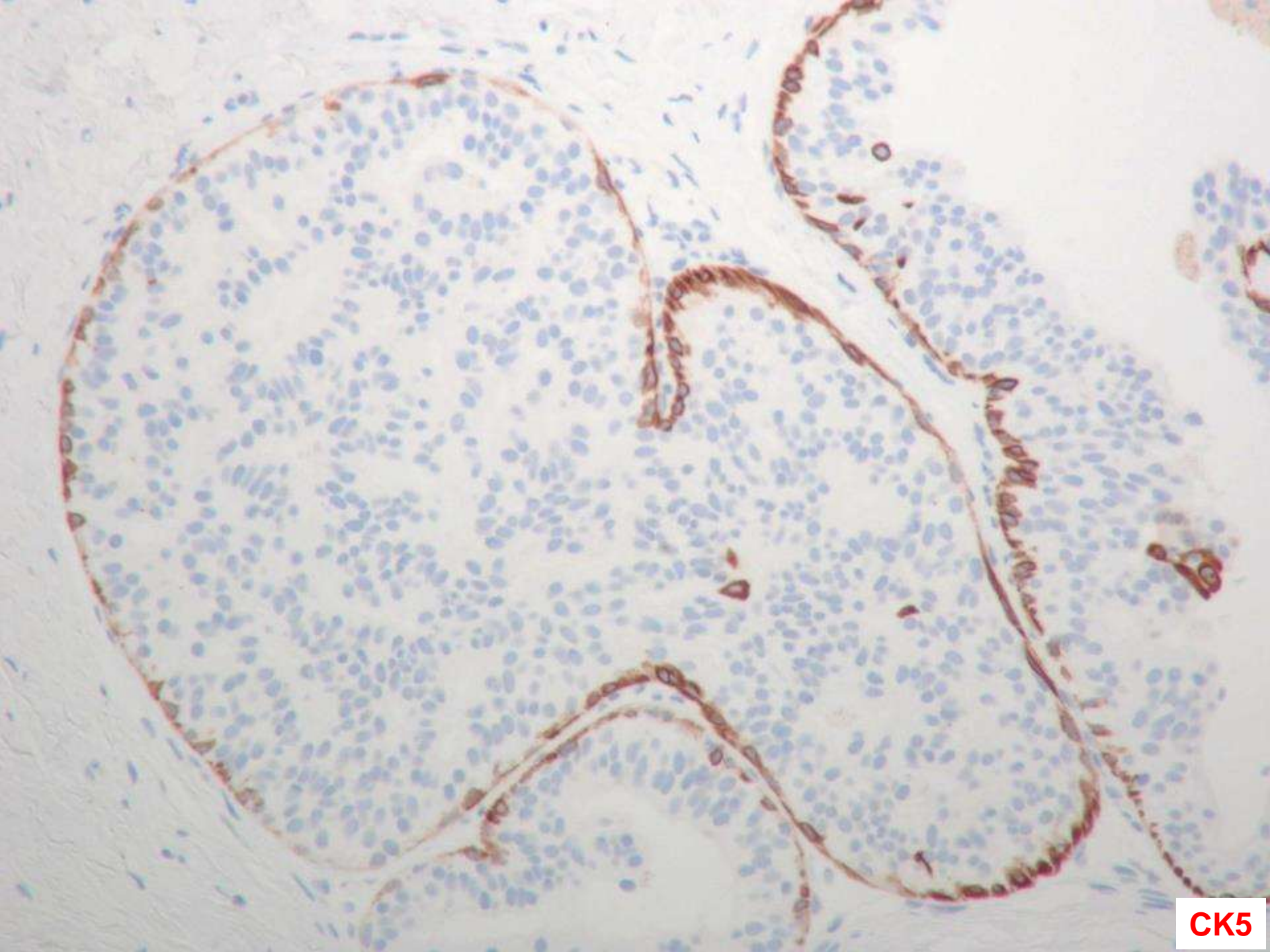


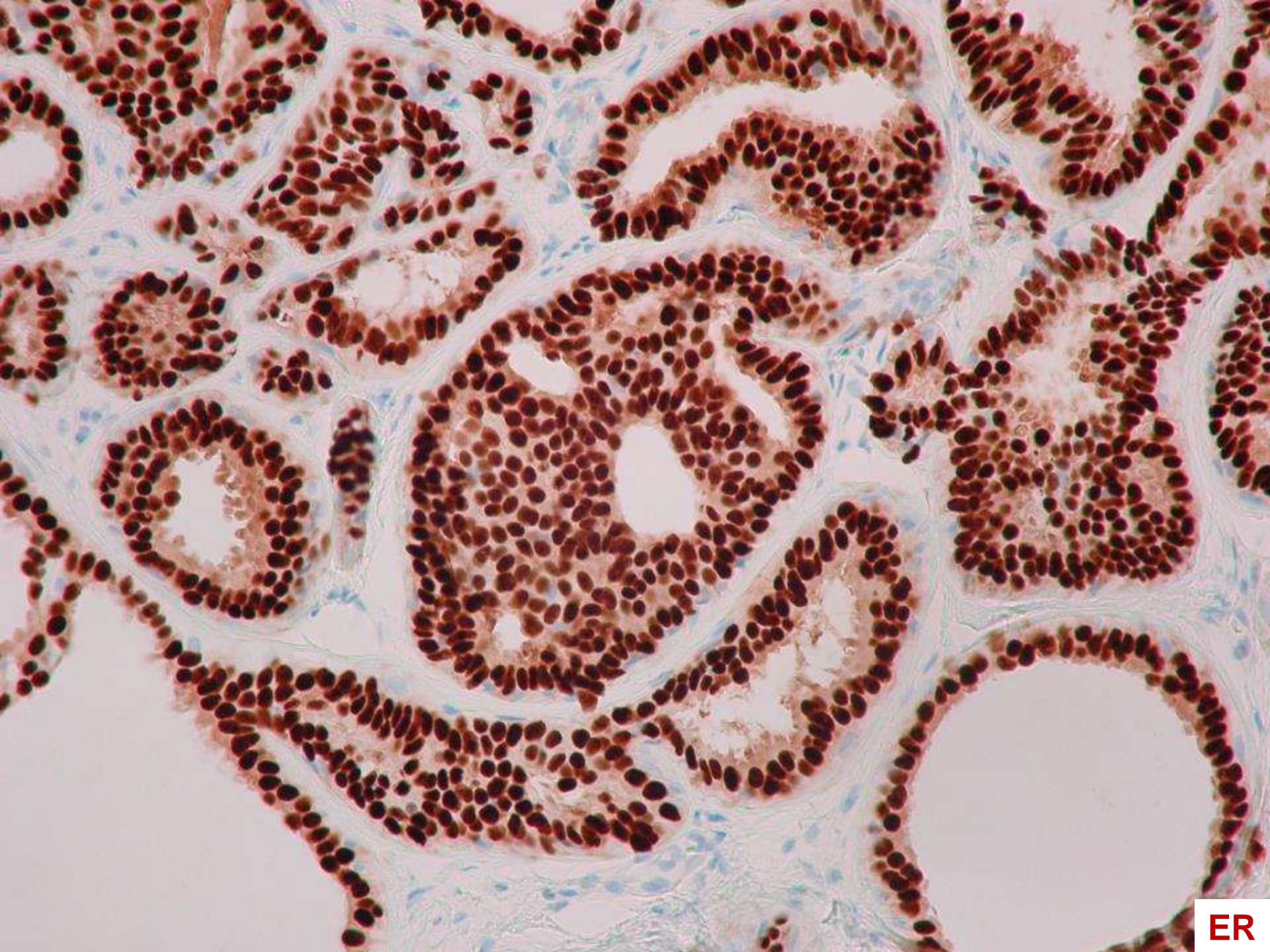
DCIS





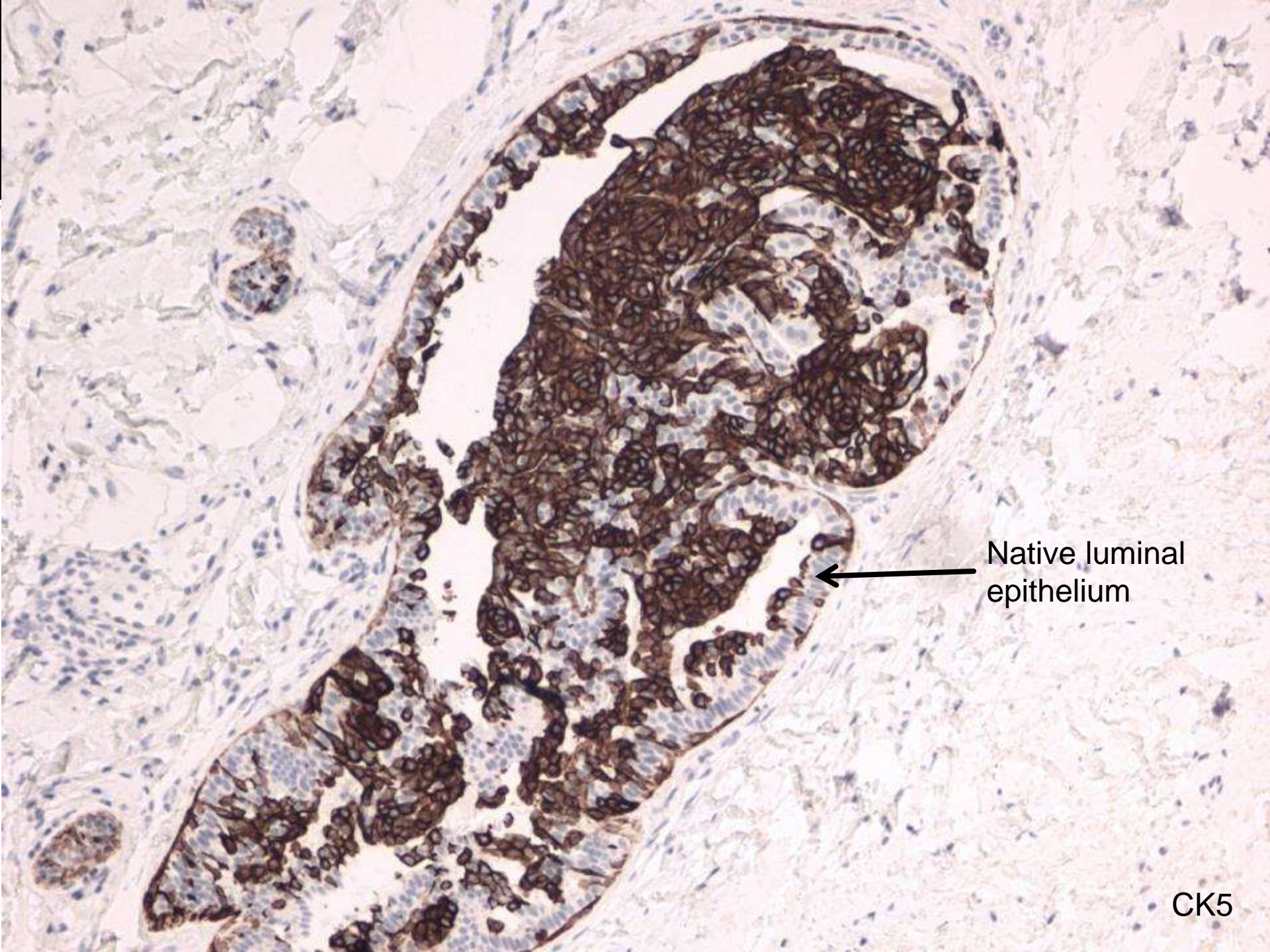






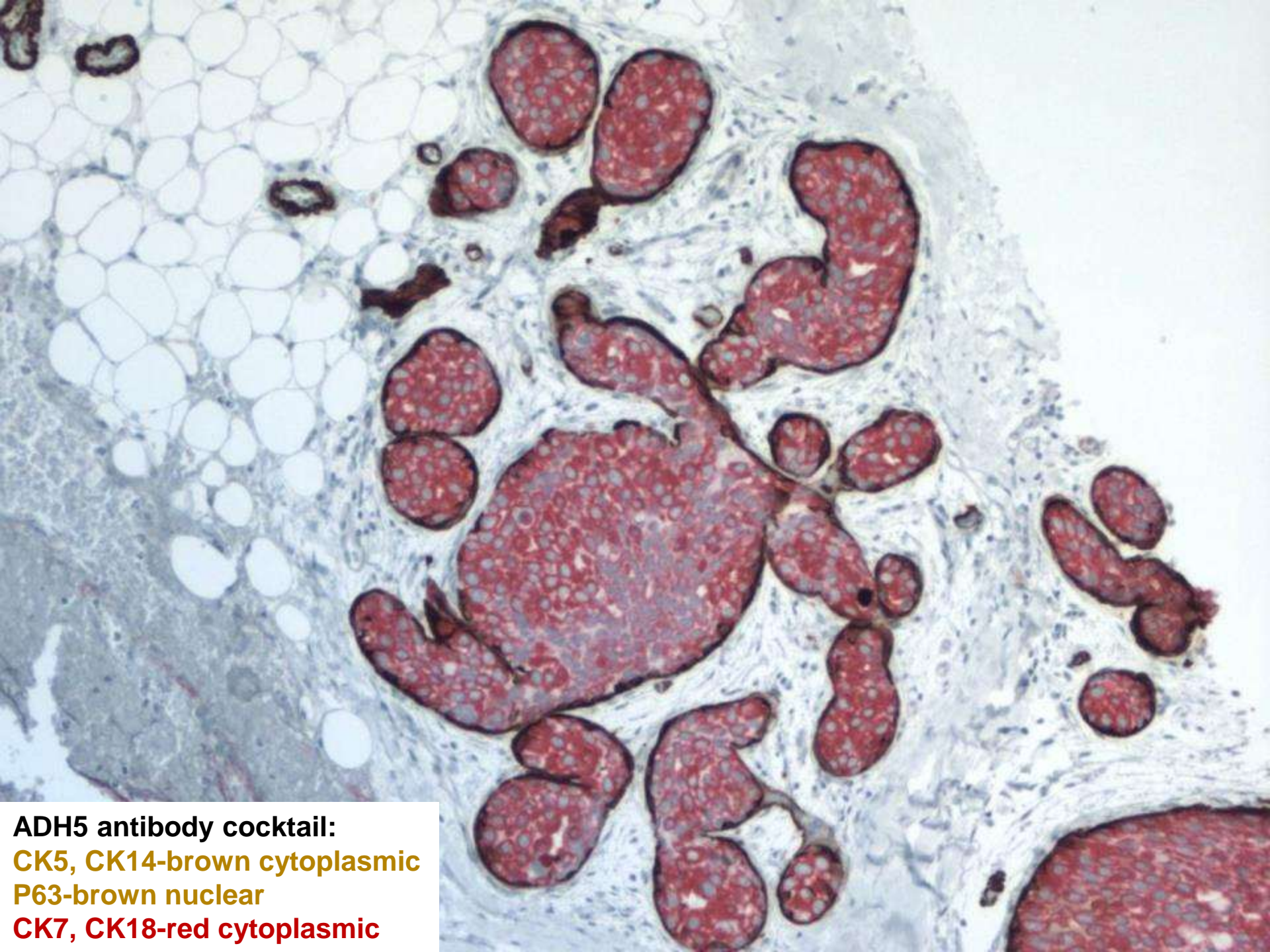Diagnosis of ADH-use of CK5 and ER

- Use the stains as adjuncts
- Focus on pattern and extent of reactivity
 - ADH: CK5 negative, ER + (diffuse strong)
 - UDH: CK5 positive, ER negative or low/patchy
- Pitfalls
 - Apocrine cells show variable reactivity for CK5 and are ER negative
 - Non-atypical columnar cell changes are ER+
 - “Basal-like” DCIS is CK5+
 - Native luminal epithelium is CK5 negative
- Limitation
 - Cannot distinguish between ADH and low grade DCIS

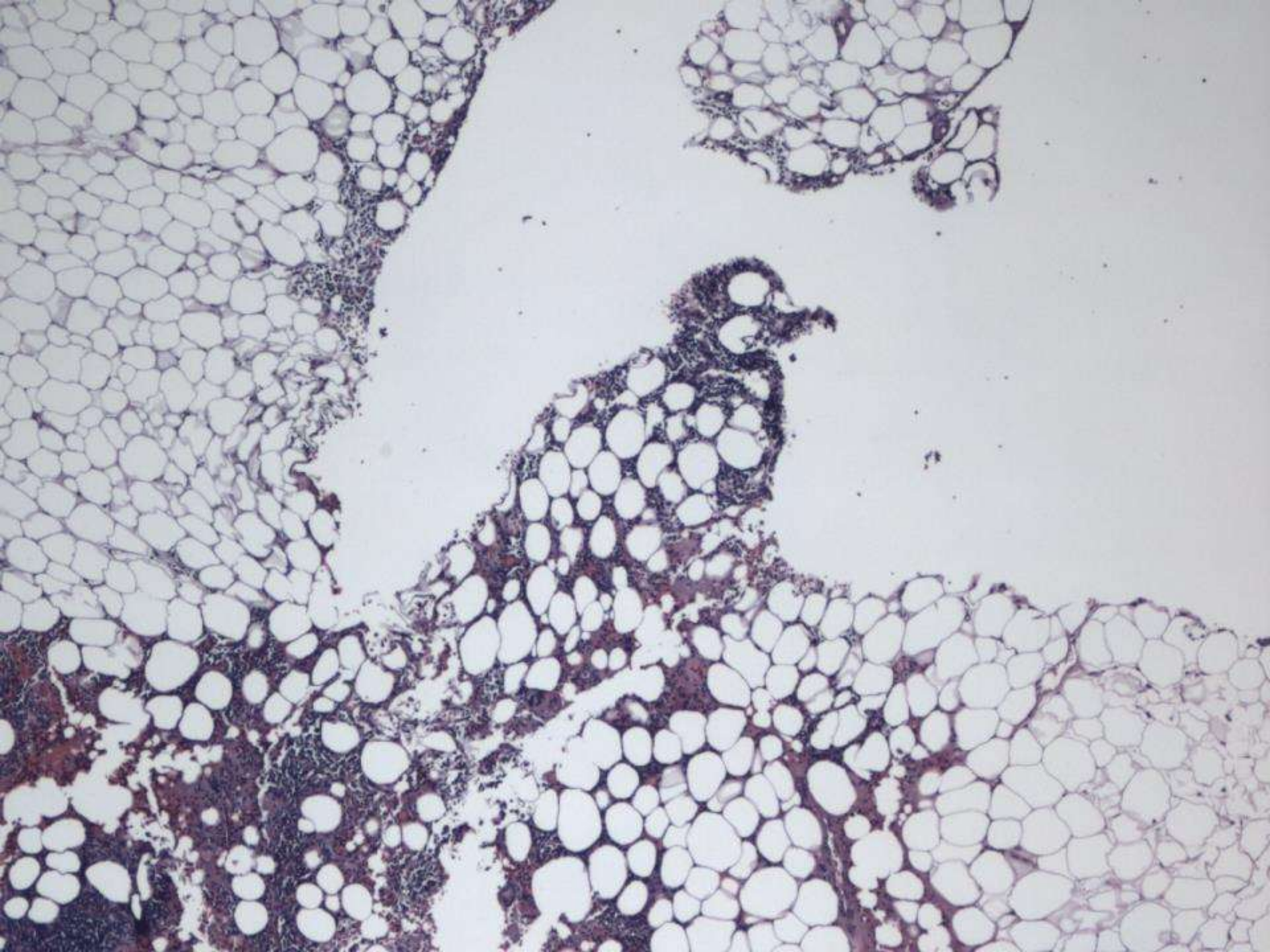


Native luminal
epithelium

CK5



ADH5 antibody cocktail:
CK5, CK14-brown cytoplasmic
P63-brown nuclear
CK7, CK18-red cytoplasmic



Papillary Lesions

- Ranges from benign papilloma to invasive carcinoma

- Intraductal papilloma
- Papilloma with ADH
- Papilloma with DCIS
- Papillary DCIS

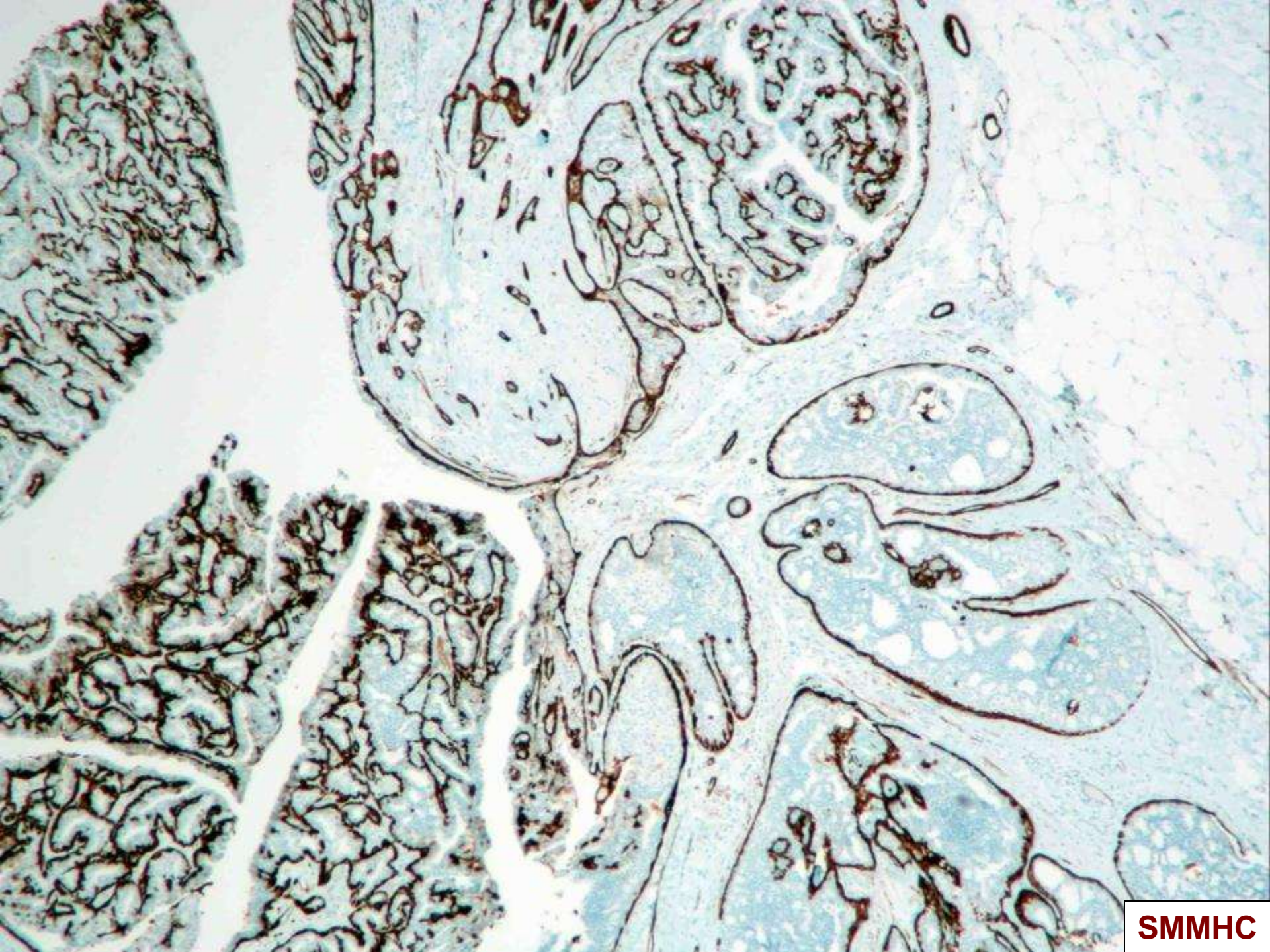
Clear

-
- Encapsulated (intracystic/encysted) papillary carcinoma
 - Solid papillary carcinoma

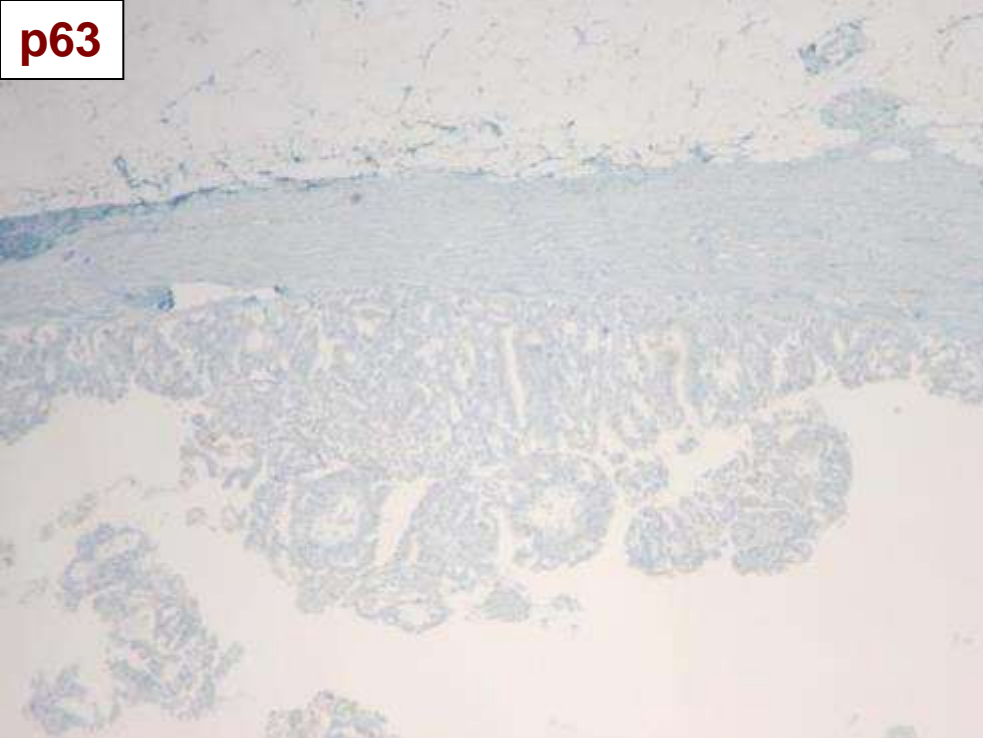
Confusing

-
- Invasive papillary carcinoma

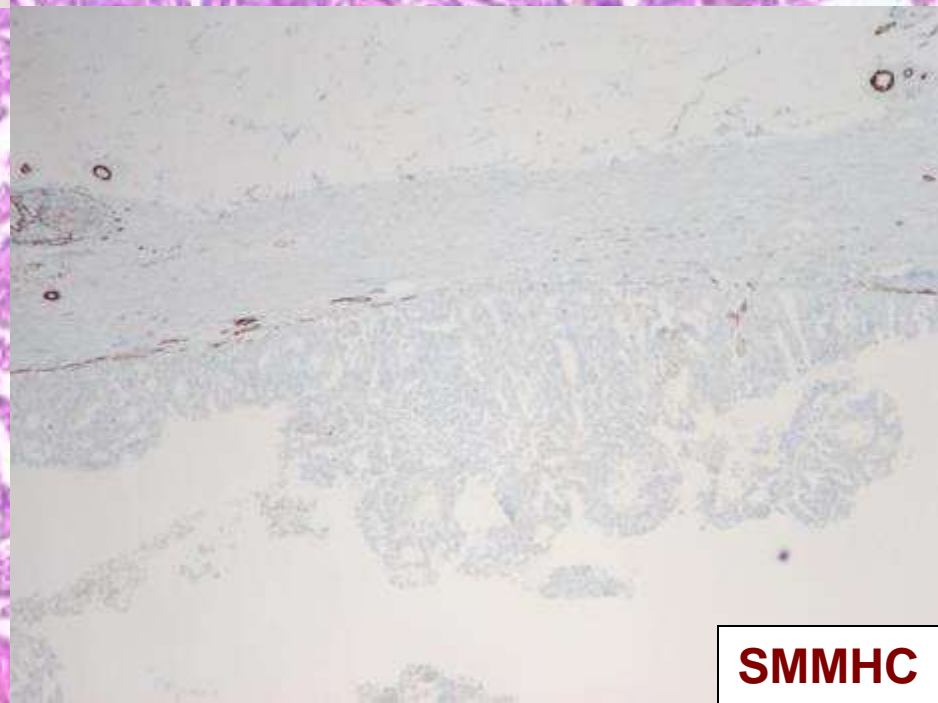
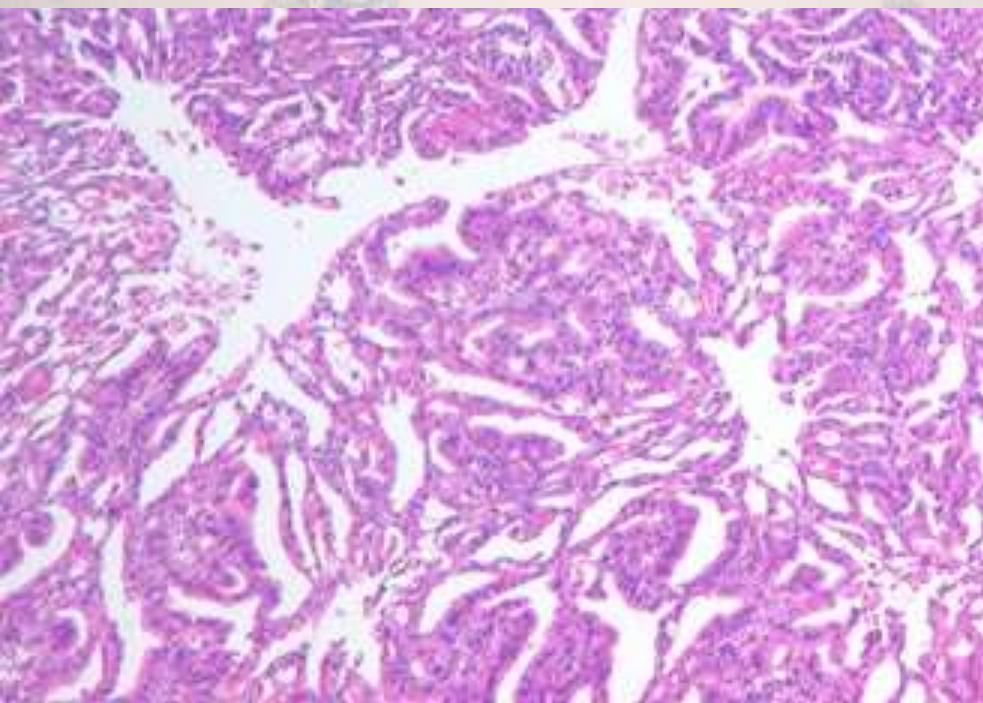
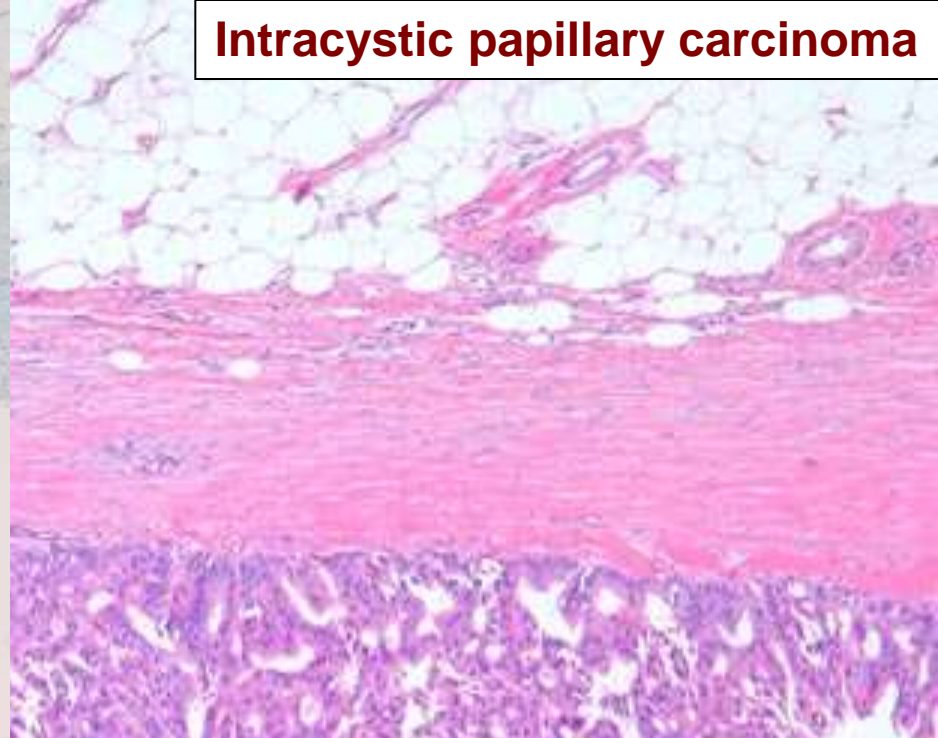
Clear



p63



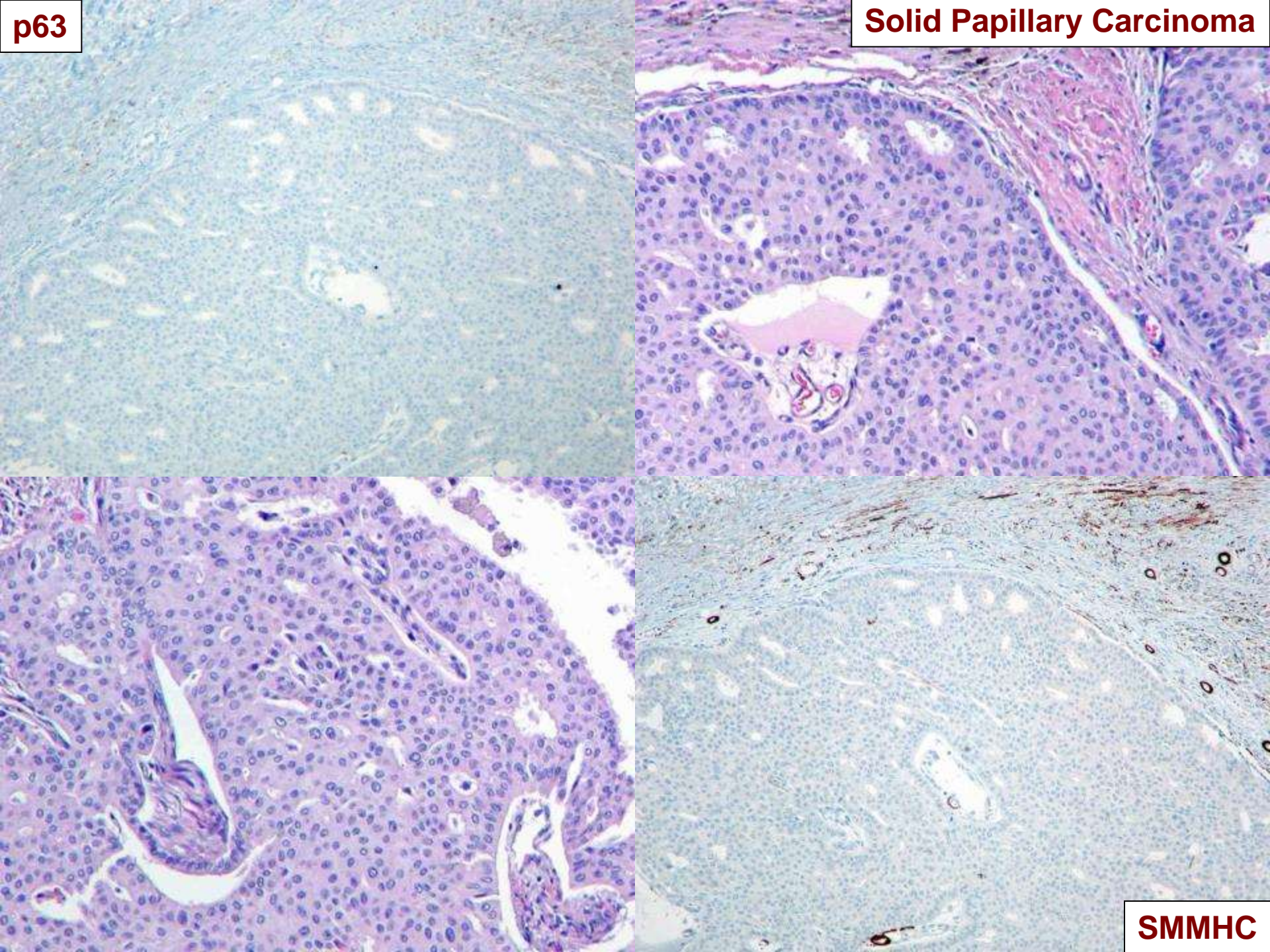
Intracystic papillary carcinoma



SMMHC

p63

Solid Papillary Carcinoma

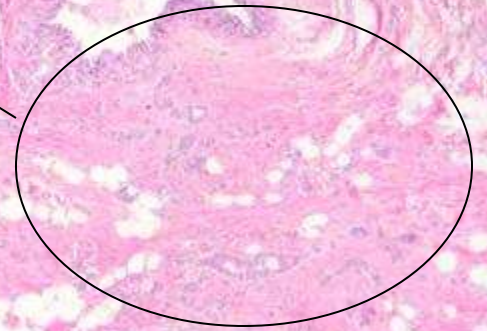
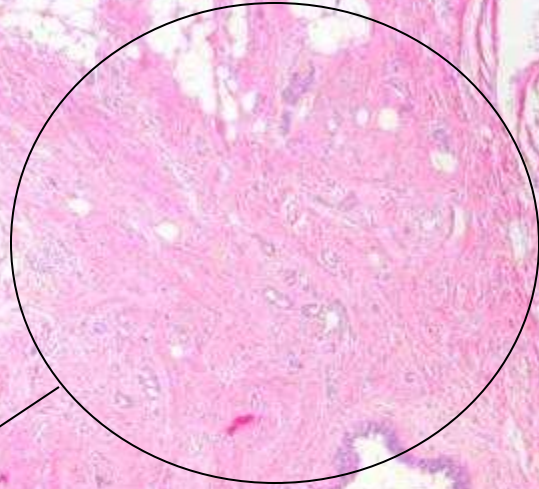
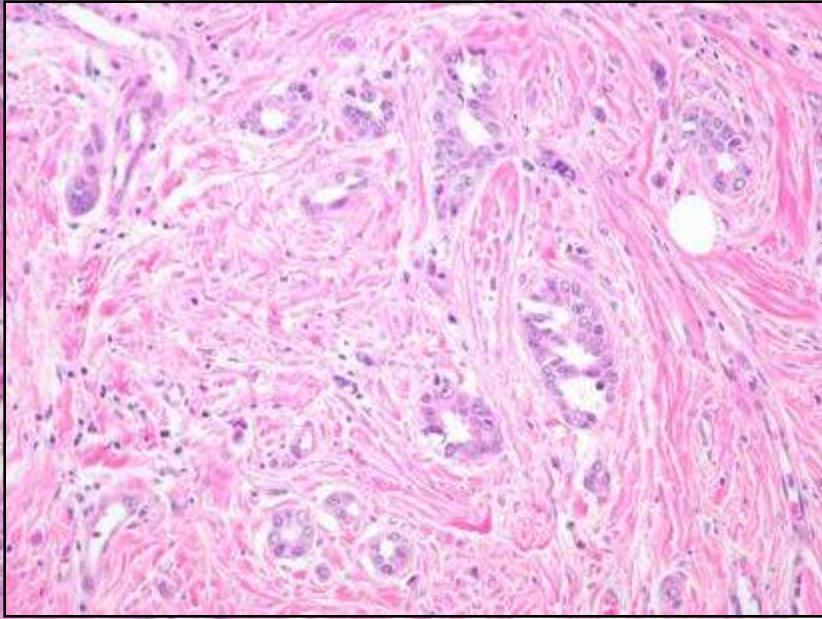
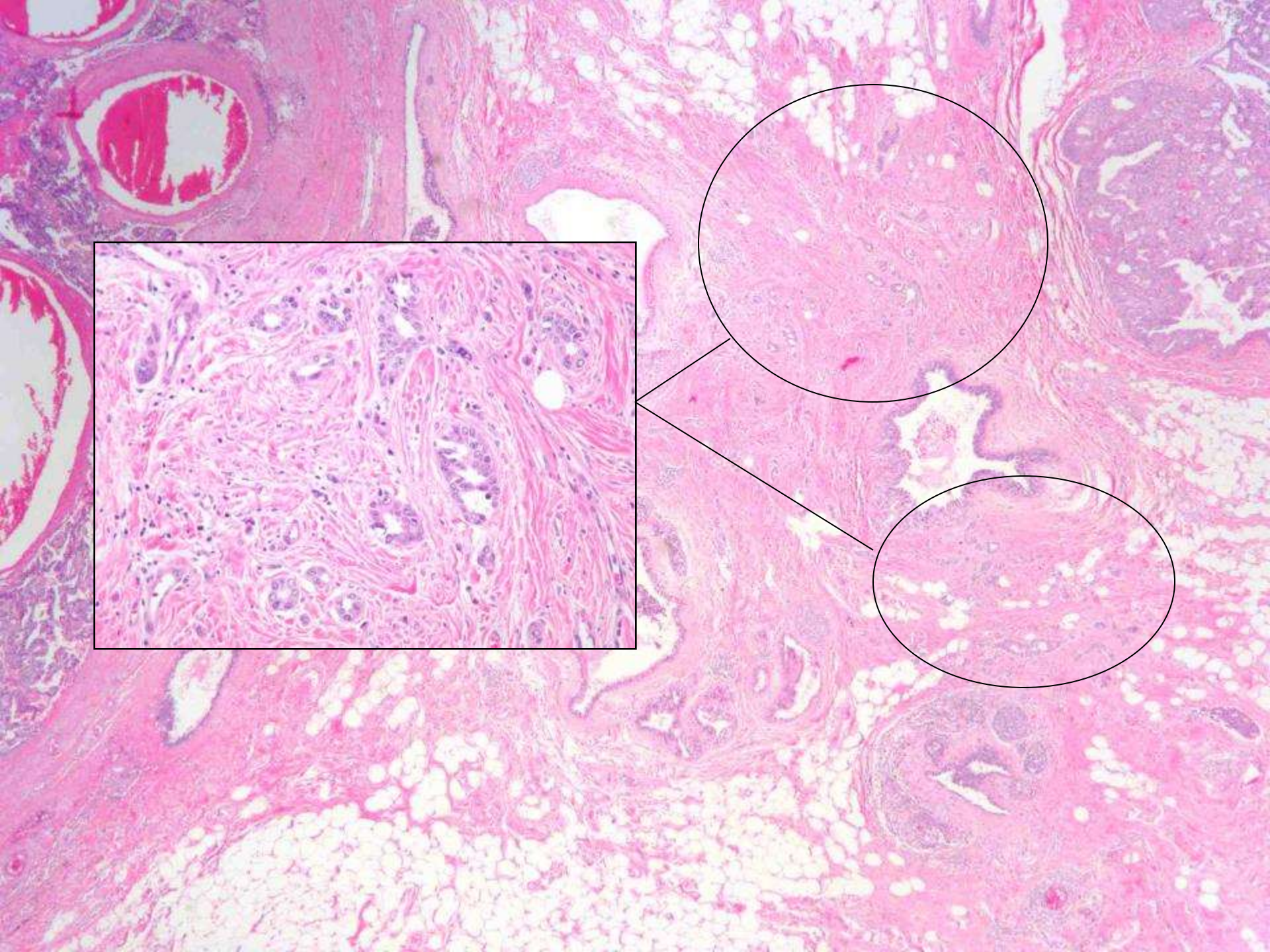


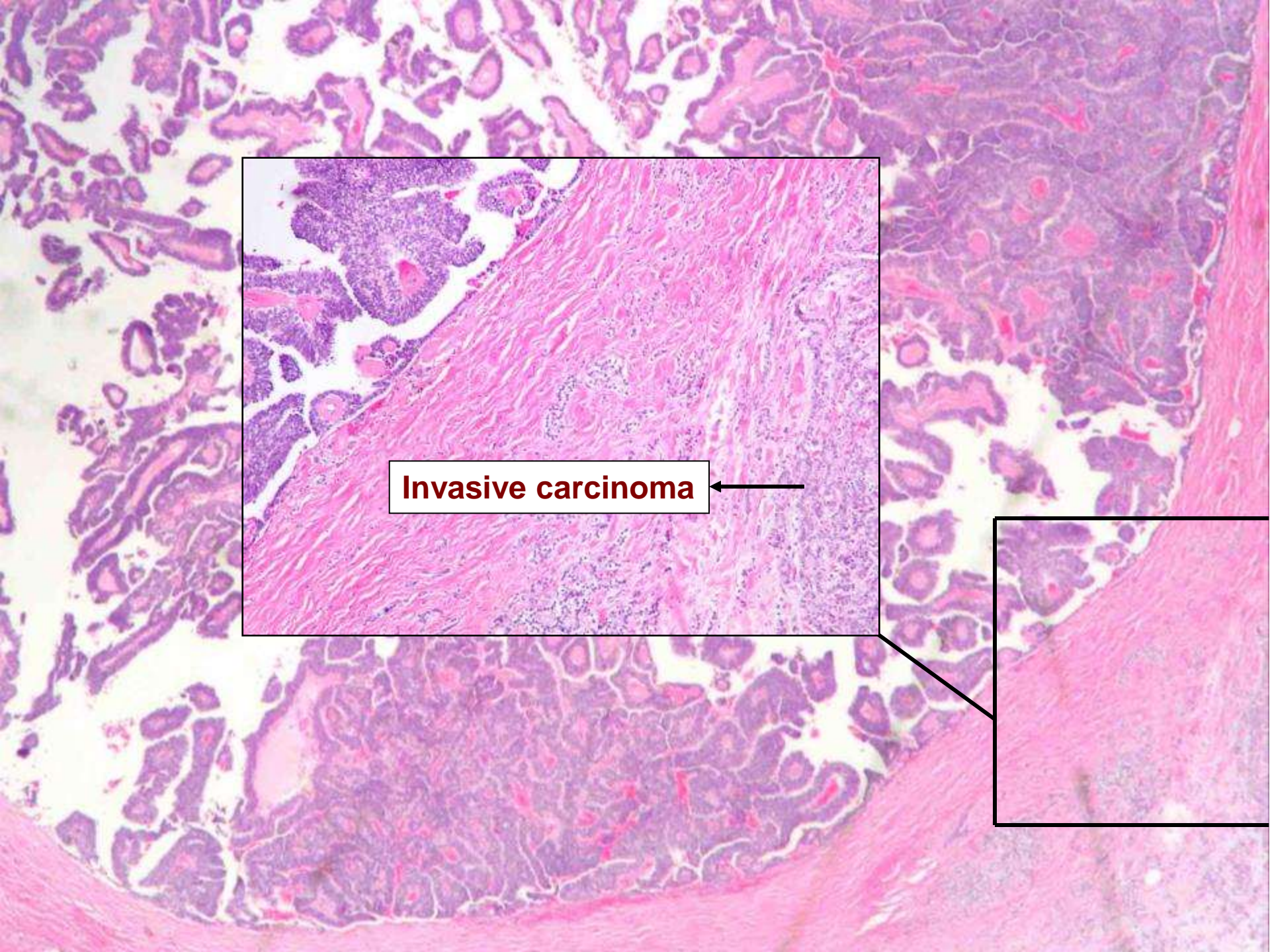
SMMHC

Papillary Lesions

	Myoepithelial cells	Clinical Behavior
Papilloma	Present within and around ducts	Benign, slight increase in lifetime risk
Papilloma with ADH/DCIS or papillary DCIS	Reduced/absent within, present around ducts	Risk for invasive malignancy
Encapsulated papillary carcinoma	Absent within, absent/focal around	Mostly similar to DCIS, unless frankly invasive
Solid papillary carcinoma	Absent within, absent/focal around	Mostly similar to DCIS, unless frankly invasive

Original Studies: Hill et al. Am J Clin Pathol. 2005;123:36-44; Collins et al. Am J Surg Pathol. 2006;30:1002-1007
 Reviews: Collins LC et al. Histopathology 2008;52:20-29; Mulligan AM et al. Adv Anat Pathol. 2007;14:108-119





Invasive carcinoma

EPC/SPC-Clinical Issues

- Conceptually somewhere in the spectrum between DCIS and invasive cancer
- Low risk of local recurrence*
- Very low risk of distant recurrence*
- Clinical management issues
 - Should be staged as pTis
 - HER2 should not be performed
 - Should not be sent out for multi-gene tests for invasive cancer

*Rakha EA et al. Am J Surg Pathol. 2011;35:1093-1103. PMID: 21753694

EPC/SPC-Clinical Issues

- Prior to their recognition, EPC/SPC have been diagnosed mostly as DCIS and in some cases as invasive and treated as such
 - Radiation therapy as indicated for DCIS if patient only had lumpectomy
 - Endocrine therapy for risk reduction if any breast tissue remaining
 - No definitive recommendation for endocrine therapy if patient receives bilateral mastectomies

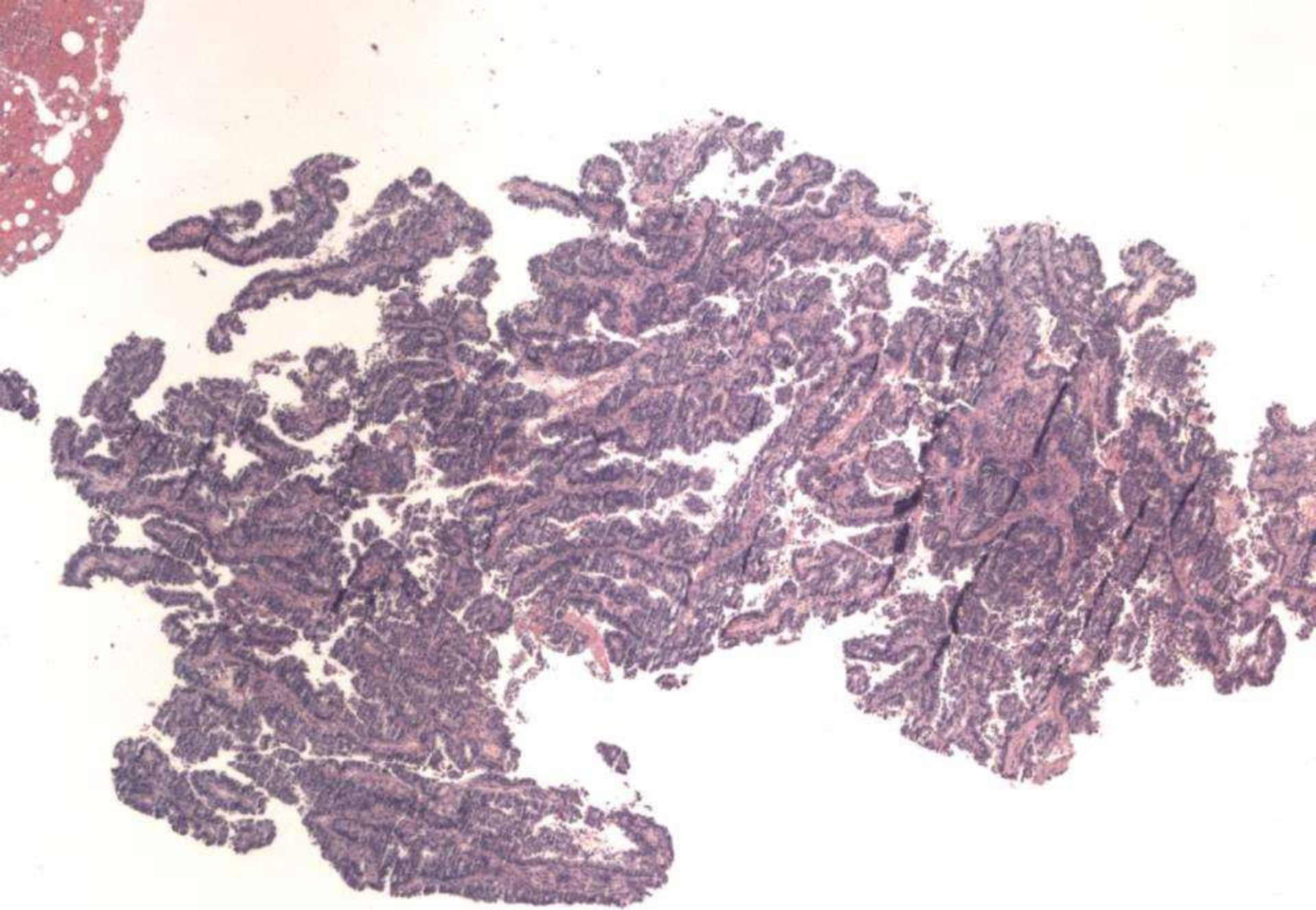
EPC and SPC

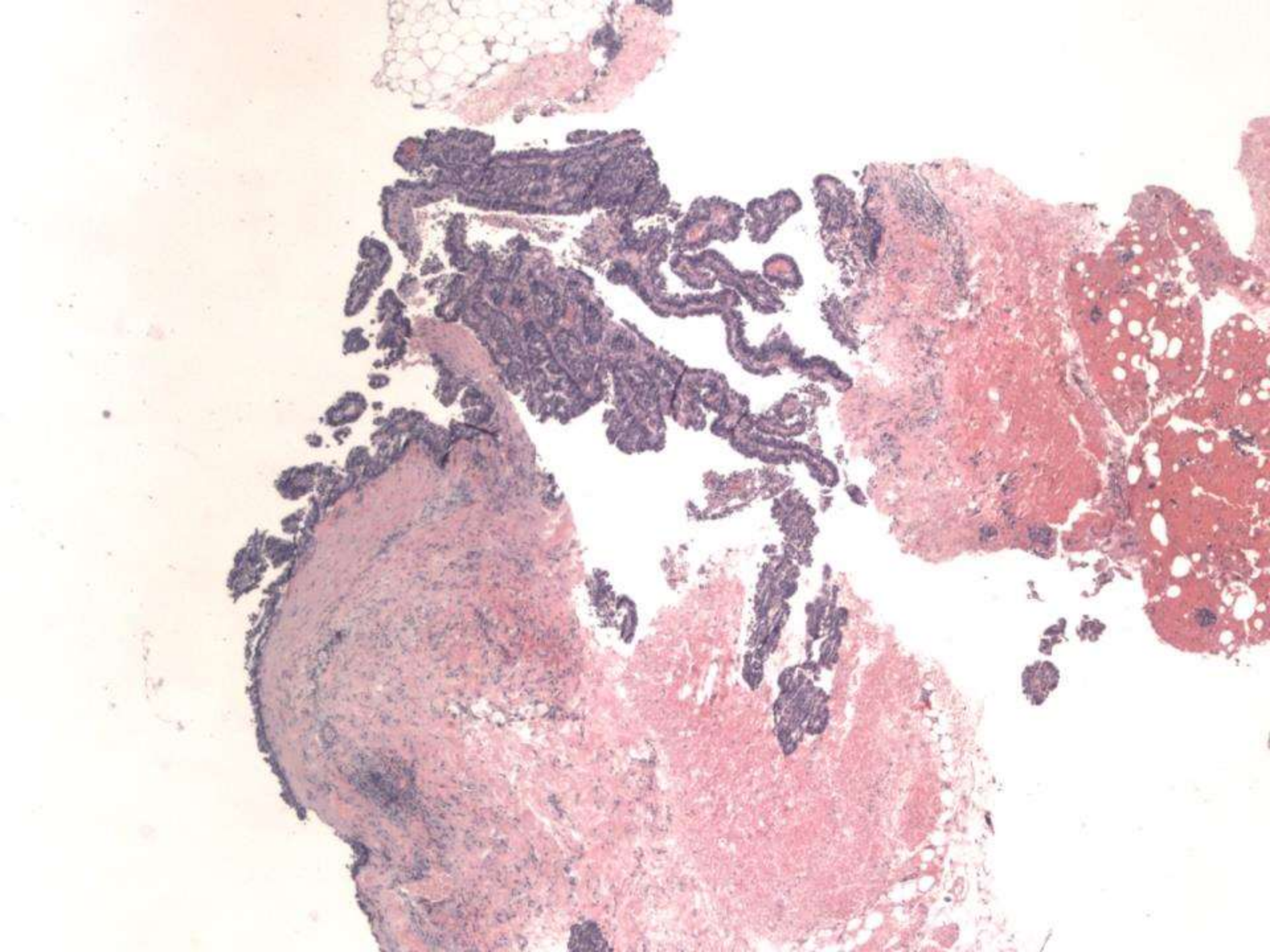
Can one diagnose EPC and SPC in a core biopsy?

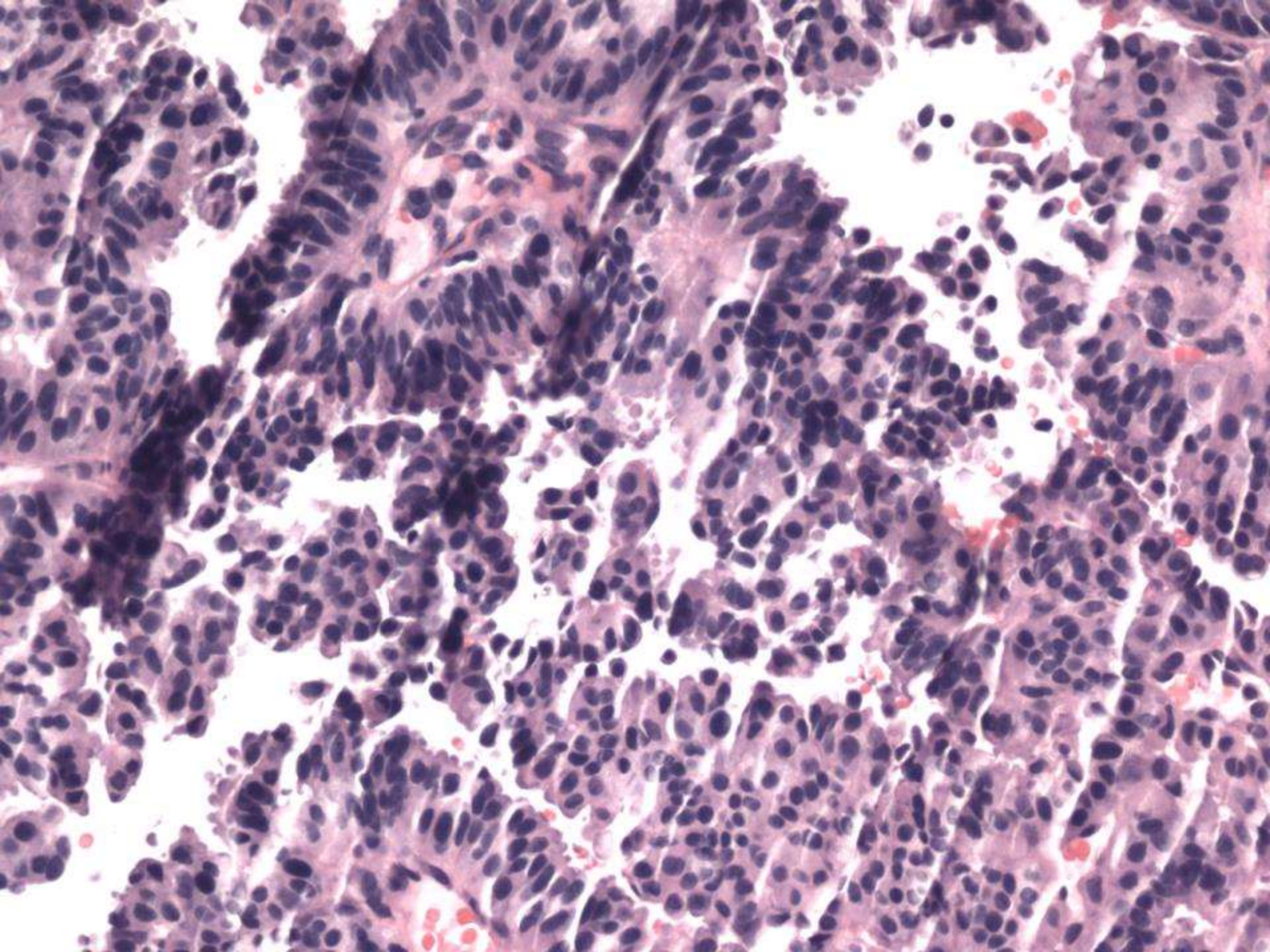
Yes, but with caution!

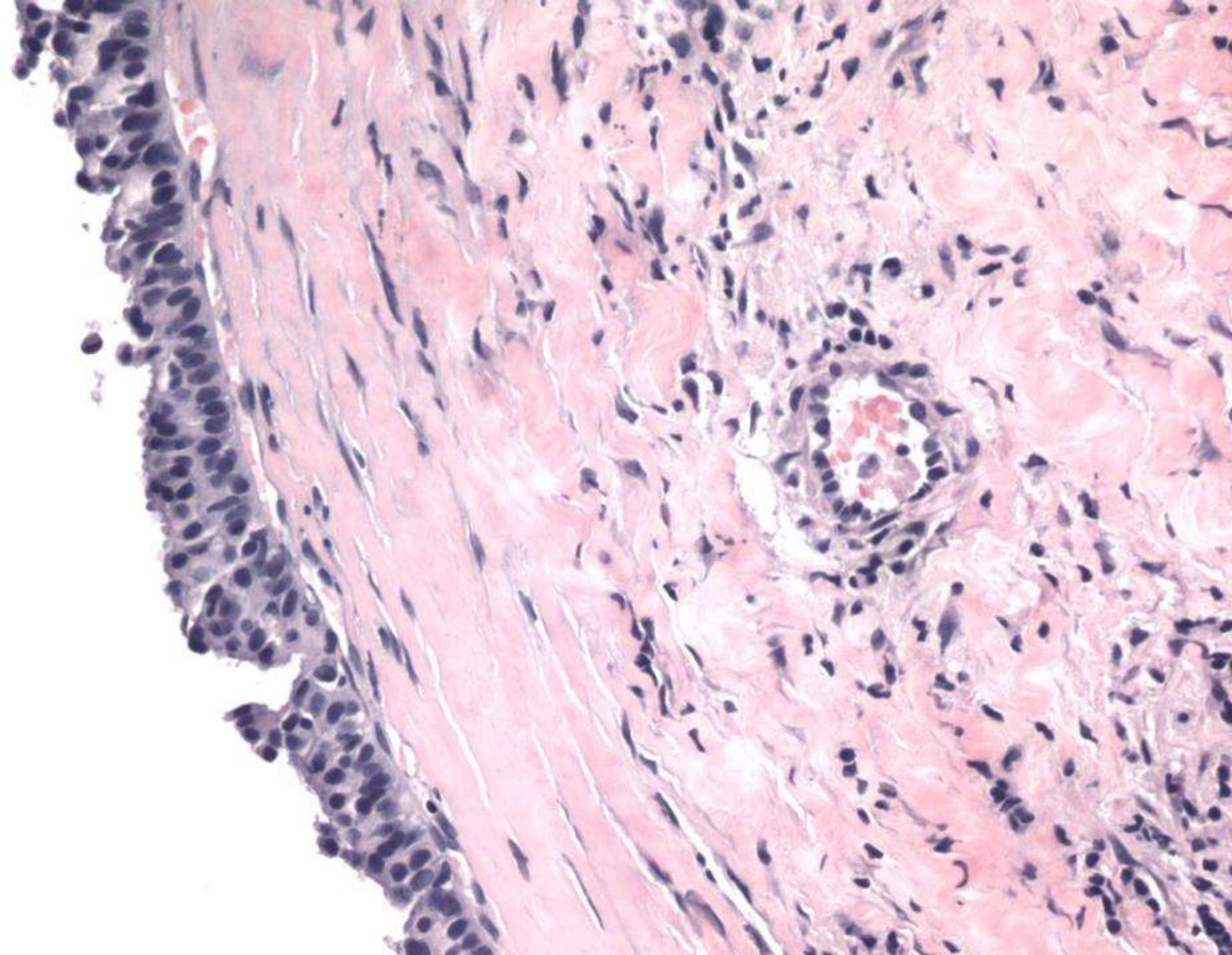
History-Classic EPC Case

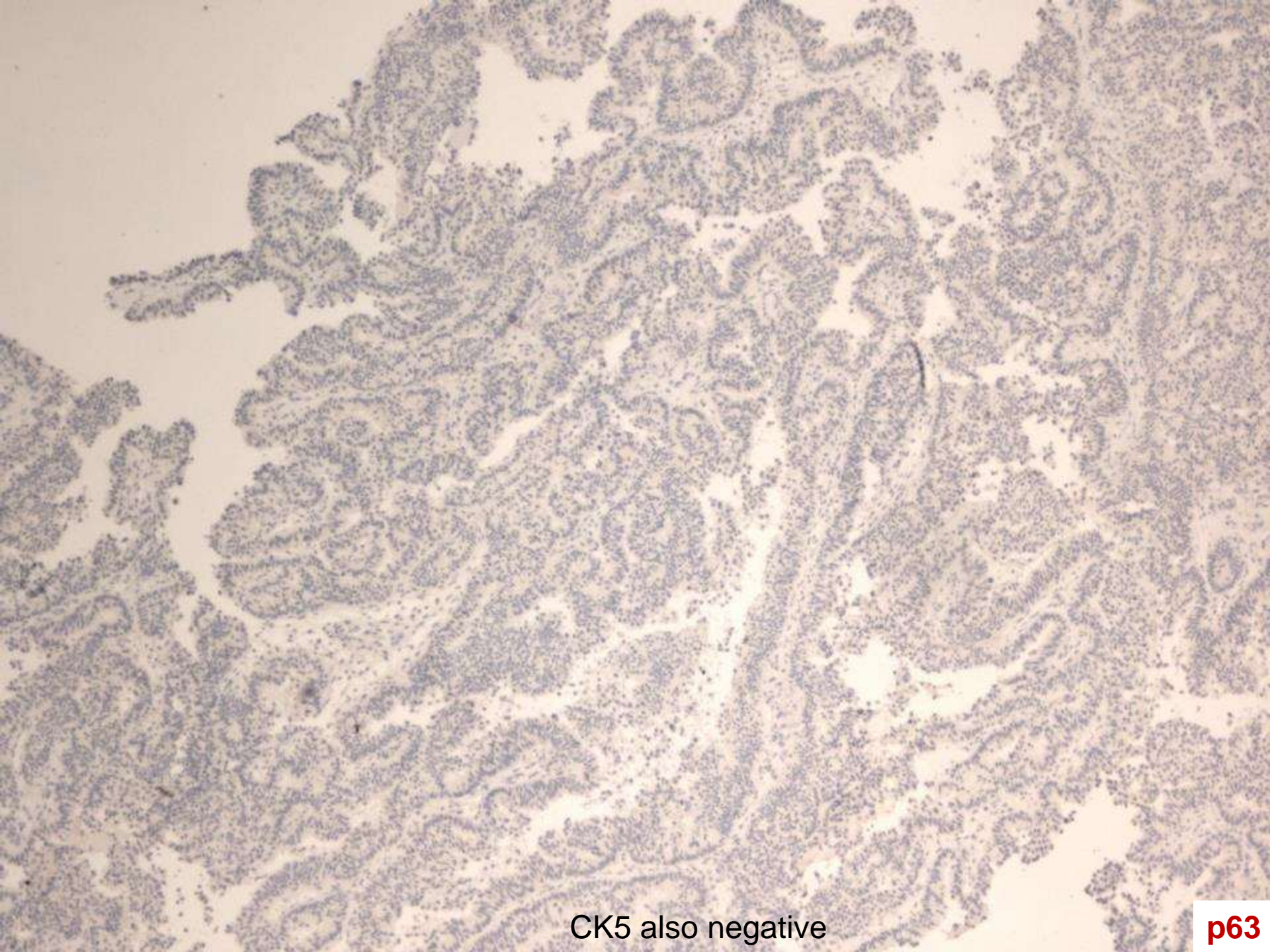
- Female, 63 years
- Right breast mass
 - 3 cm
 - Complex solid and cystic
- Core biopsy performed





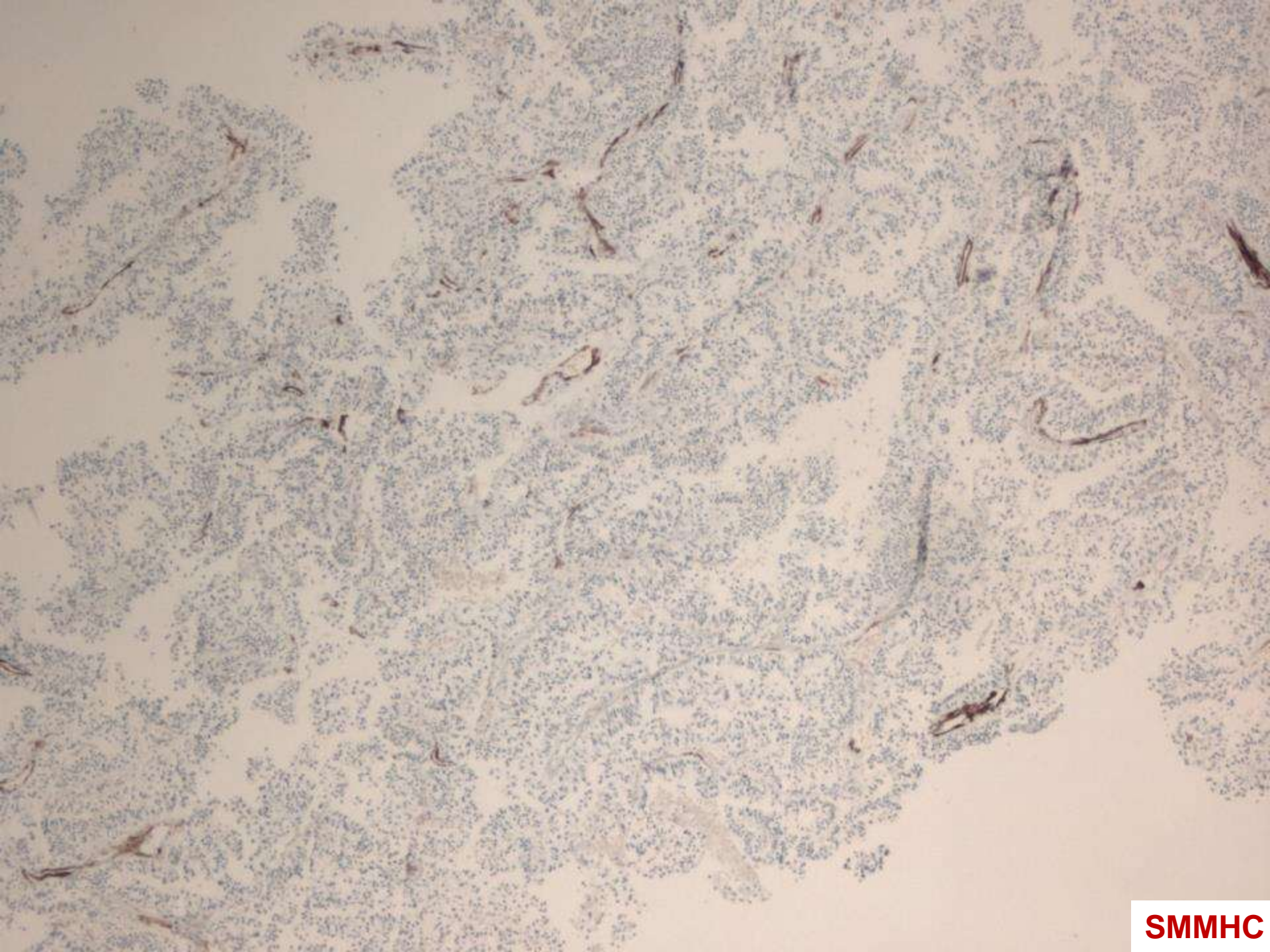


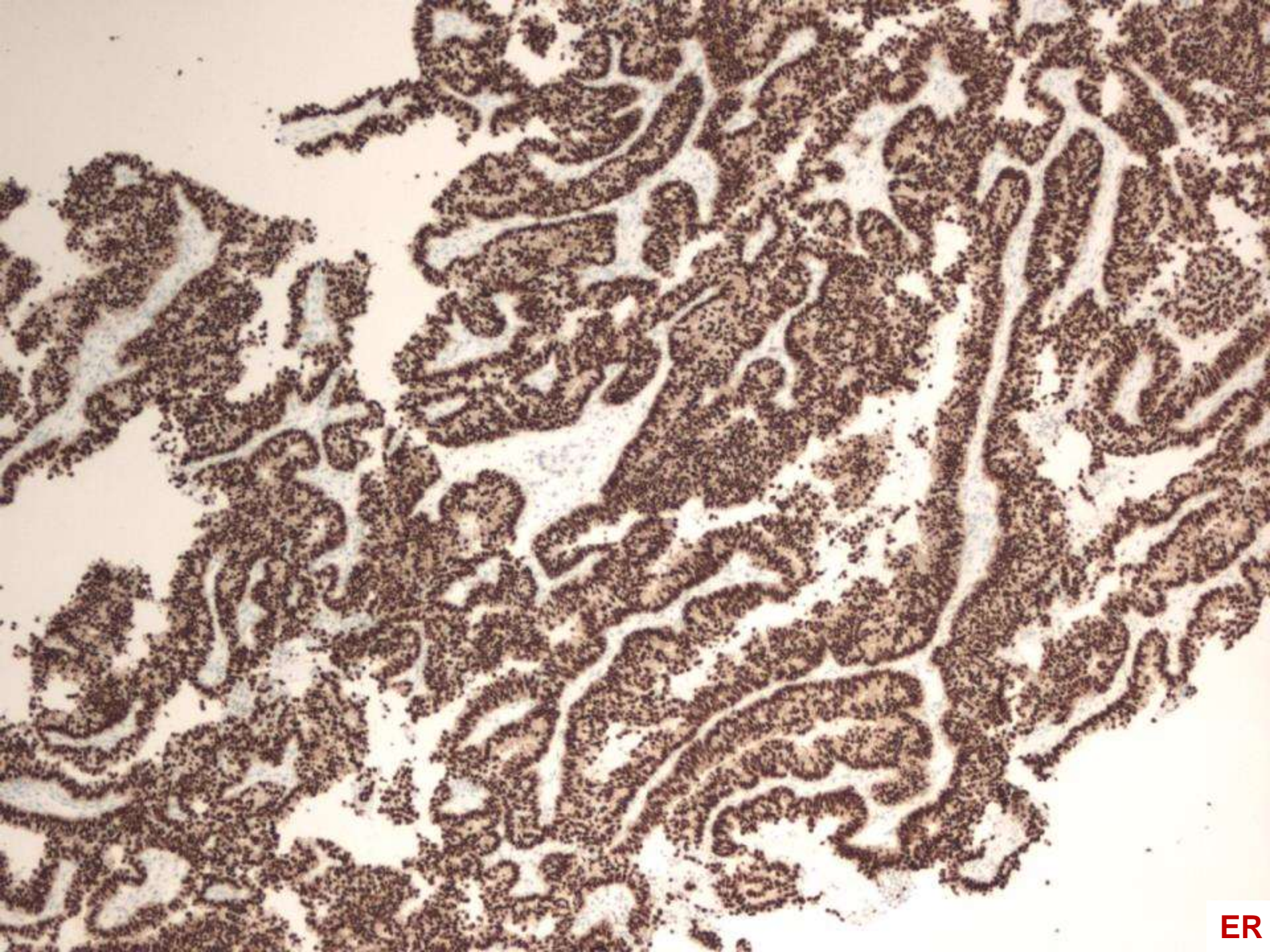


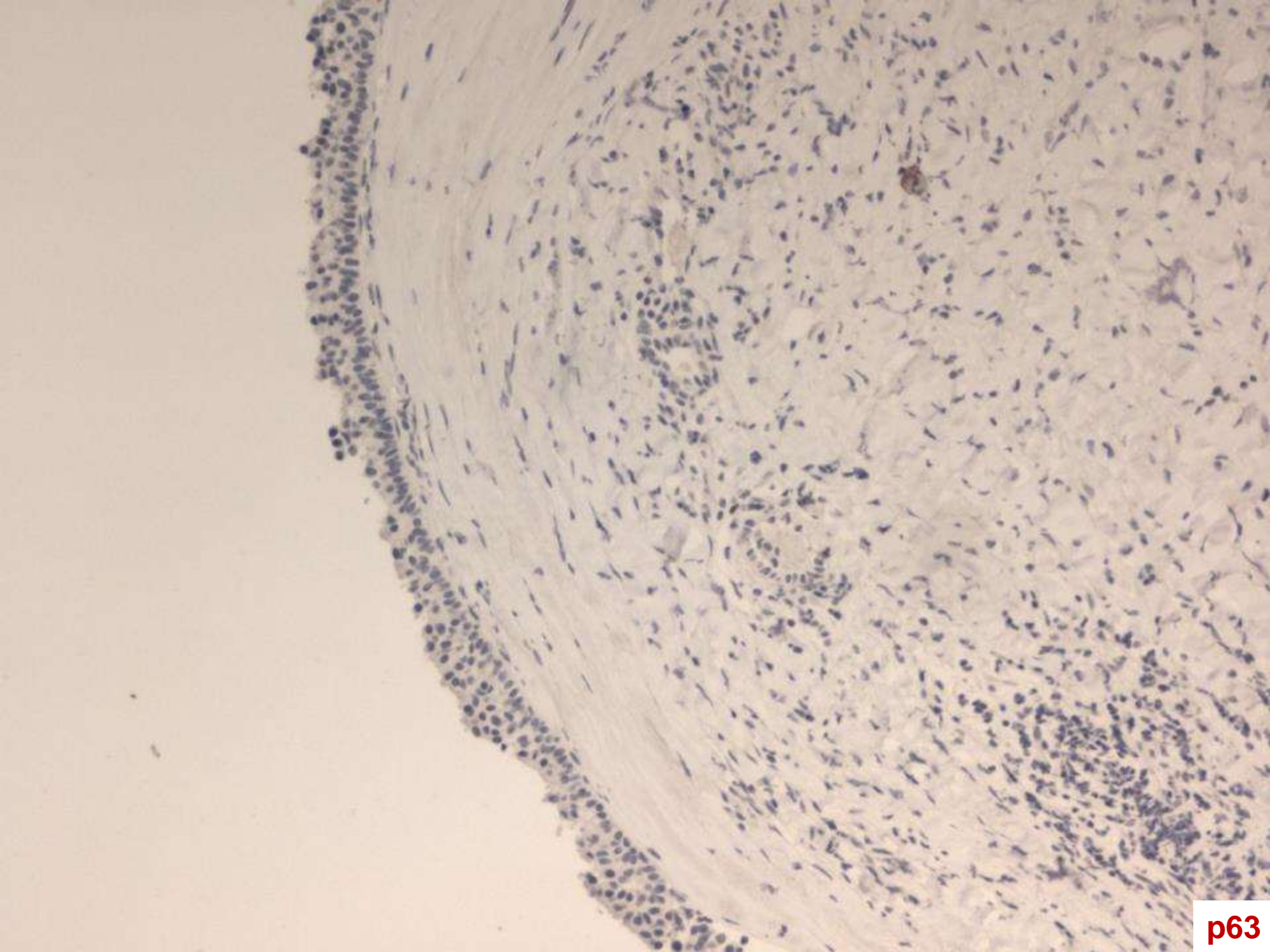


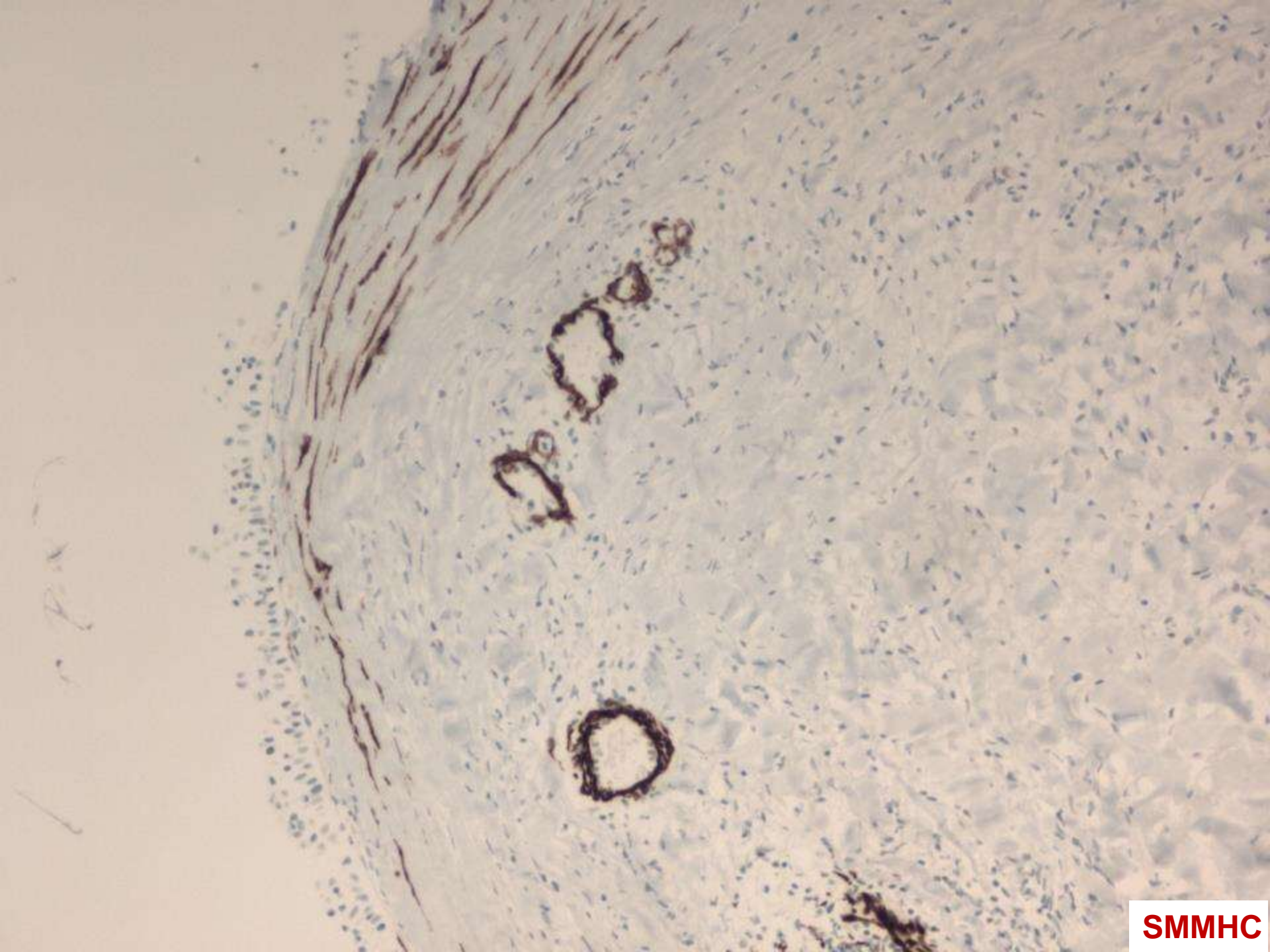
CK5 also negative

p63



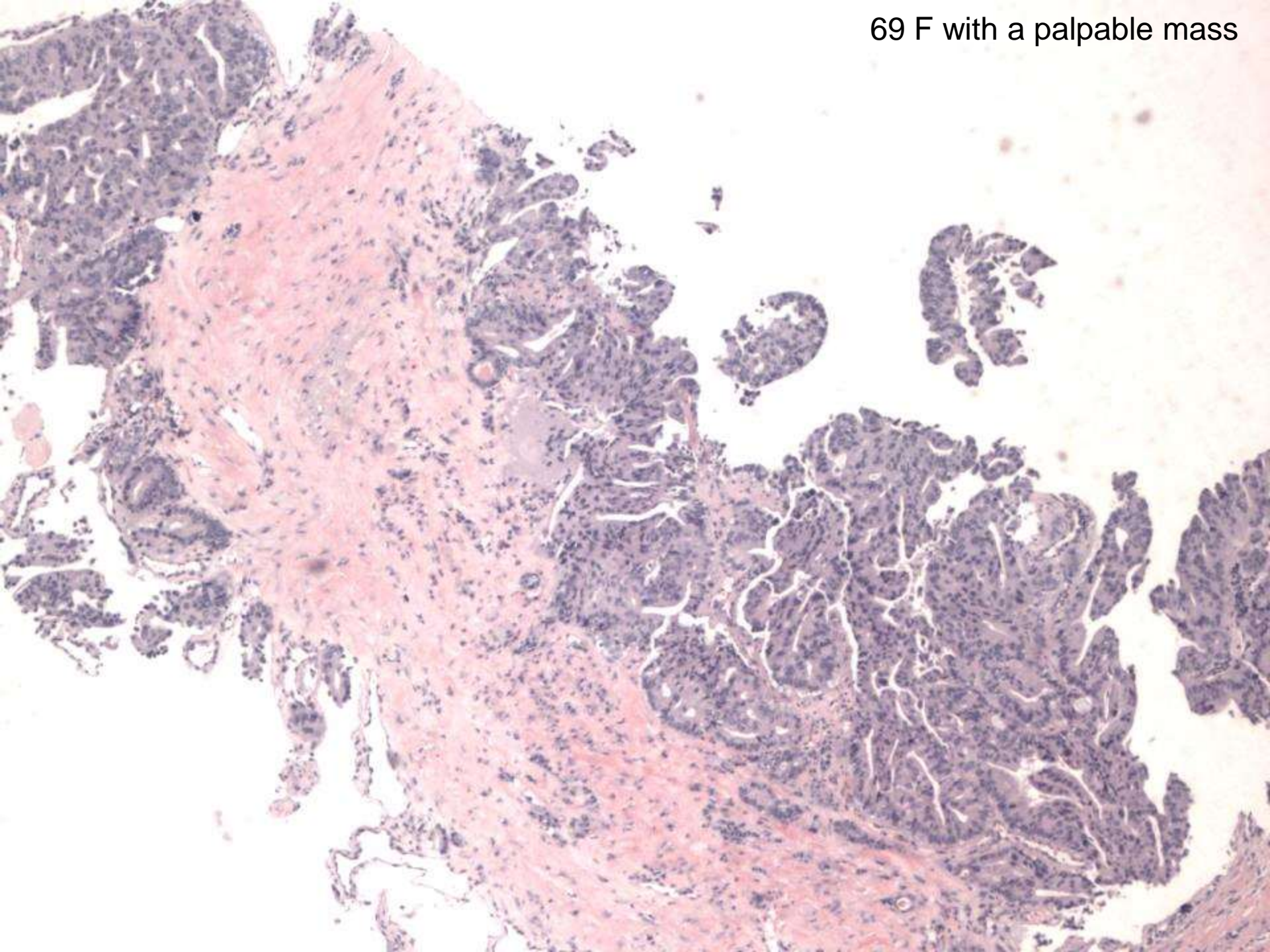


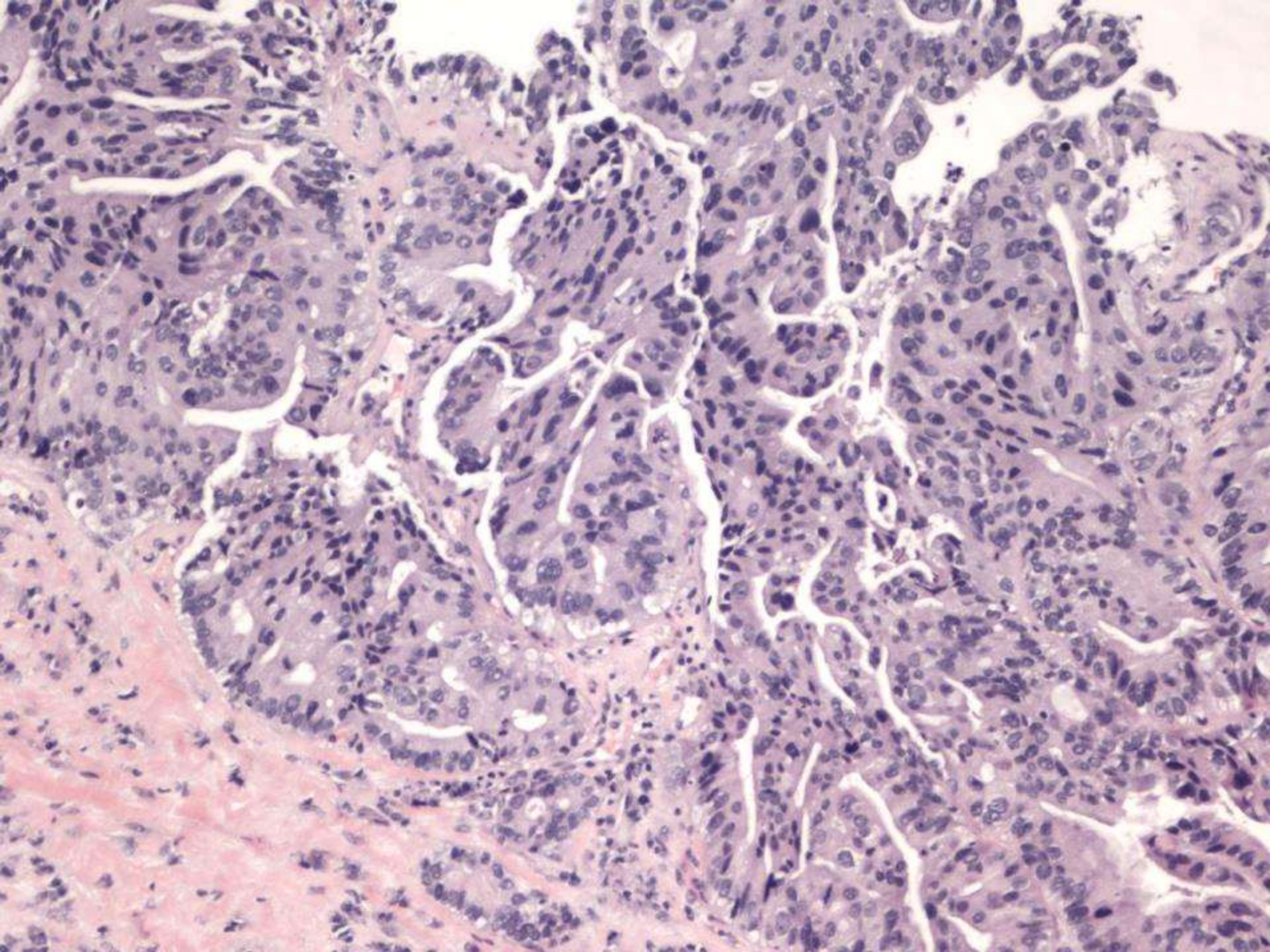


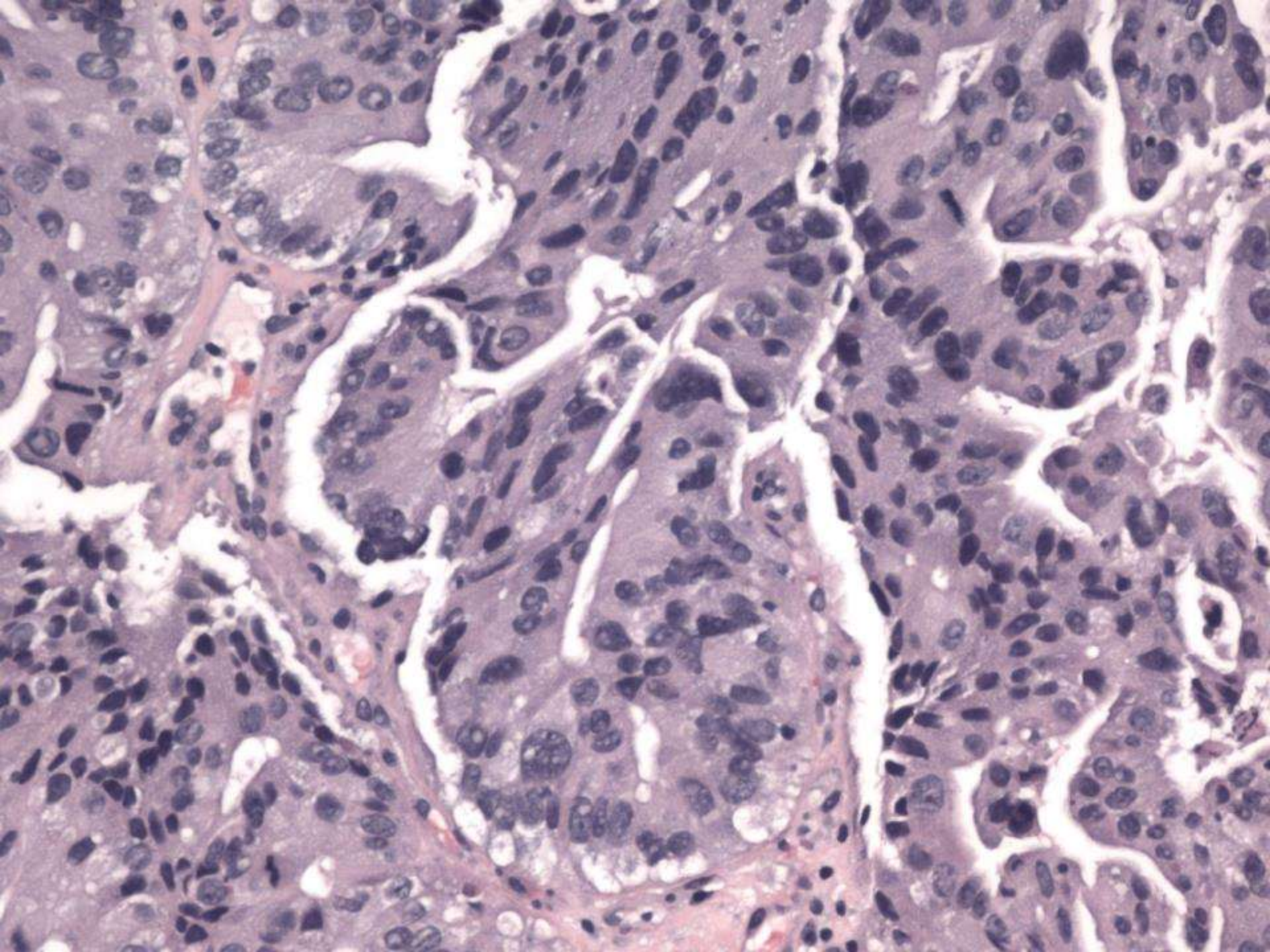


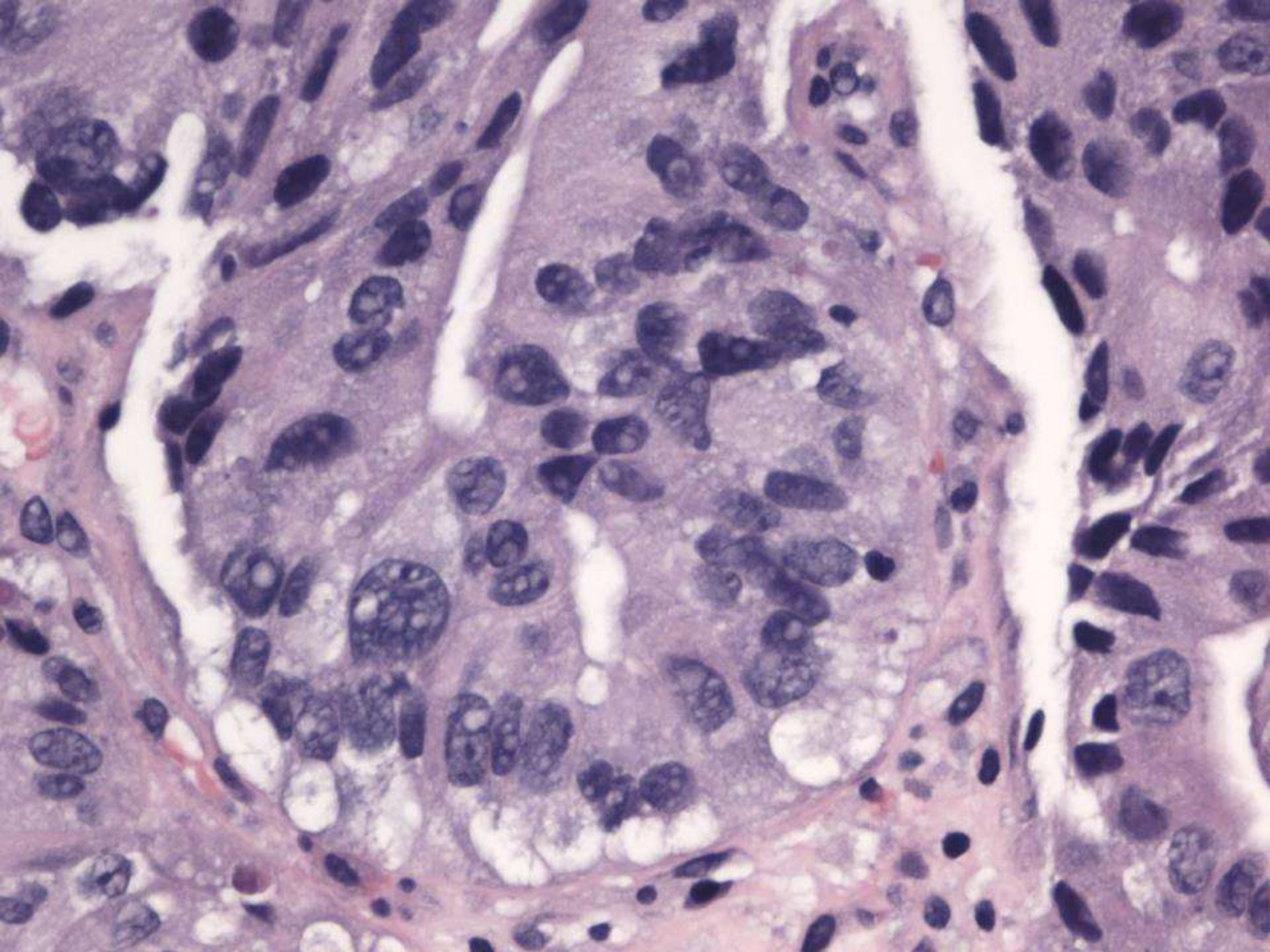
Case that mimics an EPC

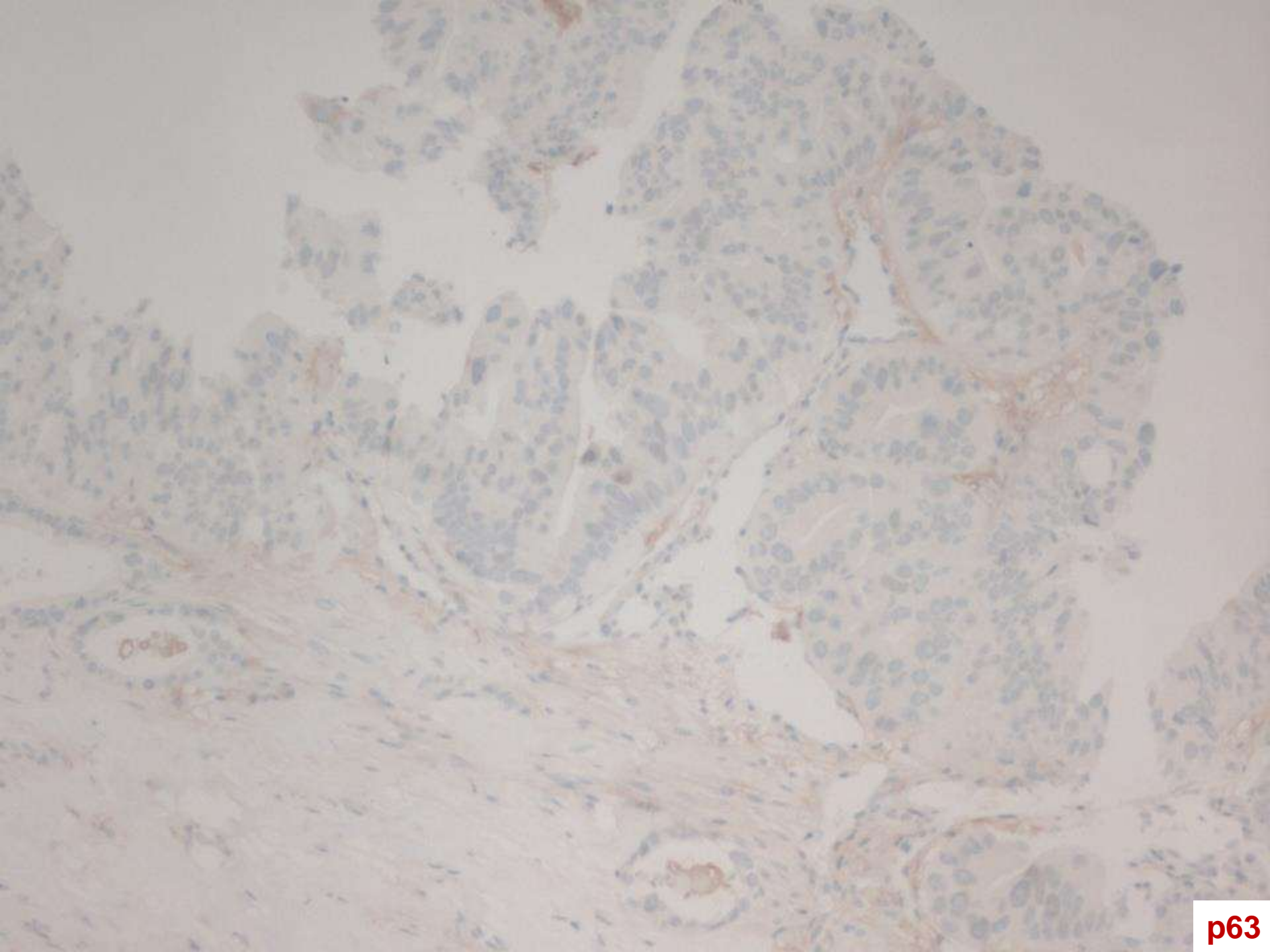
69 F with a palpable mass

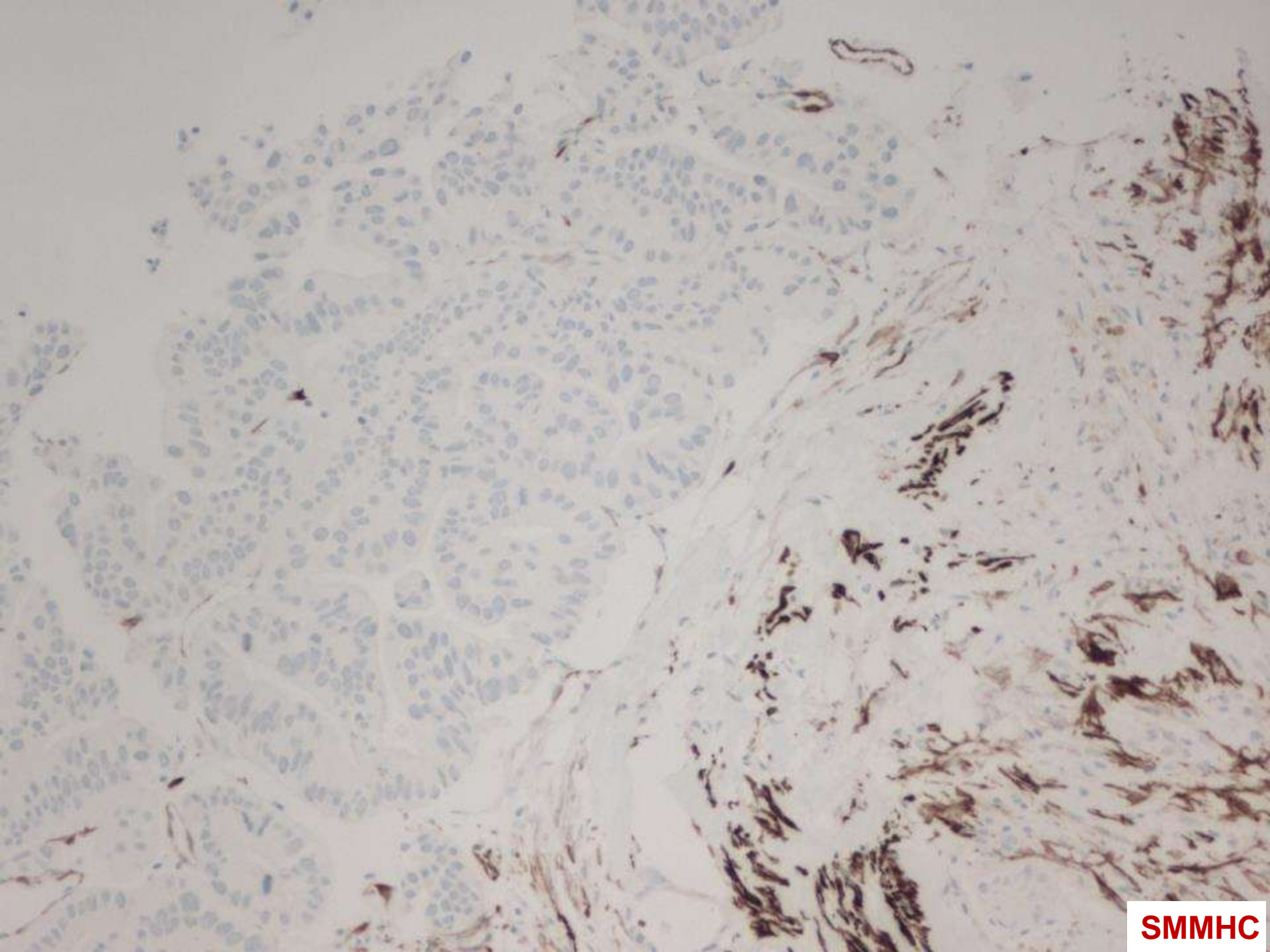


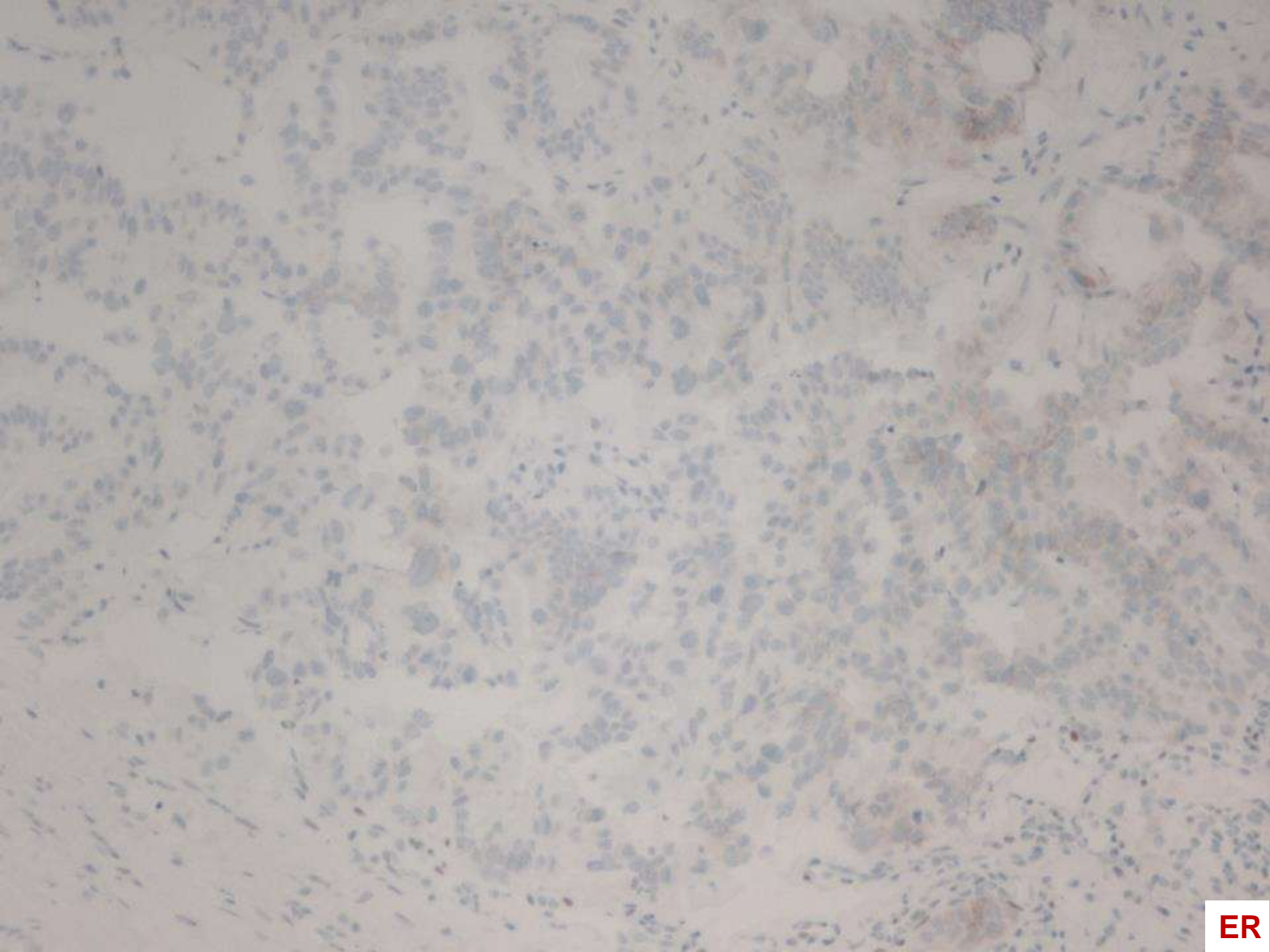


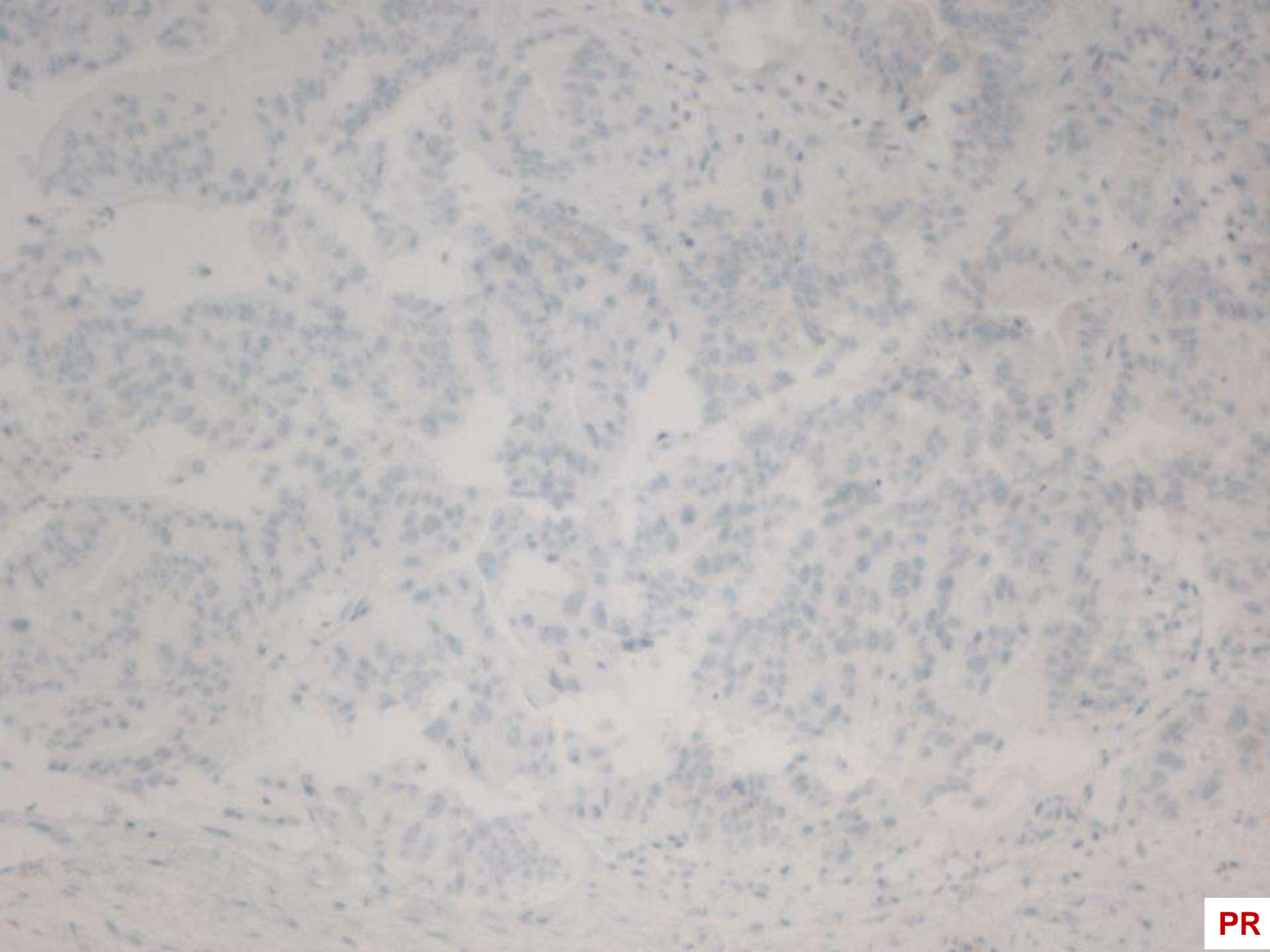

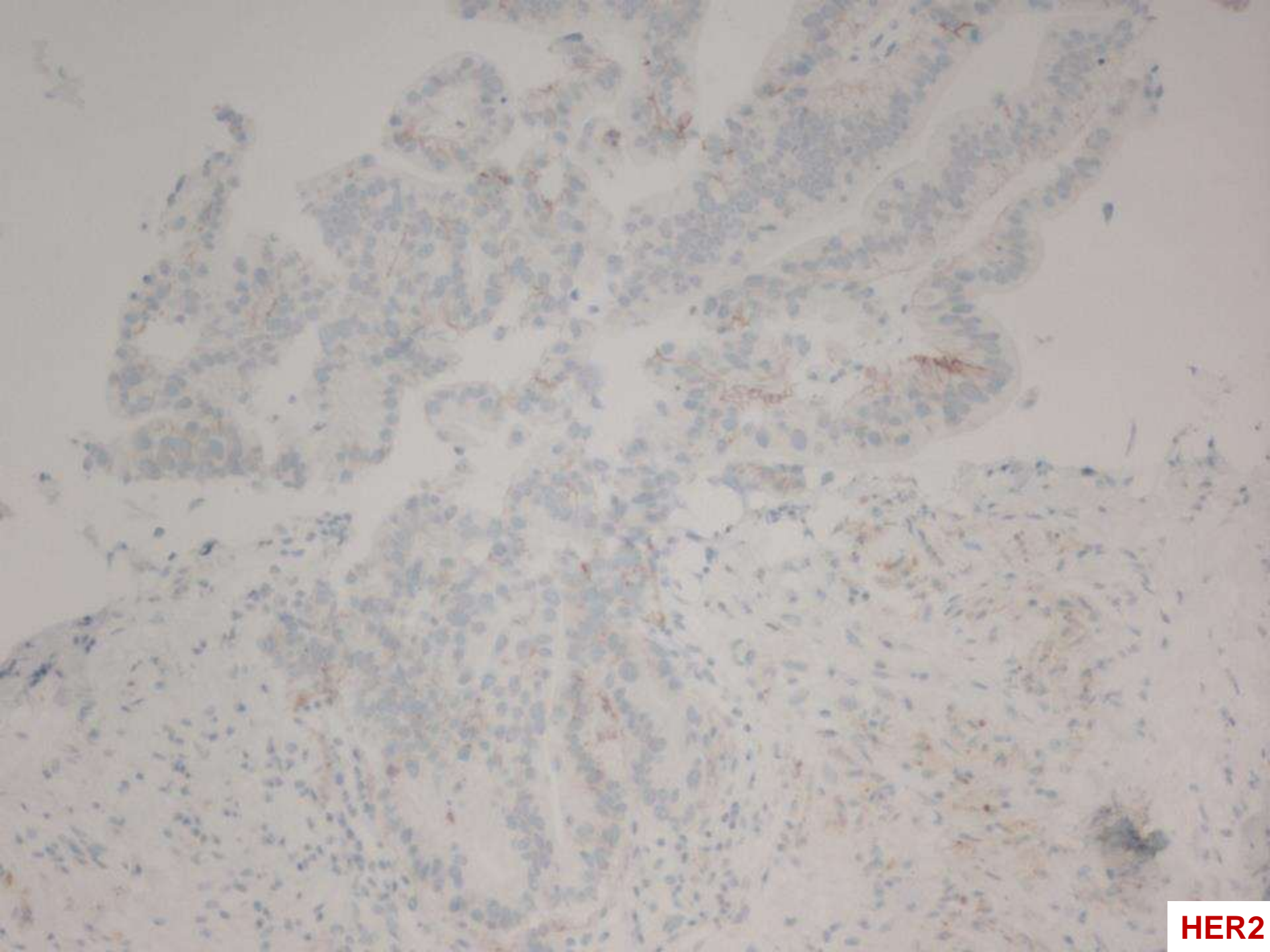




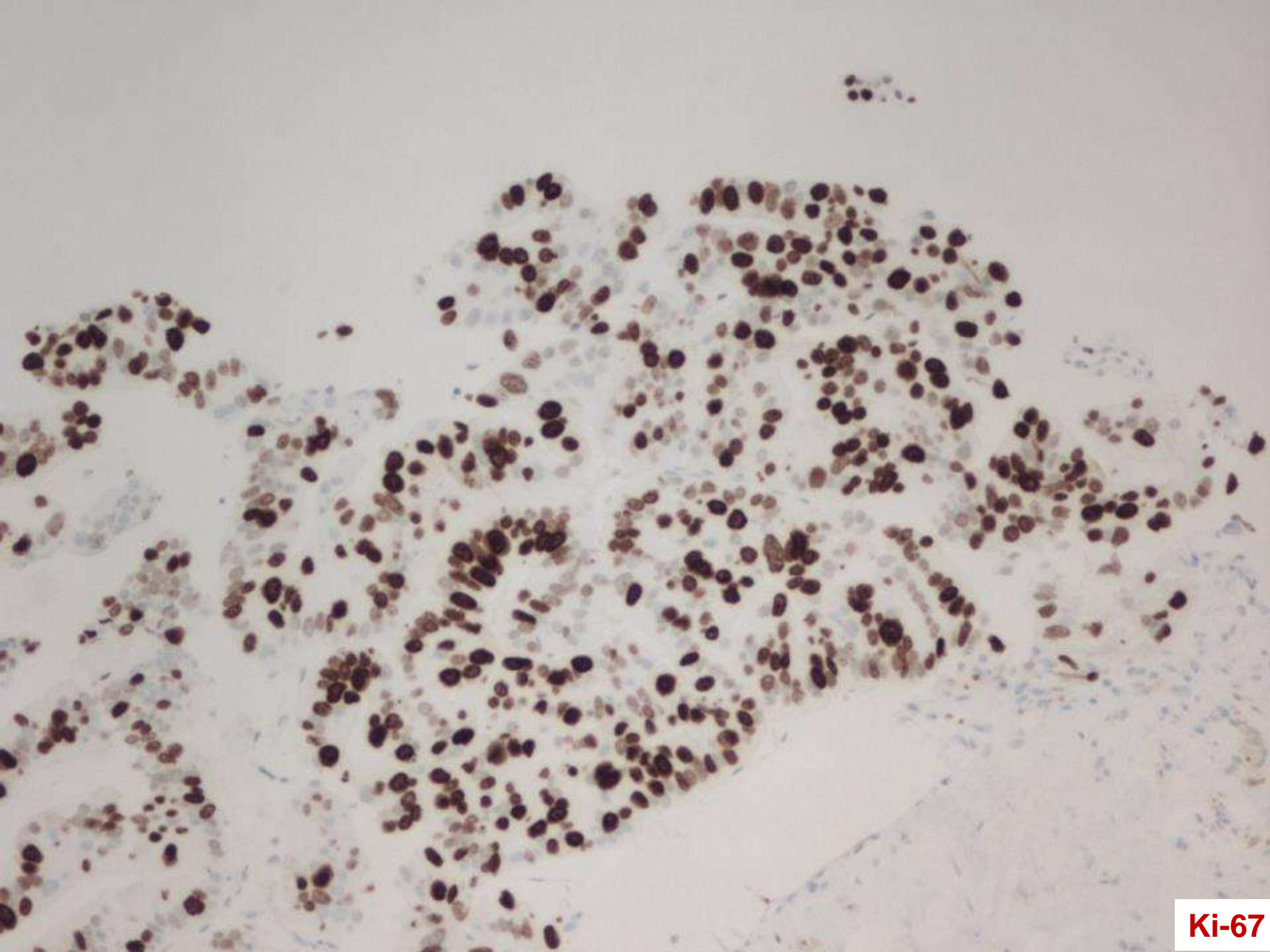




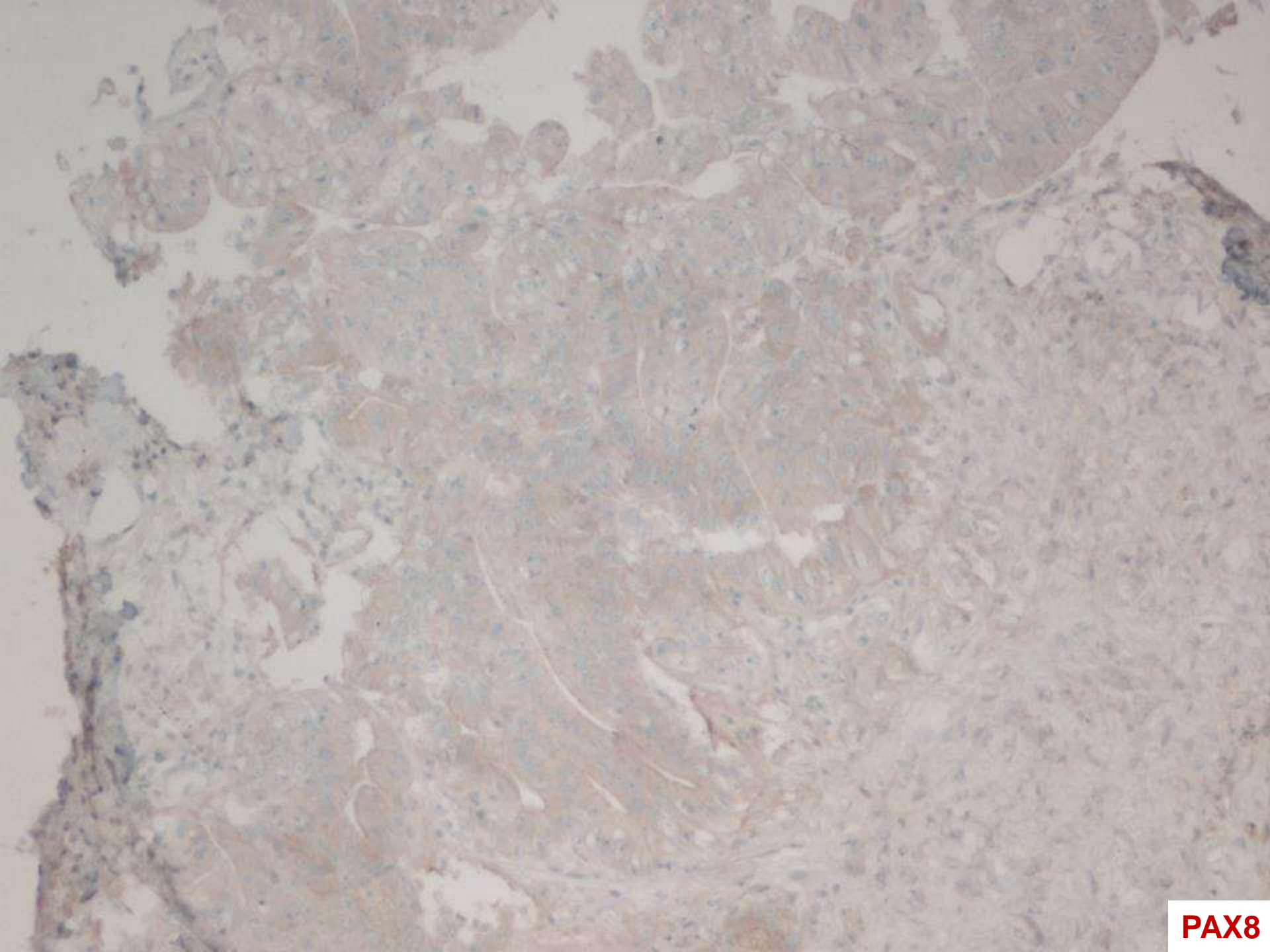




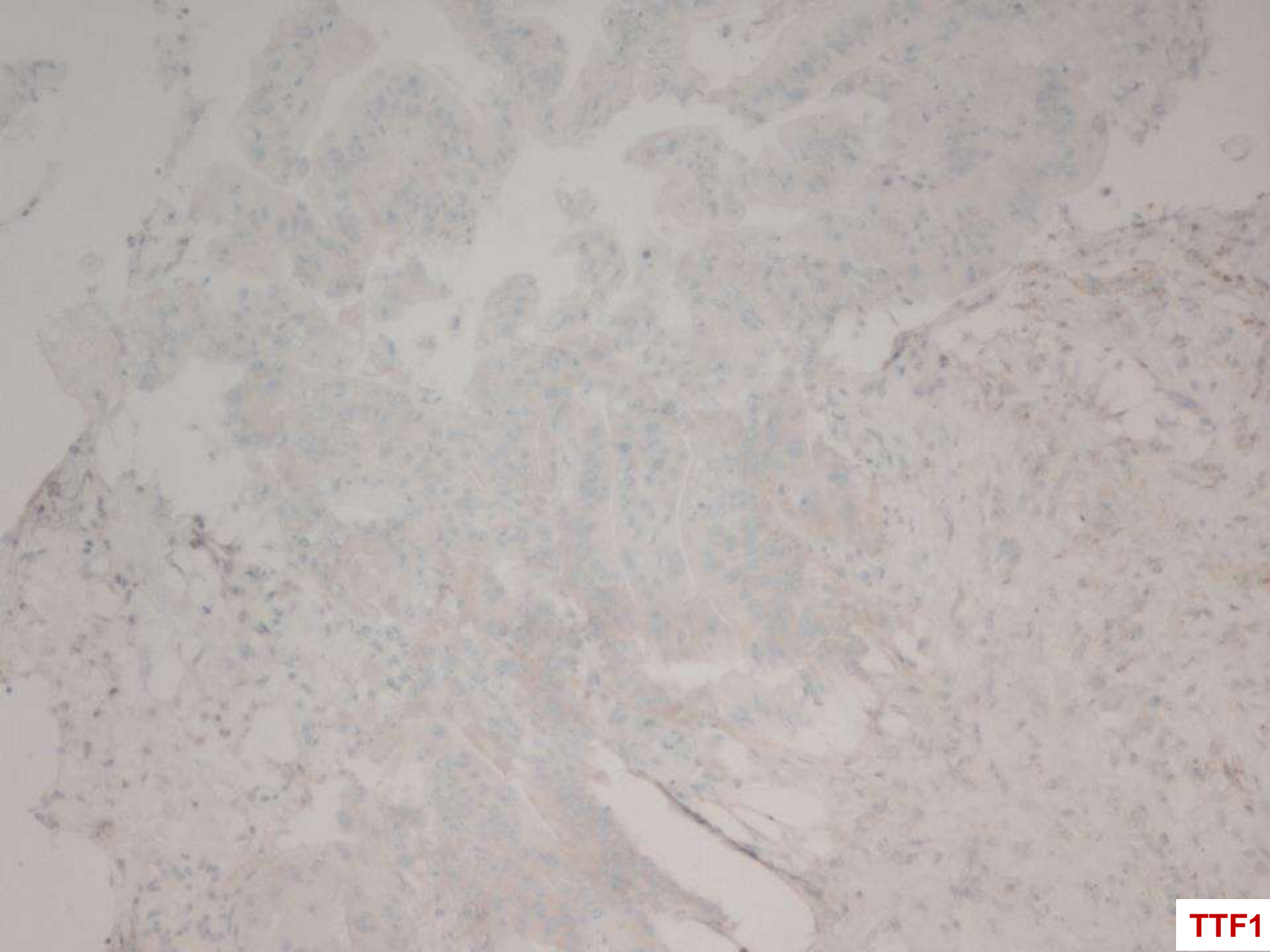
HER2



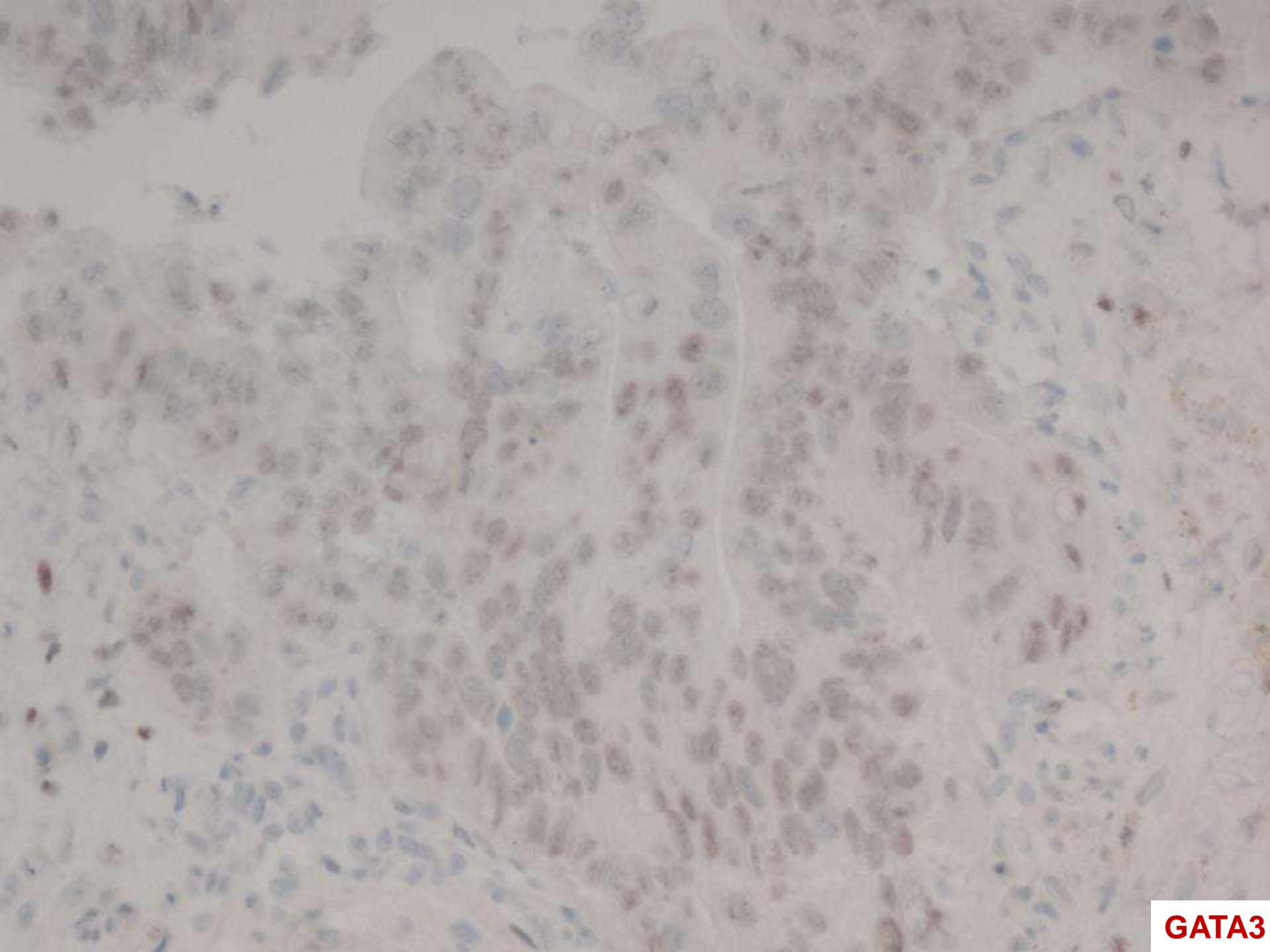
Ki-67



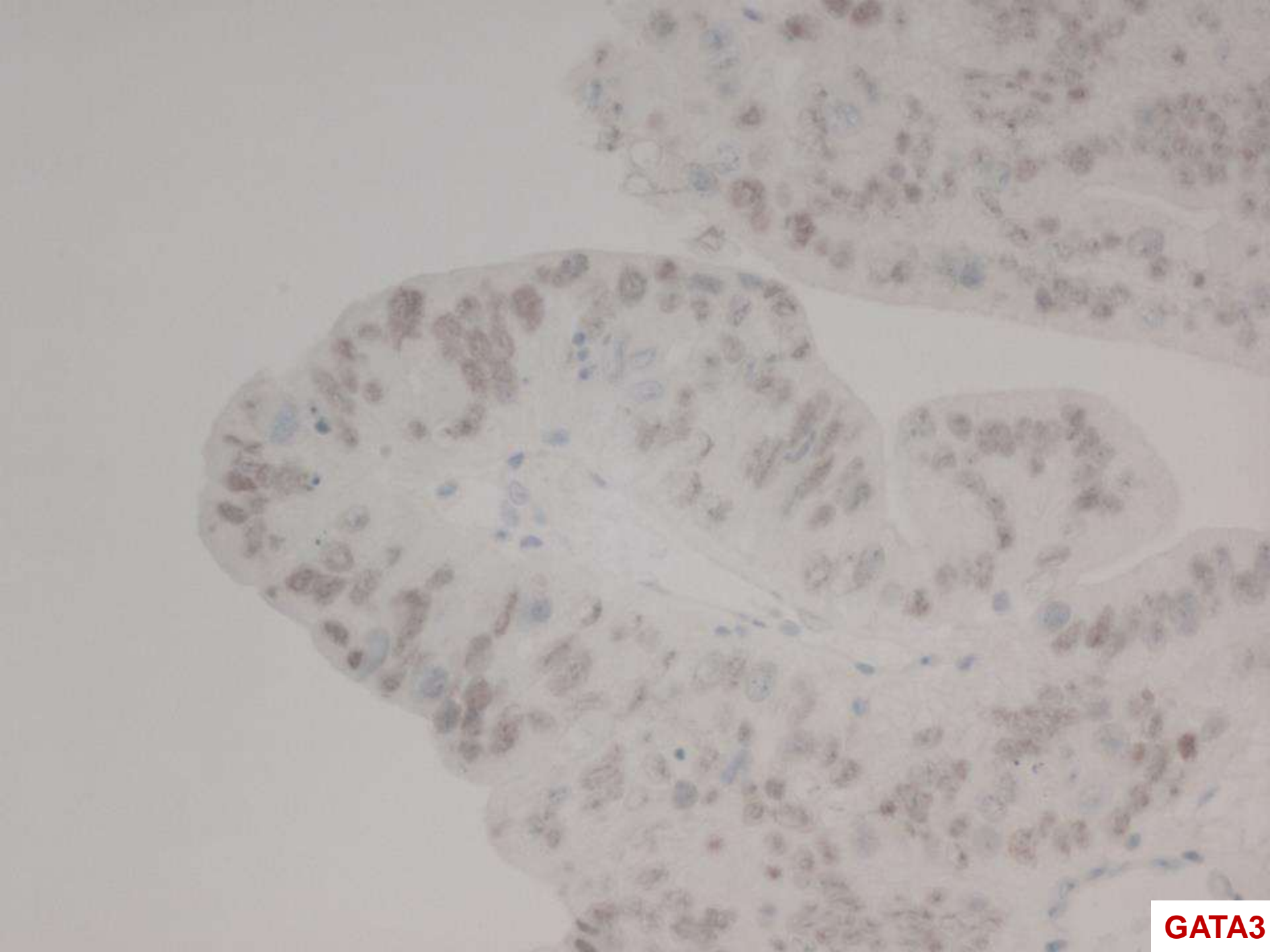
PAX8



TTF1

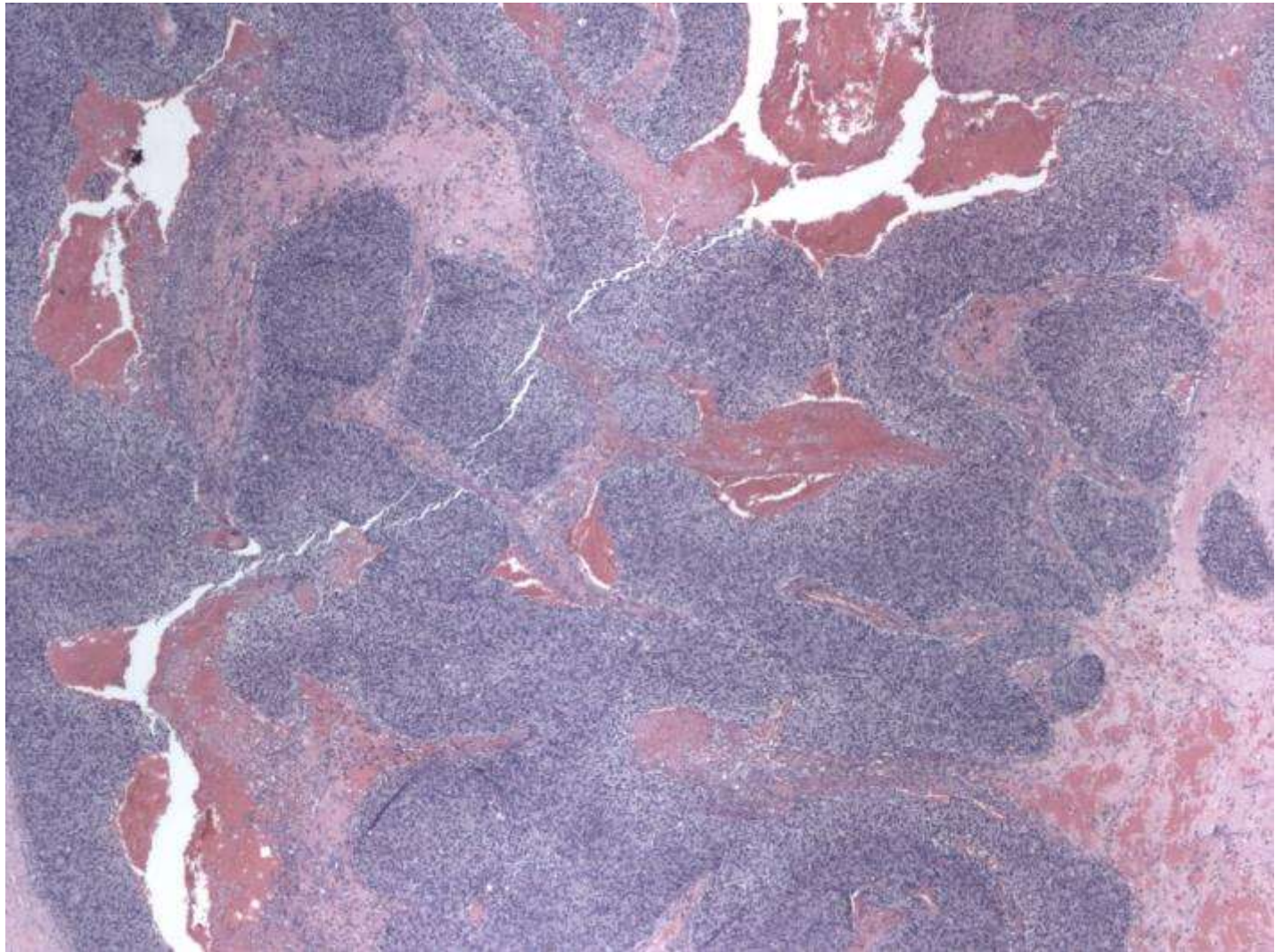


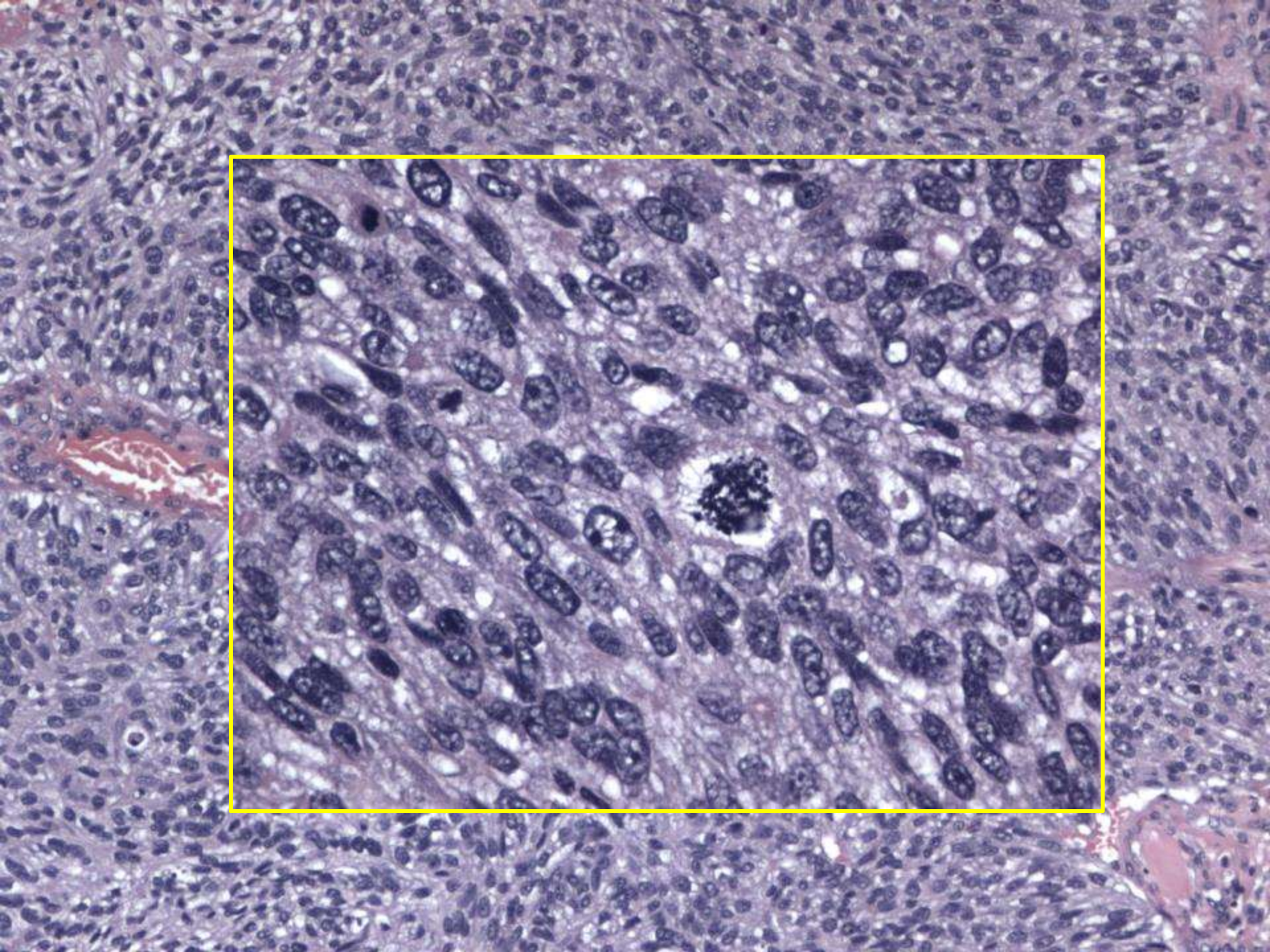
GATA3



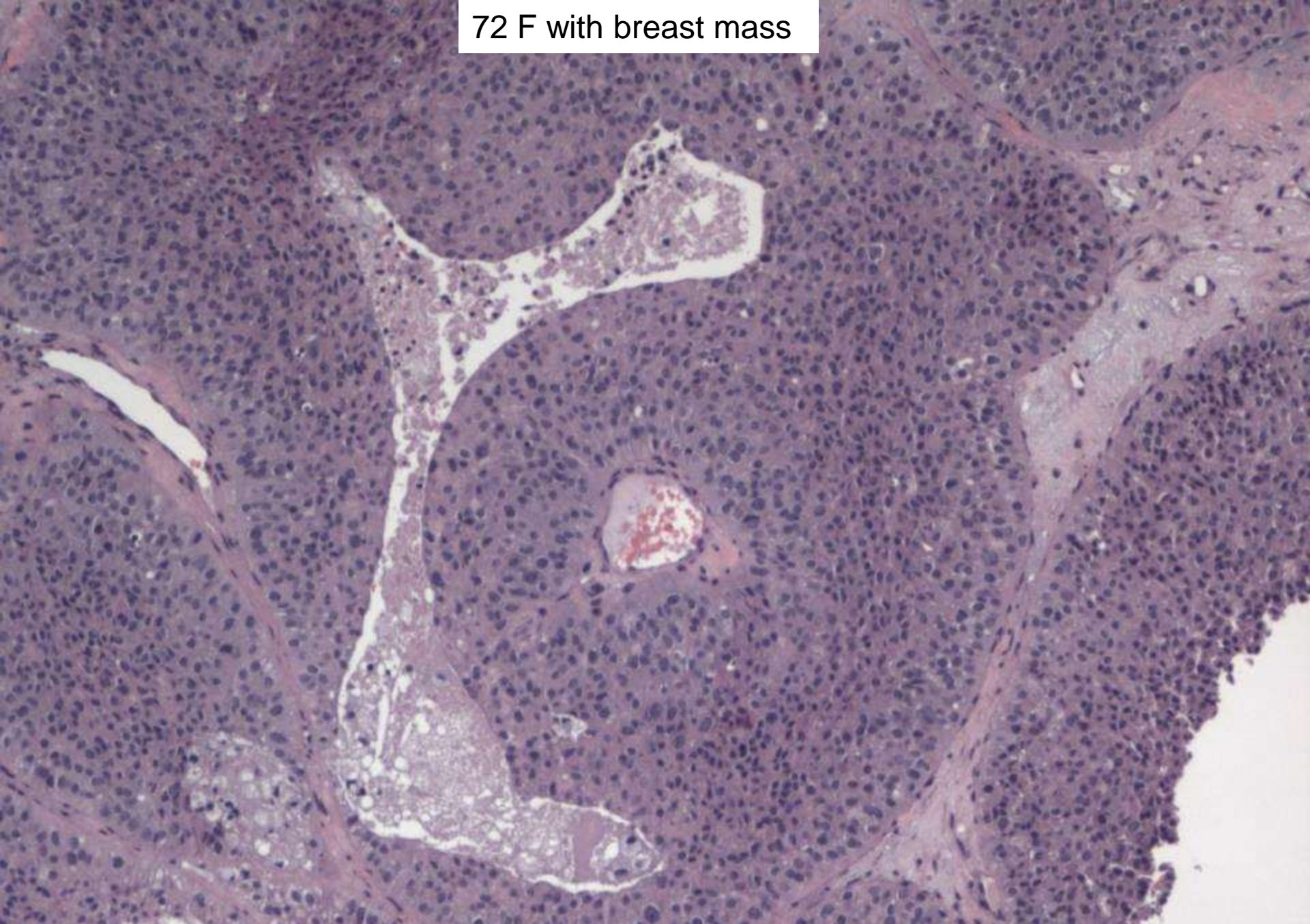
GATA3

Case that mimics SPC

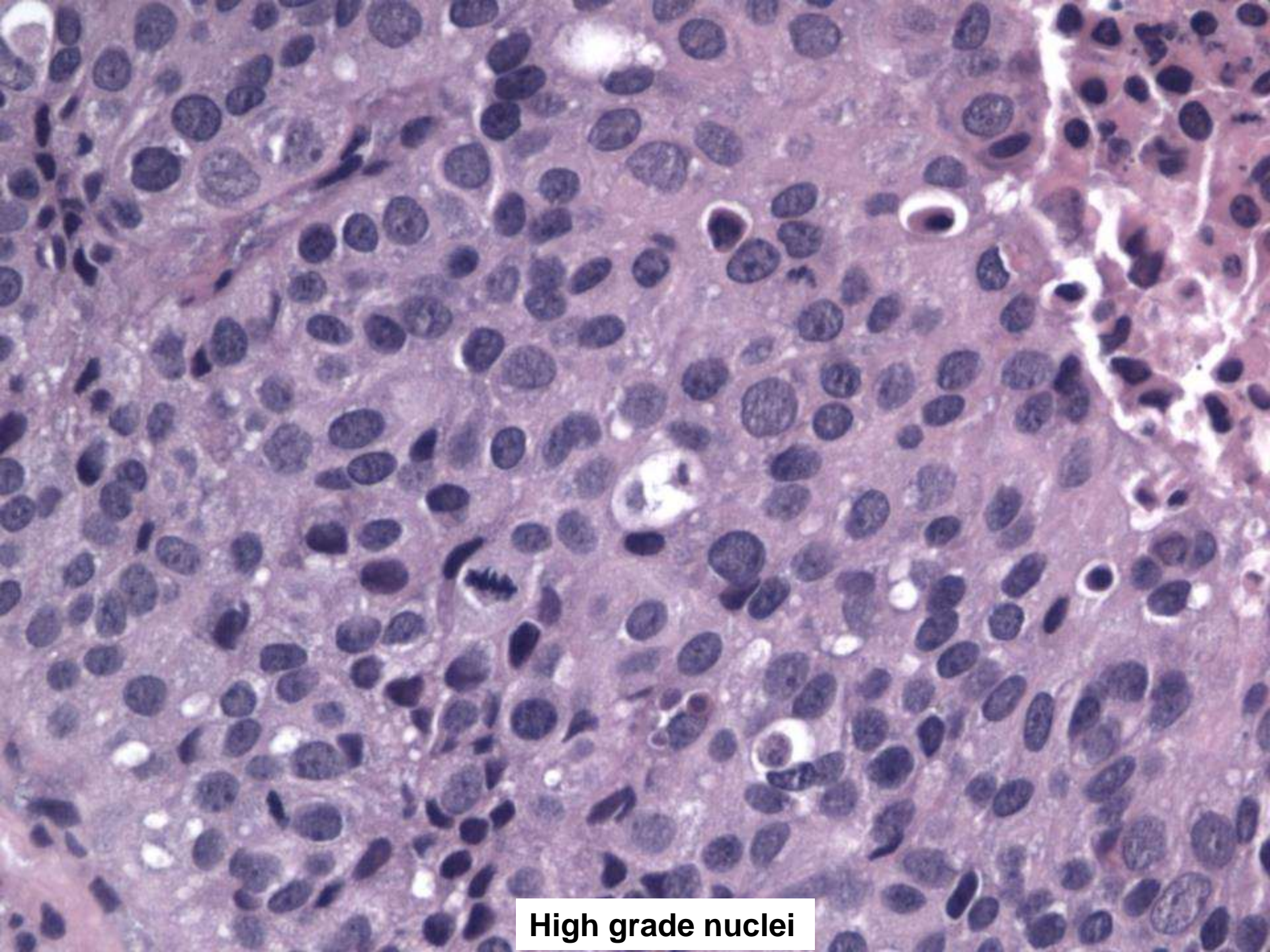




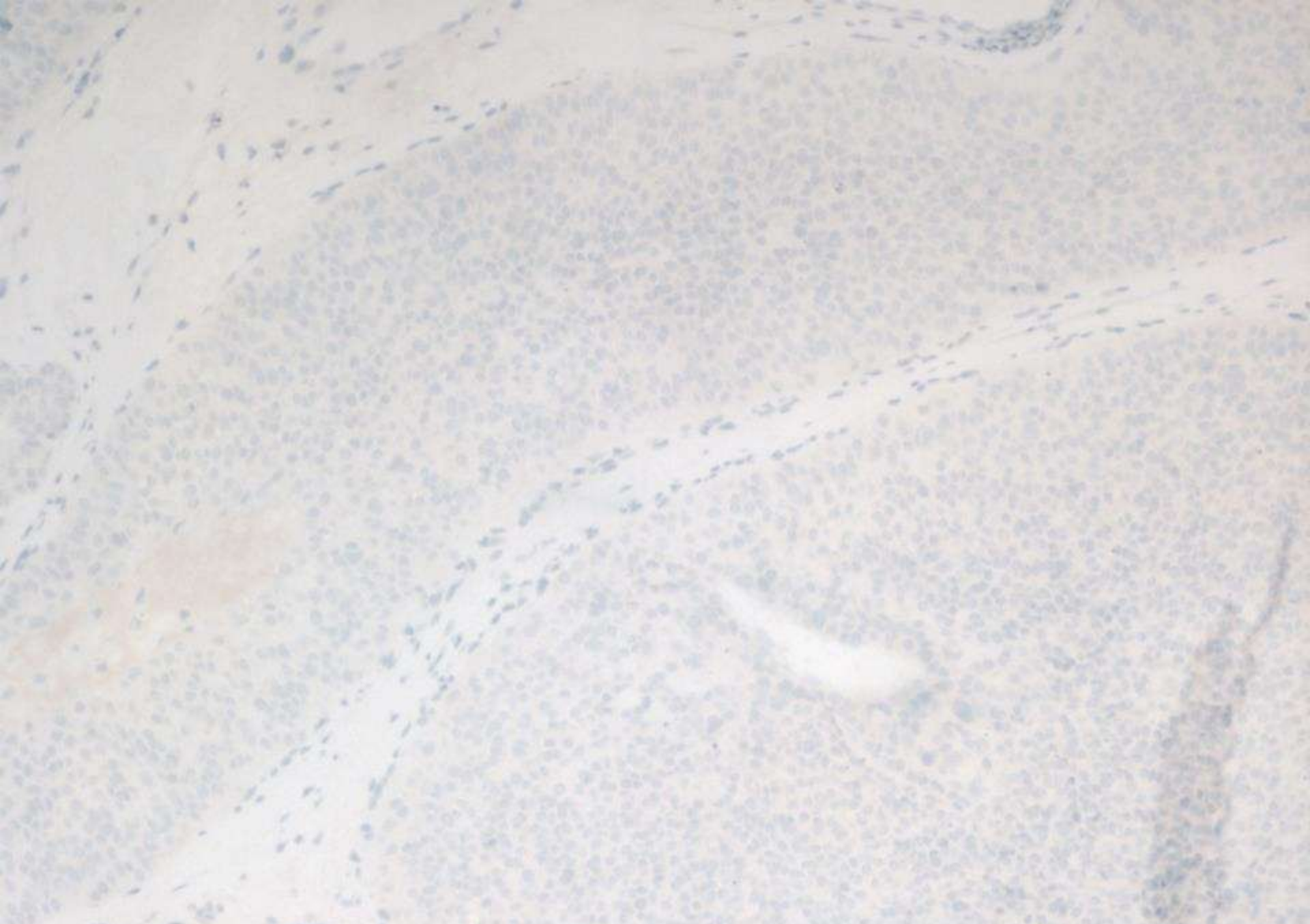72 F with breast mass



Tumor with solid papillary growth pattern but “confluent”



High grade nuclei



ER (similar staining for PR and myoepithelial markers)

When should you avoid diagnosing EPC/SPC?

- Solid confluent growth
 - Such tumors should be called invasive with solid-papillary growth pattern
- High grade nuclei (grade 3) and ER negative status
 - These are triple negative invasive tumors with “circumscribed” growth

EPC/SPC-Immunohistochemistry

Stains helpful in establishing a diagnosis of EPC or SPC

Stains	Expected pattern of staining
P63	Negative around the lesion
SMMHC	Negative around the lesion
ER	Strongly and diffusely positive
CK5	Negative in proliferating cells

Papillary Lesions

- Ranges from benign papilloma to invasive carcinoma

- Intraductal papilloma
- Papilloma with ADH
- Papilloma with DCIS
- Papillary DCIS

Clear

-
- Encapsulated (intracystic/encysted) papillary carcinoma
 - Solid papillary carcinoma

~~Confusing~~ Hopefully clear now!

-
- Invasive papillary carcinoma

Clear

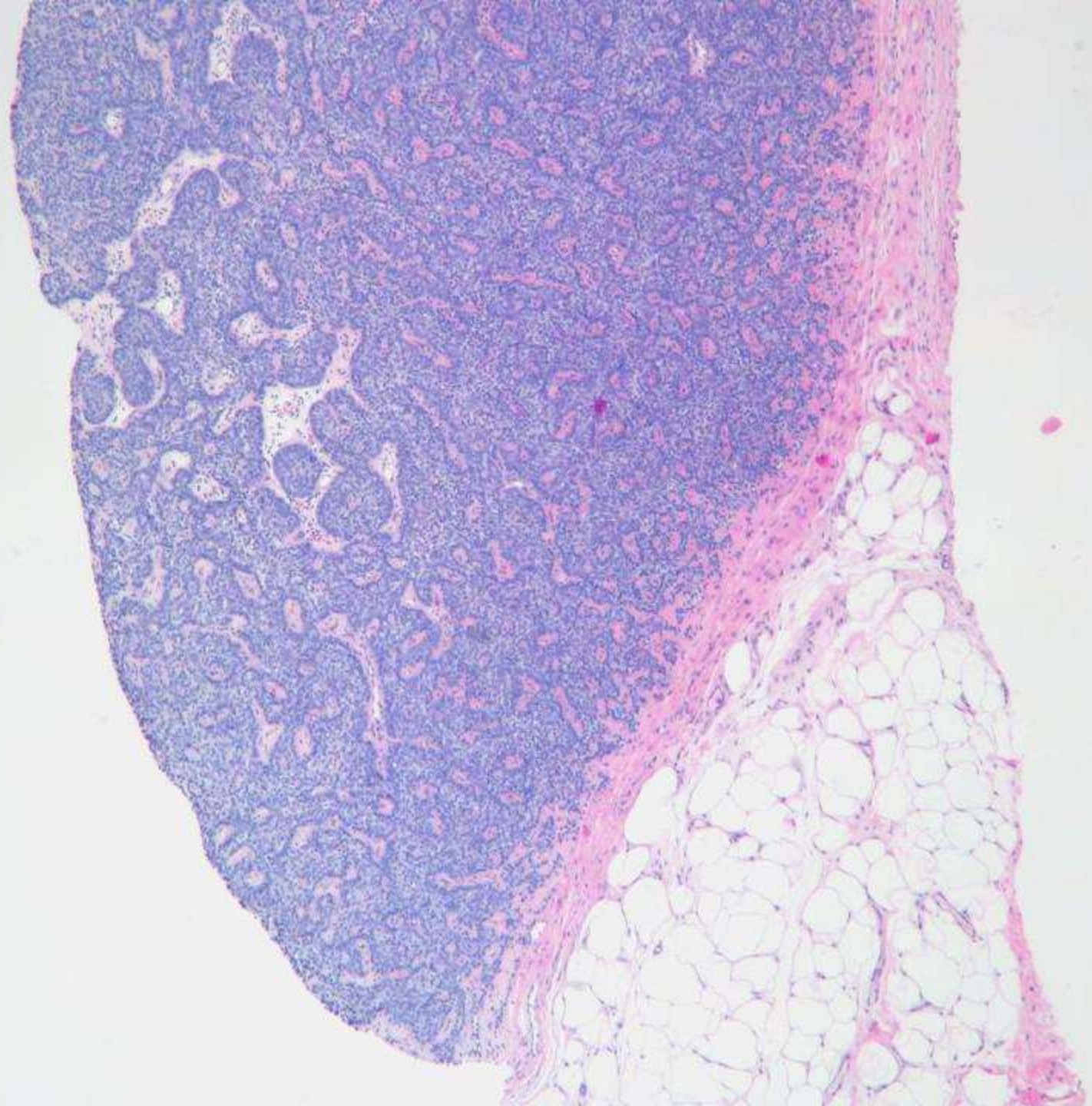
Are there any more papillary lesions of the breast?

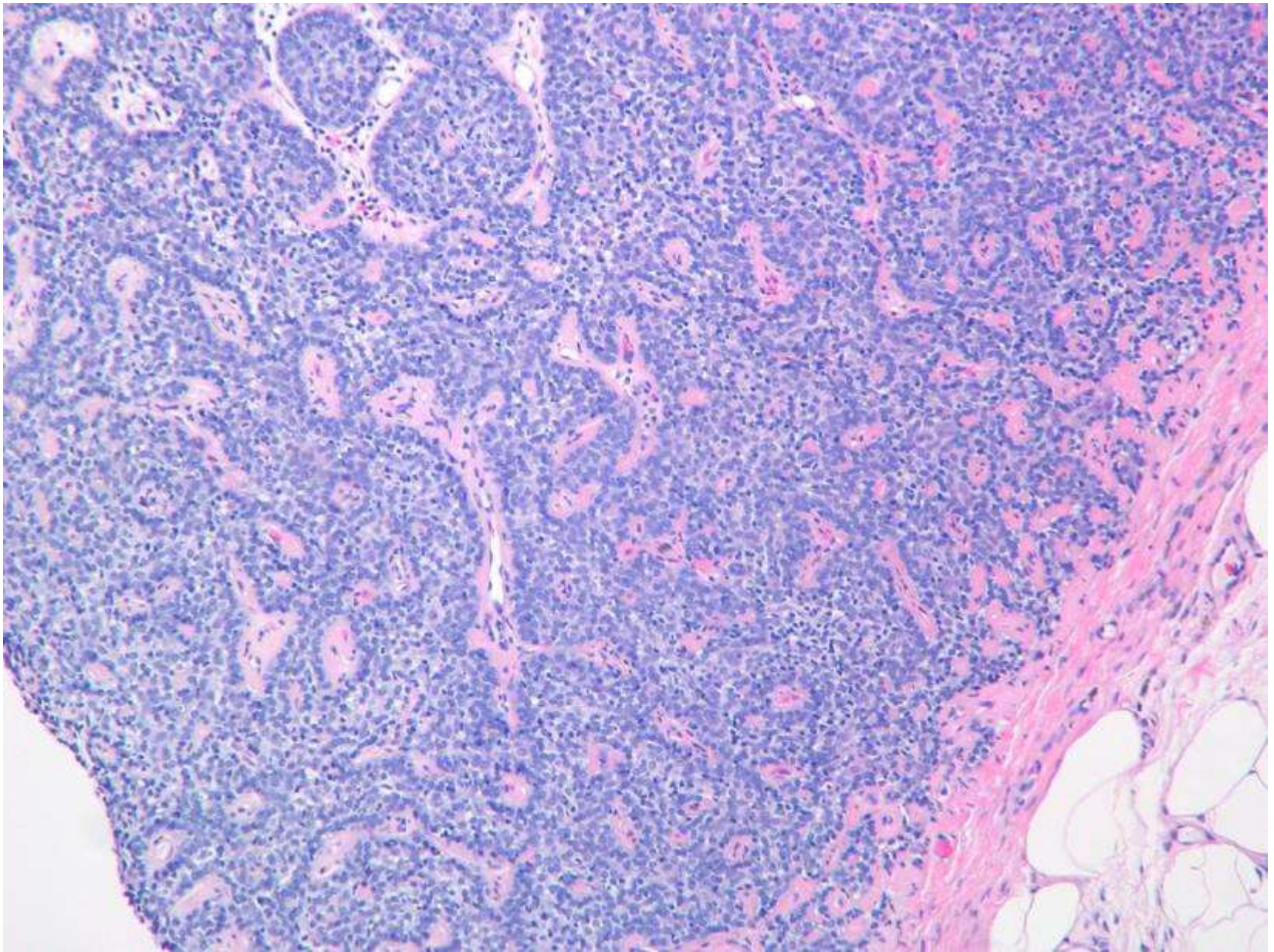
Two more papillary lesions!

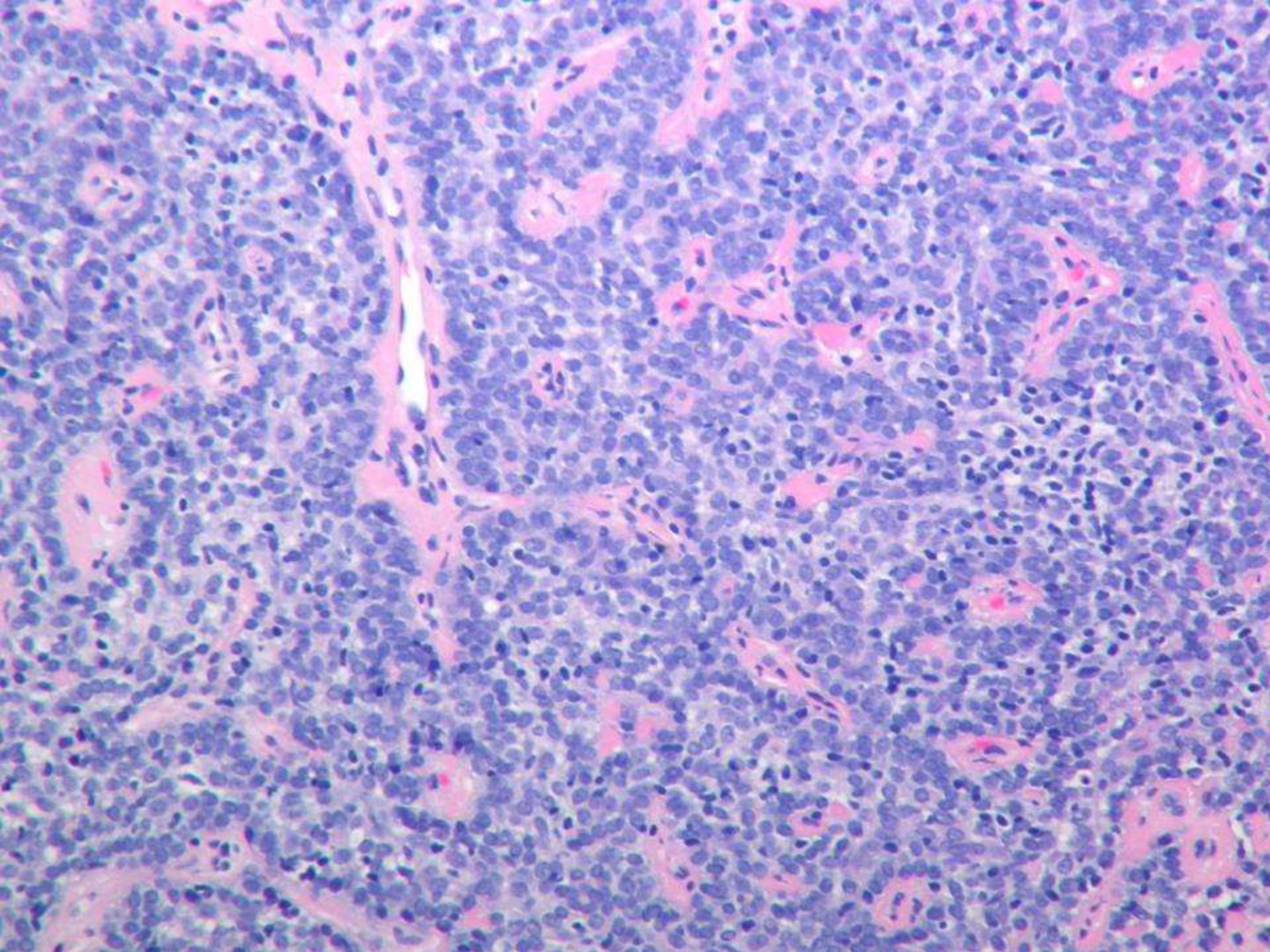
First additional papillary lesion-

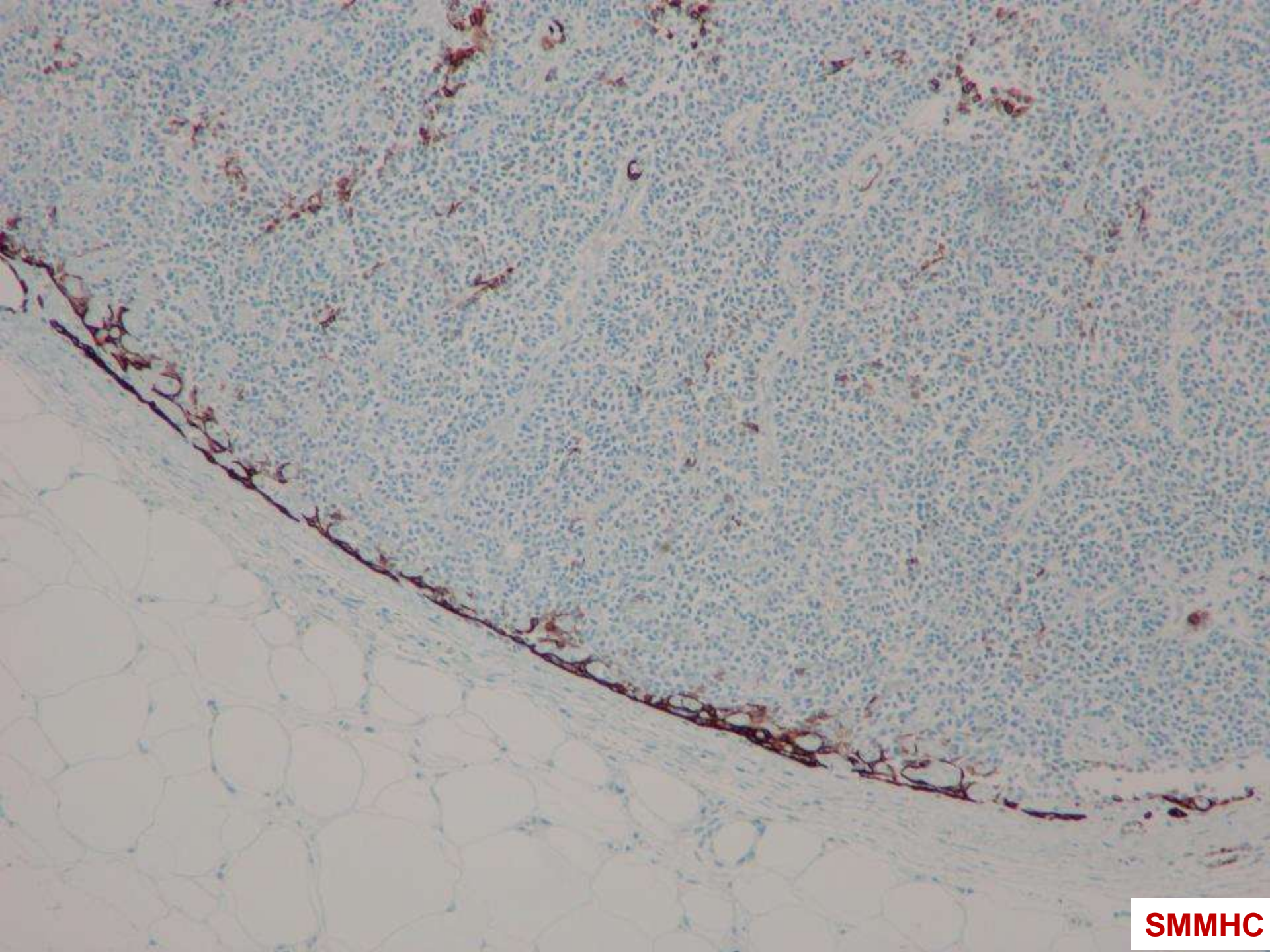
Case History

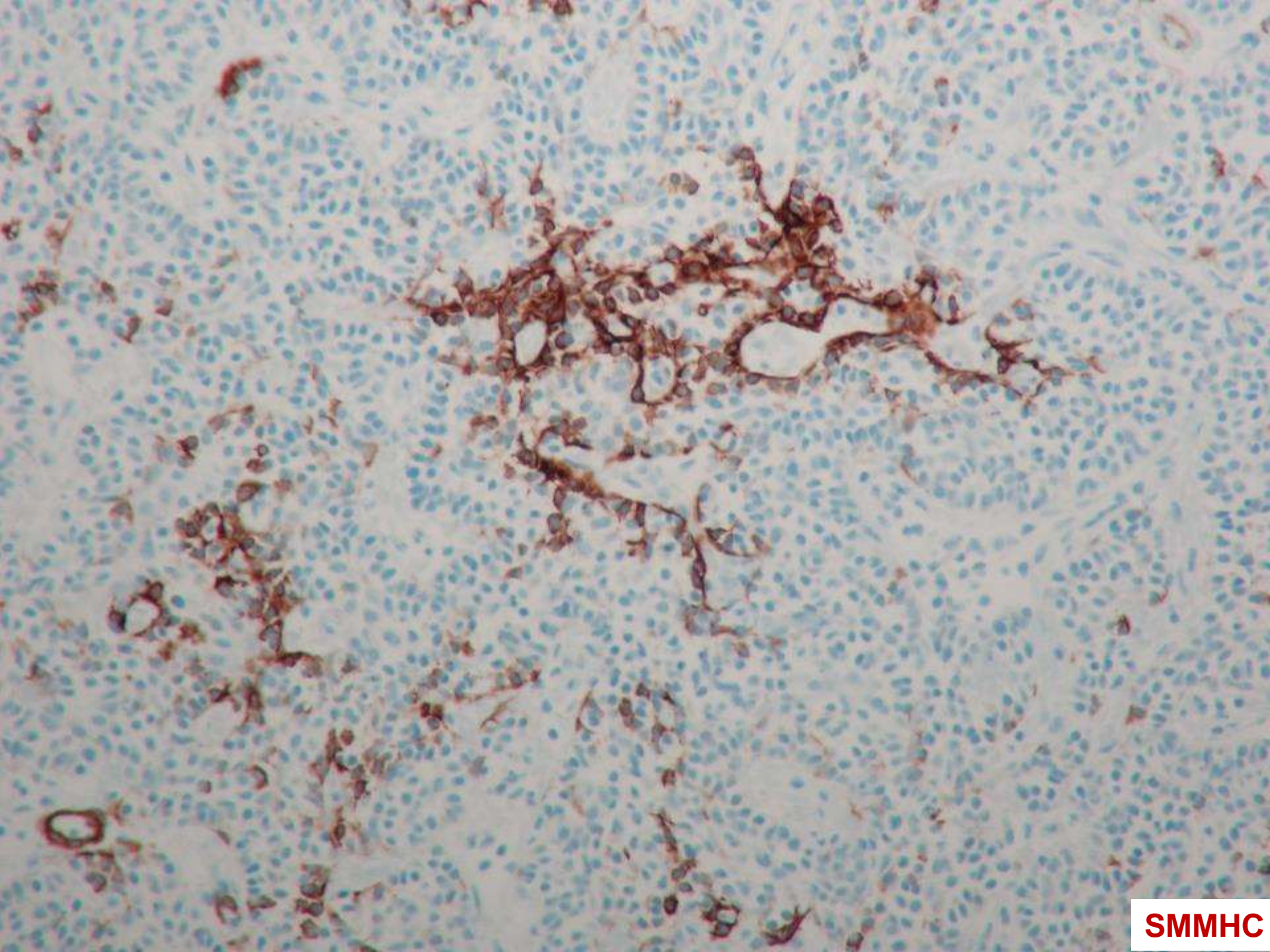
- Female, 57 years
- Left breast mass, ~ 1.0 cm
- FNA showed atypical ductal cells
- Core biopsy performed for definitive diagnosis

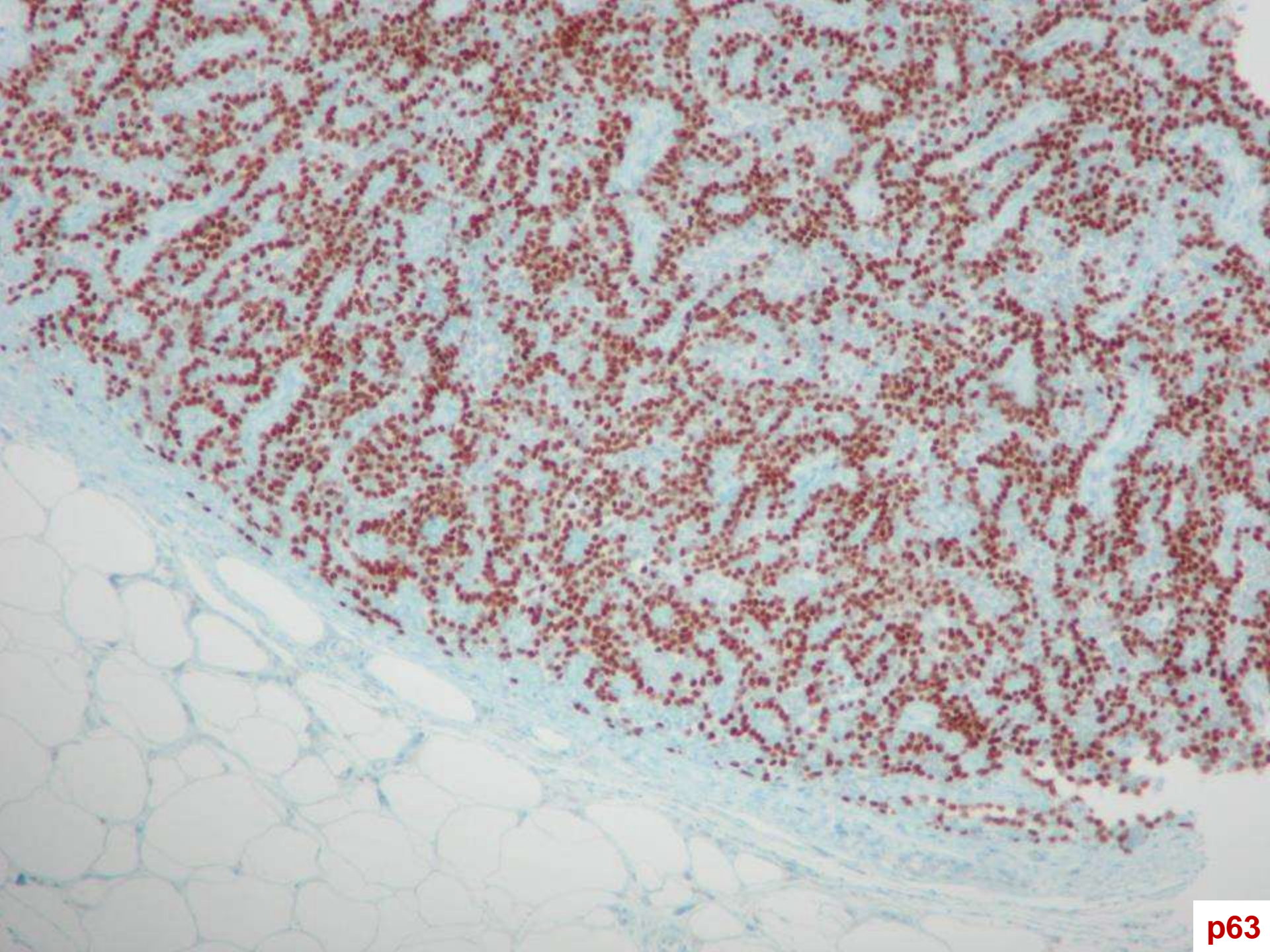


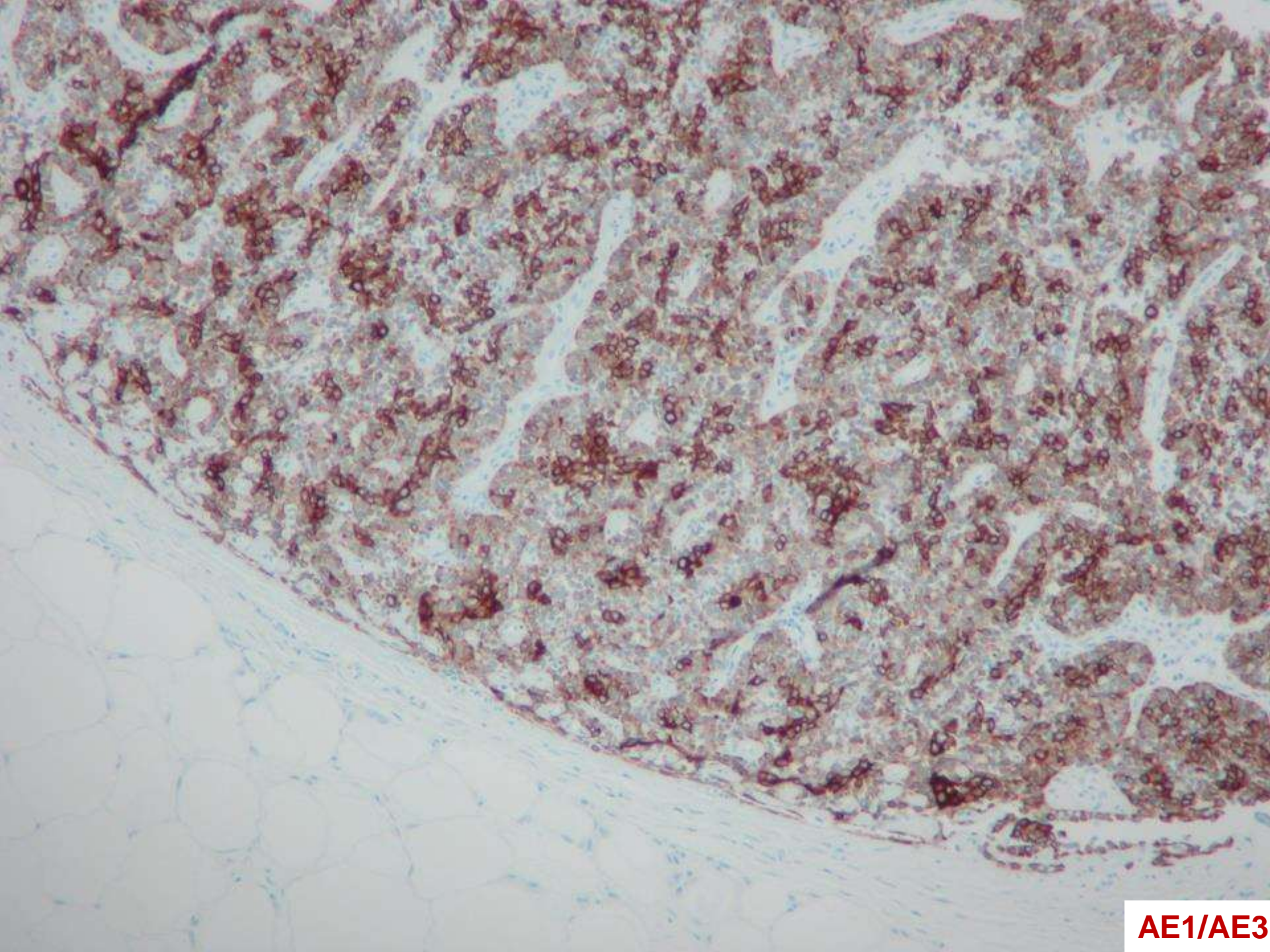












AE1/AE3

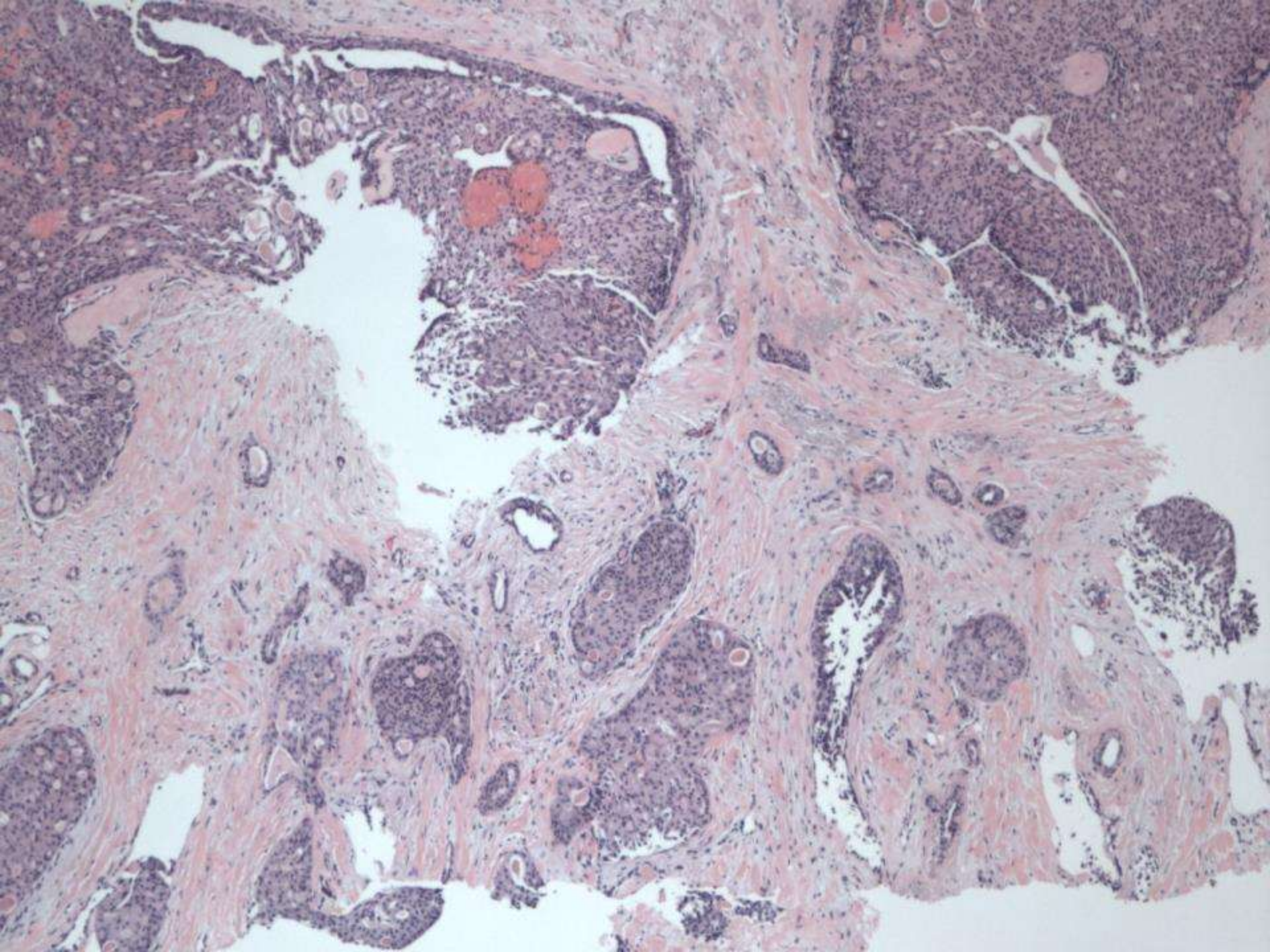
Adenomyoepithelioma (AME)

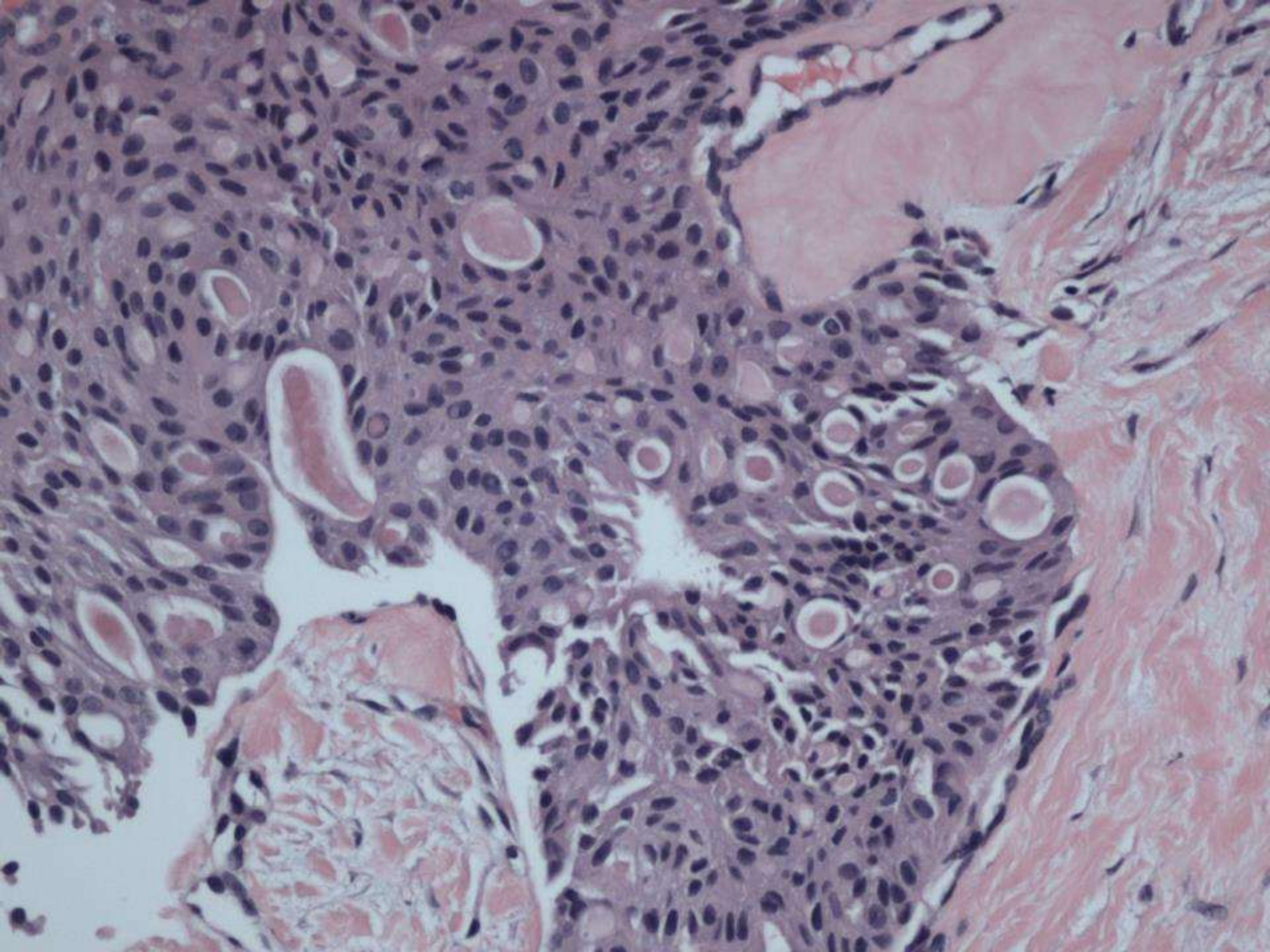
- Derived either from a papilloma or adenosis
- Two cell population: adeno (glandular) and myoepithelial
 - Appears as spindle cell lesion when myoepithelial cells are prominent
- Benign lesion with rare associated atypical ductal hyperplasia
- Malignancy can arise in AME but is extremely rare
- Excision often performed, mainly to confirm the diagnosis

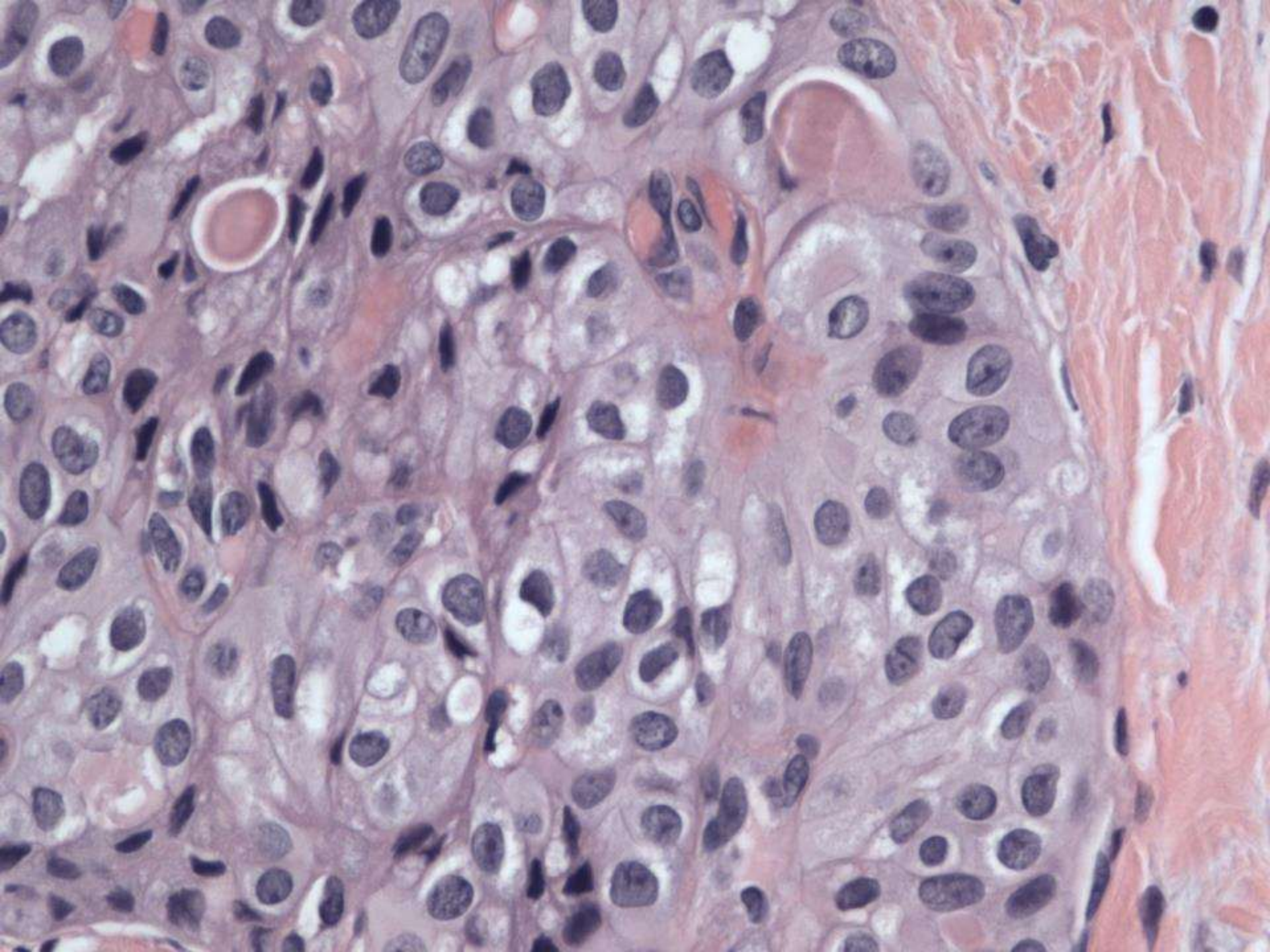
Second additional papillary lesion-

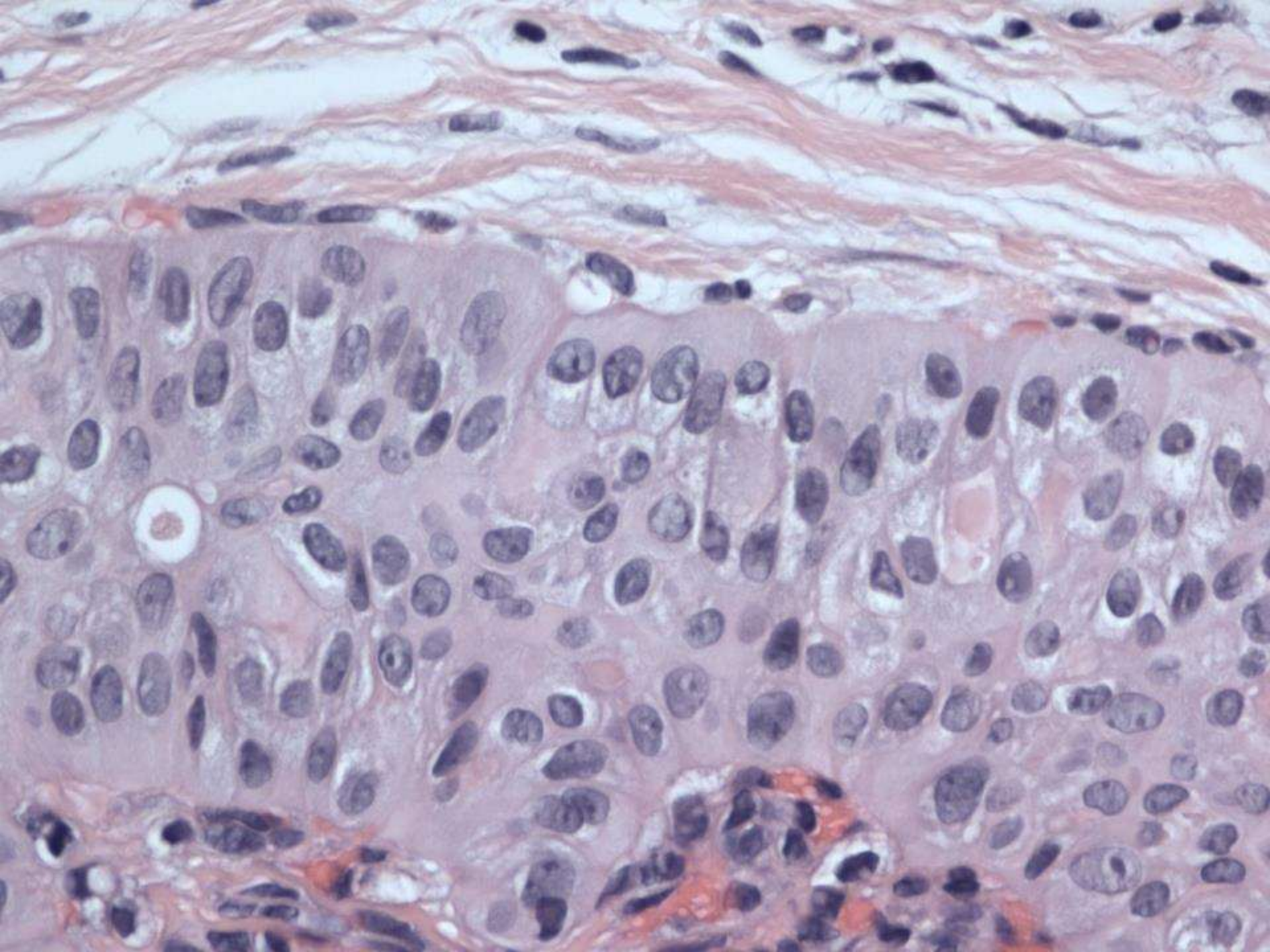
Case History

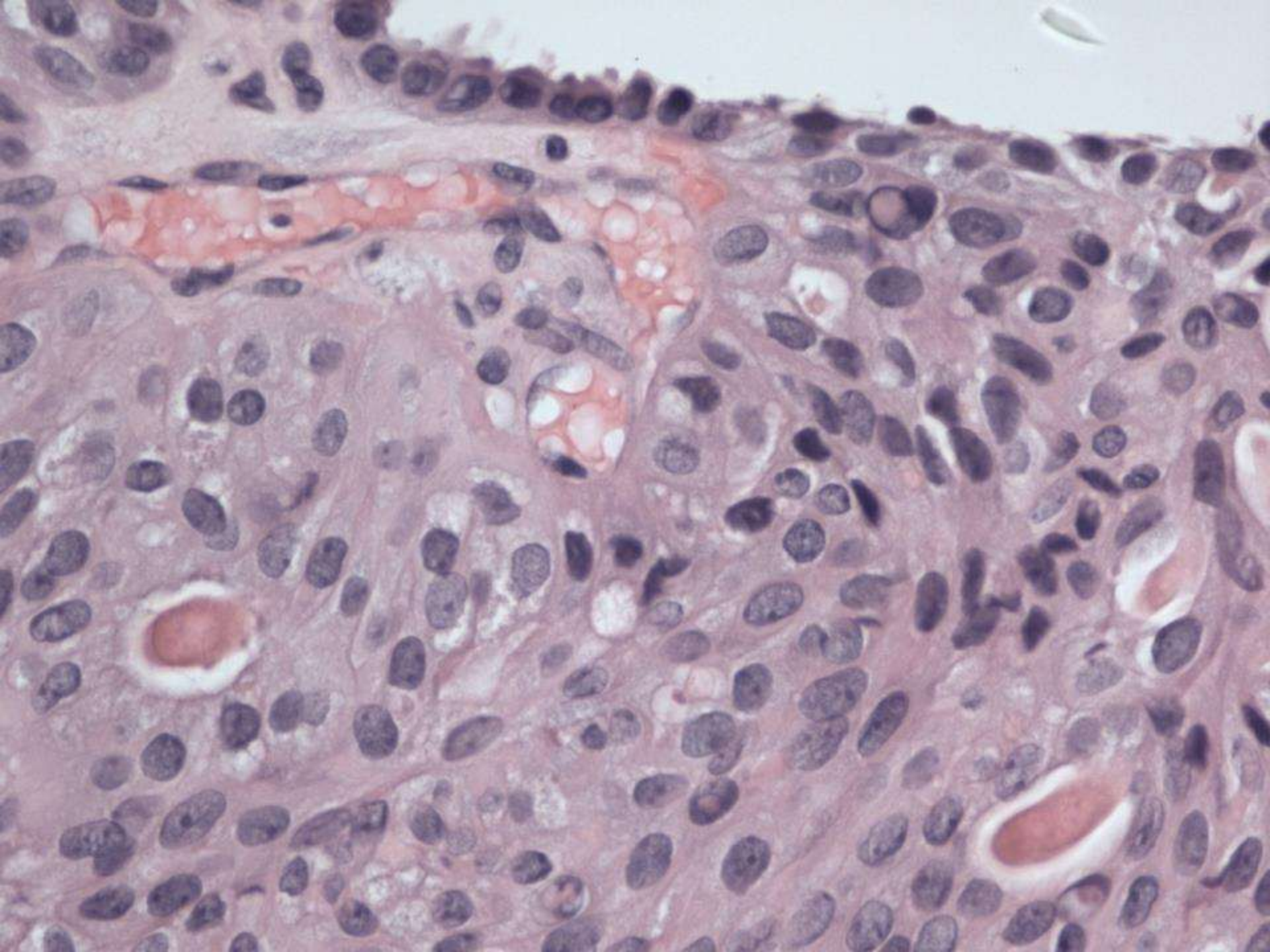
- Female, 48 years
- Contralateral (left breast) IDC, ERneg/PR weak pos, HER2+, recently diagnosed
 - B/L MRI for extent of disease
 - Irregular enhancing 1.2 cm mass in right breast
 - Core biopsy performed

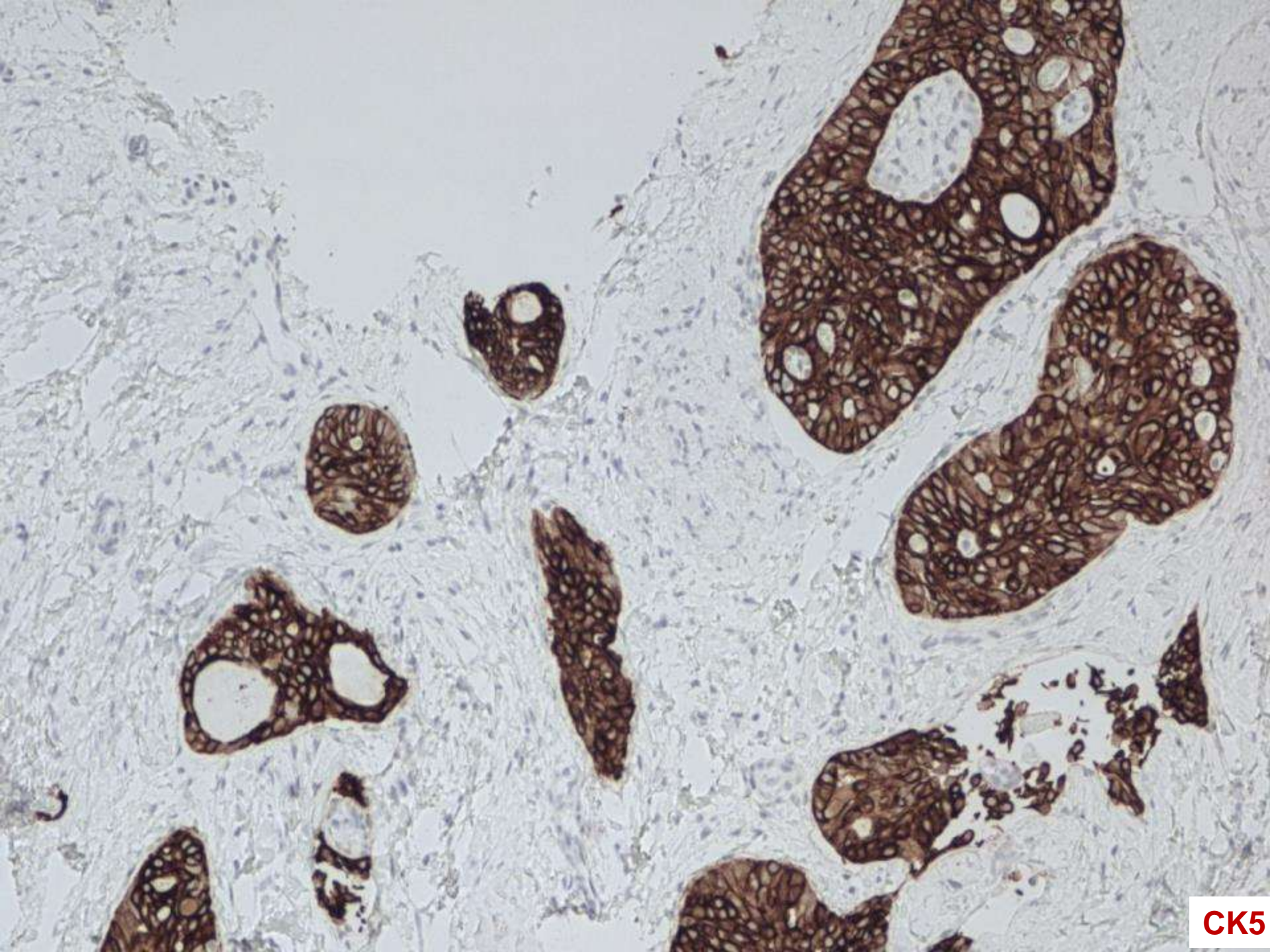


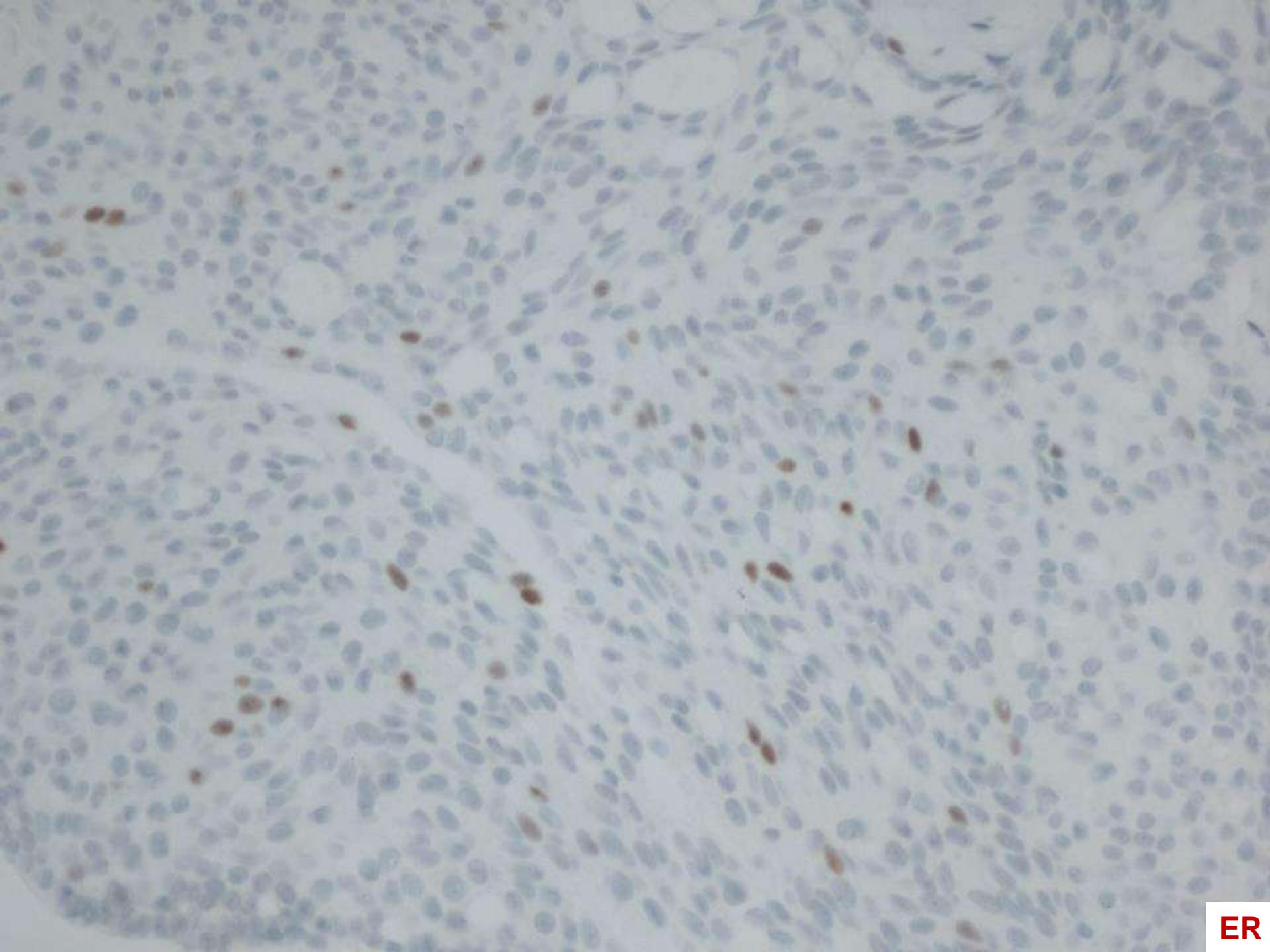


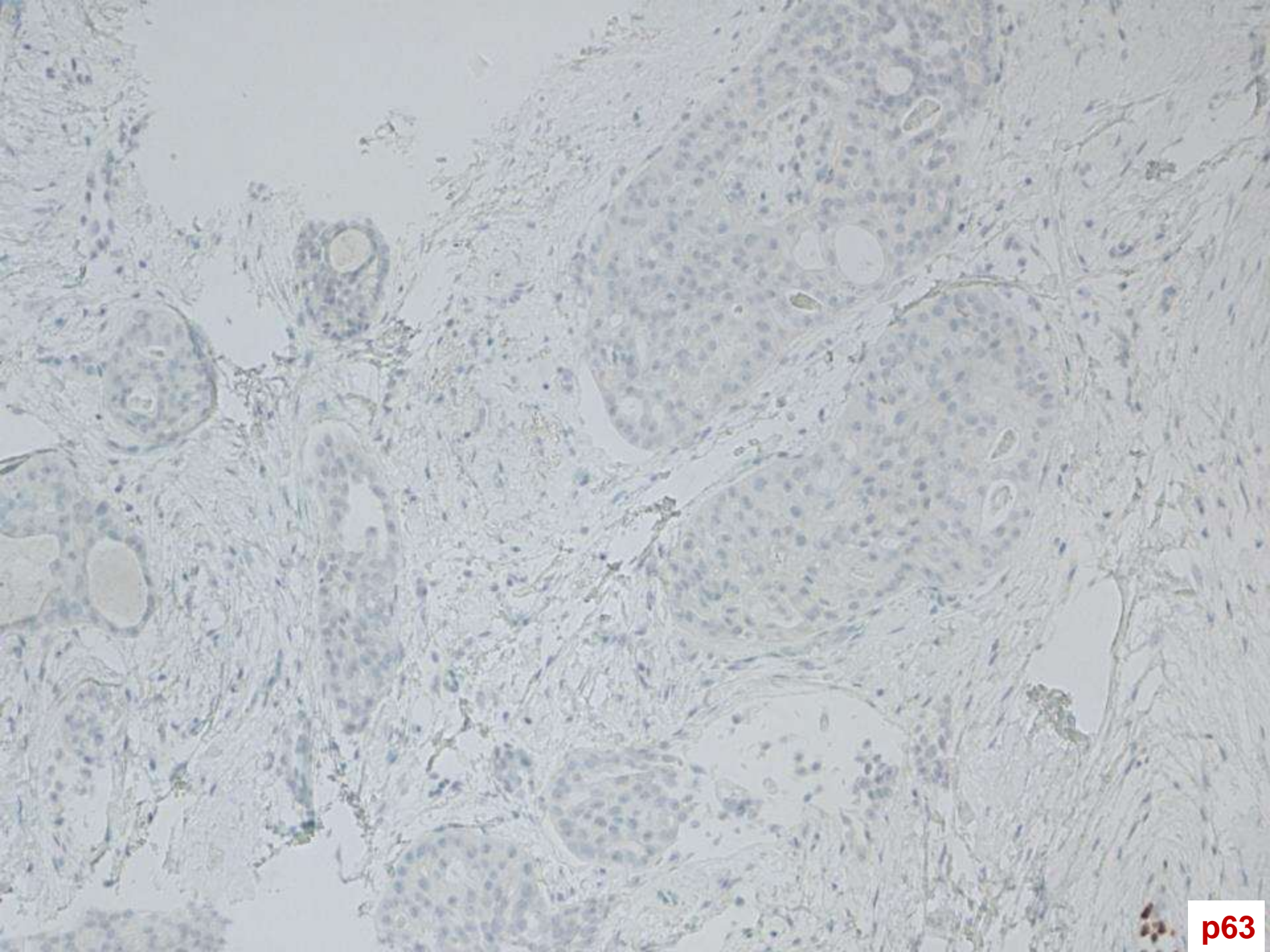


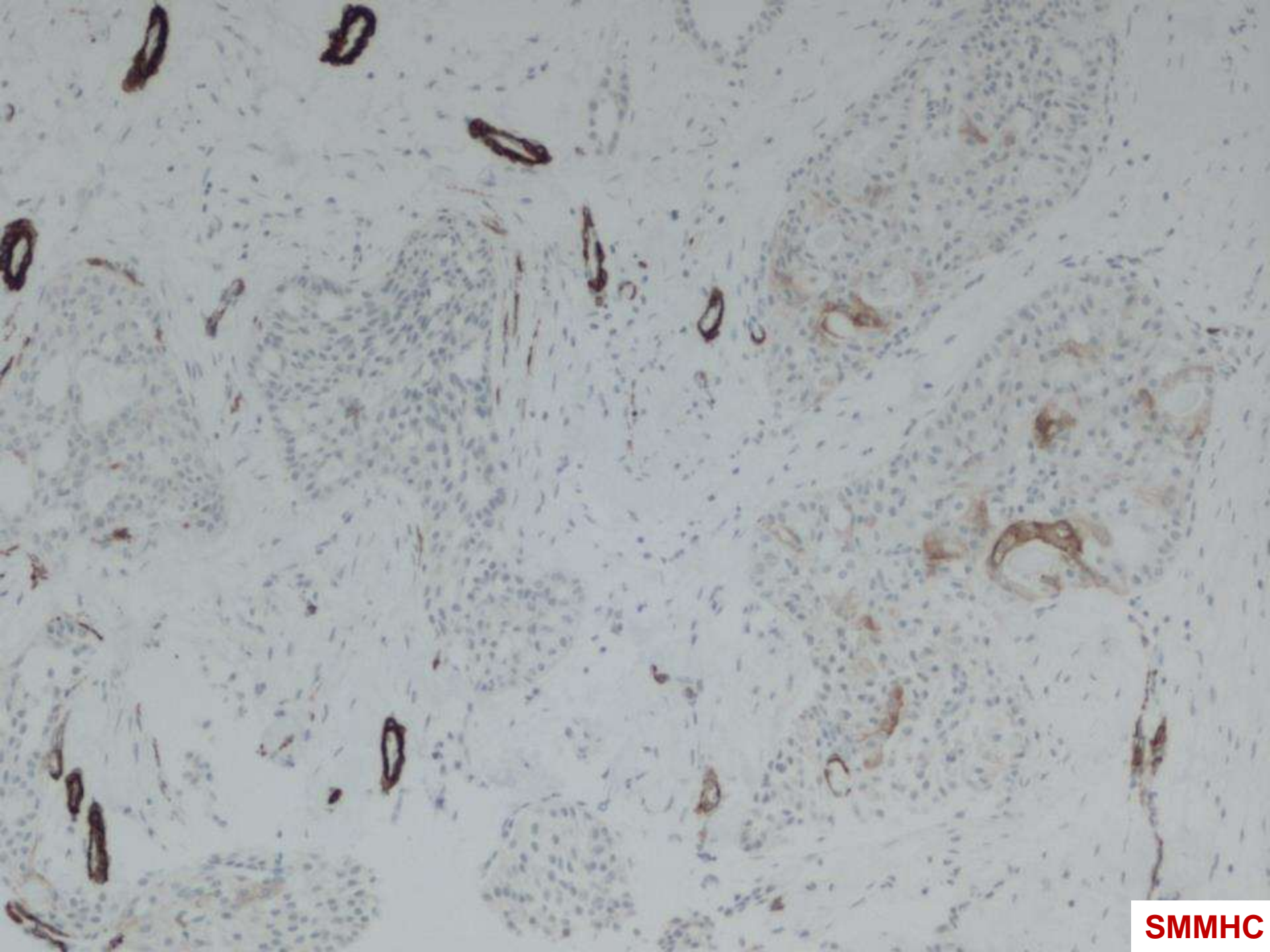












Differential Diagnosis

- Invasive carcinoma
- Solid papillary carcinoma
- Usual ductal hyperplasia
- Radial scar
- Intraductal papilloma

Diagnosis

Breast Tumor Resembling Tall Cell Variant of Papillary Thyroid Carcinoma
(BTRTCVPTC)

Also known as
Solid Papillary Neoplasm with Reverse Nuclear Polarization (SPNRNP)

BTRPTC

- First reported in 2003 by Eusebi et al in a series of 5 cases
- Total of 40 cases reported in the literature
- Morphological features quite similar among reported cases
- IHC variable depending on stains performed
 - Myoepithelial cells negative around lesions
 - Hormone receptors negative or weak
 - Positivity for basal phenotype markers

BTRPTC

- In most published cases, patients treated with wide local excision
 - Some cases with sentinel node biopsy and some with lymph node dissection, but close to half without lymph node sampling
- Rare patients treated with multi-modality therapy

BTRPTC

- Among the previously published 40 cases
 - Four reported cases of lymph node metastasis
 - Two case with only intra-mammary lymph node metastasis
 - One with axillary metastasis on recurrence at 60 months
 - One case with multiple positive lymph nodes at diagnosis and subsequently developed bone metastasis
 - IHC profile of this case different from others, also reported DCIS with comedo-necrosis in primary specimen (finding different from others)
 - Doubtful, if this case represents BTRTCVPTC
 - Other patients alive and well with no recurrence

BTRPTC-Molecular Profile

Cancer Res. 2016 Dec 15;76(24):7118-7129. Epub 2016 Oct 20.

IDH2 Mutations Define a Unique Subtype of Breast Cancer with Altered Nuclear Polarity.

Chiang S¹, Weigelt B², Wen HC², Pareja F², Raghavendra A², Martelotto LG², Burke KA², Basili T², Li A², Geyer FC², Piscuoglio S², Ng CK², Jungbluth AA², Balss J³, Pusch S³, Baker GM⁴, Cole KS⁵, von Deimling A^{3,6}, Batten JM⁷, Marotti JD⁸, Soh HC⁹, McCalip BL¹⁰, Serrano J¹¹, Lim RS², Siziopikou KP¹², Lu S¹³, Liu X¹⁴, Hammour T¹⁵, Brogi E², Snuderl M¹¹, Iafrate AJ^{7,16}, Reis-Filho JS², Schnitt SJ^{17,18}.

⊕ Author information

Abstract

Solid papillary carcinoma with reverse polarity (SPCRP) is a rare breast cancer subtype with an obscure etiology. In this study, we sought to describe its unique histopathologic features and to identify the genetic alterations that underpin SPCR using massively parallel whole-exome and targeted sequencing. The morphologic and immunohistochemical features of SPCR support the invasive nature of this subtype. Ten of 13 (77%) SPCRs harbored hotspot mutations at R172 of the isocitrate dehydrogenase IDH2, of which 8 of 10 displayed concurrent pathogenic mutations affecting PIK3CA or PIK3R1. One of the IDH2 wild-type SPCRs harbored a TET2 Q548* truncating mutation coupled with a PIK3CA H1047R hotspot mutation. Functional studies demonstrated that IDH2 and PIK3CA hotspot mutations are likely drivers of SPCR, resulting in its reversed nuclear polarization phenotype. Our results offer a molecular definition of SPCR as a distinct breast cancer subtype. Concurrent IDH2 and PIK3CA mutations may help diagnose SPCR and possibly direct effective treatment. *Cancer Res*; 76(24); 7118-29. ©2016 AACR.

©2016 American Association for Cancer Research.

PMID: 27913435

IDH2 mutations, at R172
PIK3CA mutation H1074R

BTRPTC

Am J Clin Pathol. 2017 Apr 1;147(4):399-410. doi: 10.1093/ajcp/aqx016.

Breast Tumor Resembling Tall Cell Variant of Papillary Thyroid Carcinoma: A Solid Papillary Neoplasm With Characteristic Immunohistochemical Profile and Few Recurrent Mutations.

Bhargava R¹, Florea AV², Pelmus M², Jones MW¹, Bonaventura M¹, Wald A³, Nikiforova M³.

Author Information

Abstract

OBJECTIVES: Breast tumor resembling tall cell variant of papillary thyroid carcinoma (BTRPTC) is a rare breast lesion that is unrelated to thyroid carcinoma. Morphologically, it shows a solid papillary lesion with bland cytology, eosinophilic/amphophilic secretions, nuclear grooves, reversal of nuclear polarity (recently described), and nuclear inclusions. Clinical course is often uneventful with few exceptions reported in the literature. Herein, we report three additional cases.

METHODS: Immunohistochemical staining and next-generation sequencing was performed on all three cases.

RESULTS: The lesional cells on all cases were positive for cytokeratin 5 and S100, with weak expression/lack of estrogen receptor. No staining was observed for myoepithelial markers (p63 and myosin heavy chain) around the lesion. IDH2 mutations were identified in two cases at nucleotide 172 (cases 1 and 3). ATM gene mutation was identified in cases 2 and 3 and PIK3CA mutation in case 3. All patients are currently without disease.

CONCLUSIONS: BTRPTC is a slow-growing neoplastic lesion that needs to be distinguished from other papillary lesions for optimizing therapy.

KEYWORDS: ATM; Breast tumor resembling tall cell variant of papillary thyroid carcinoma; CK5; ER; IDH2; Myoepithelial markers; PIK3CA mutations; Reverse nuclear polarity; Solid papillary neoplasm

PMID: 28375433 DOI: [10.1093/ajcp/aqx016](https://doi.org/10.1093/ajcp/aqx016)

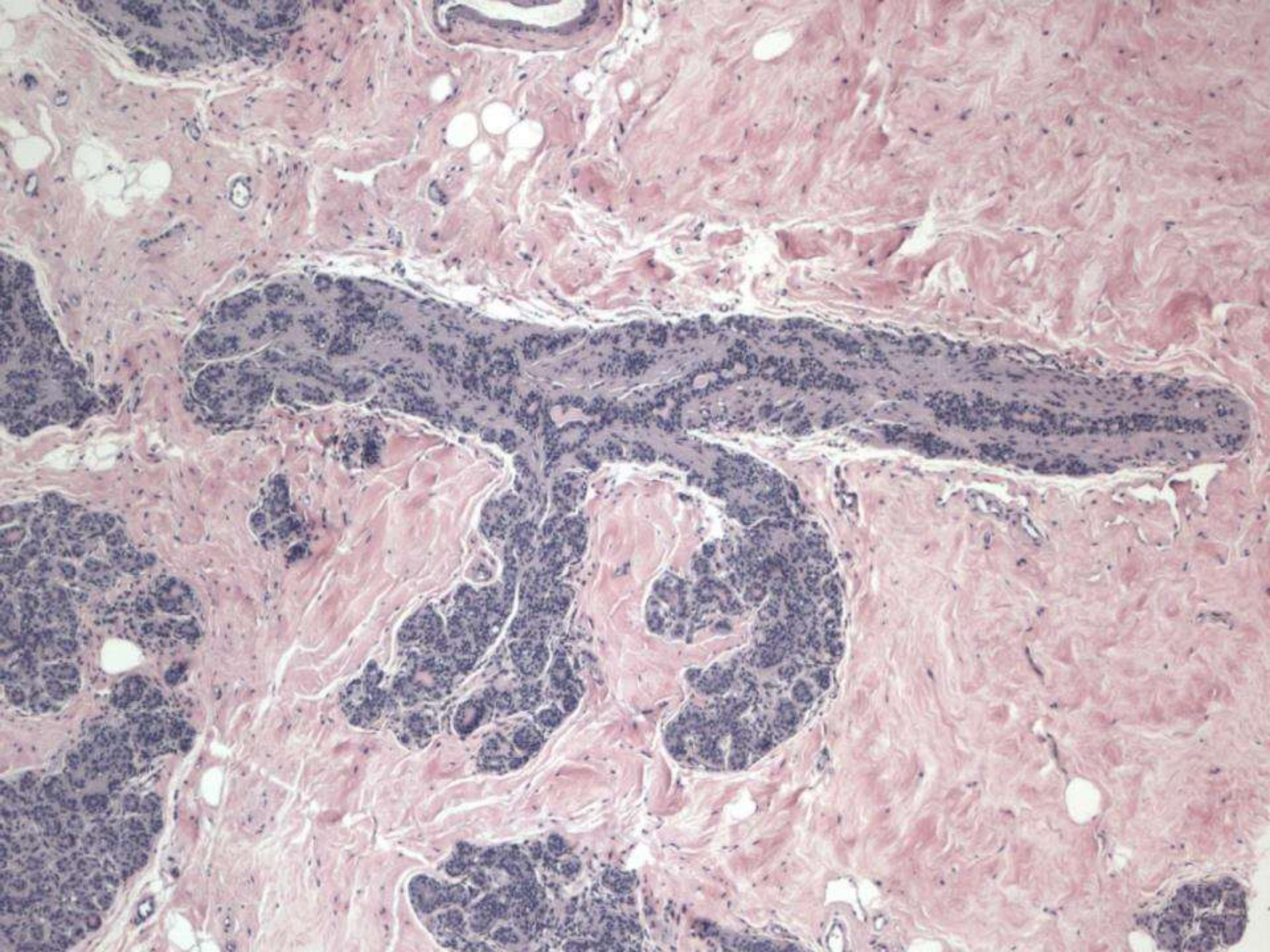
[Indexed for MEDLINE]

MET c.2962C>T p.R988C (48%)

Index case

Papillary Lesions IHC

	P63 and SMMHC	CK5 or CK5/6	ER
Papilloma with usual ductal hyperplasia	Staining within and around ducts	Staining within proliferative epithelium	Patchy to negative staining
Papilloma with ADH/ DCIS or papillary DCIS	Staining around ducts but reduced/absent staining within ducts	Negative within proliferative epithelium	Strong positive staining
EPC/SPC	Reduced/absent staining within and around the duct/lesion	Negative within proliferative epithelium	Strong positive staining
SPNRNP/BTRPTC	Reduced/absent staining within and around the duct/lesion	Staining within lesional epithelium	Patchy to negative staining



Ductal versus Lobular

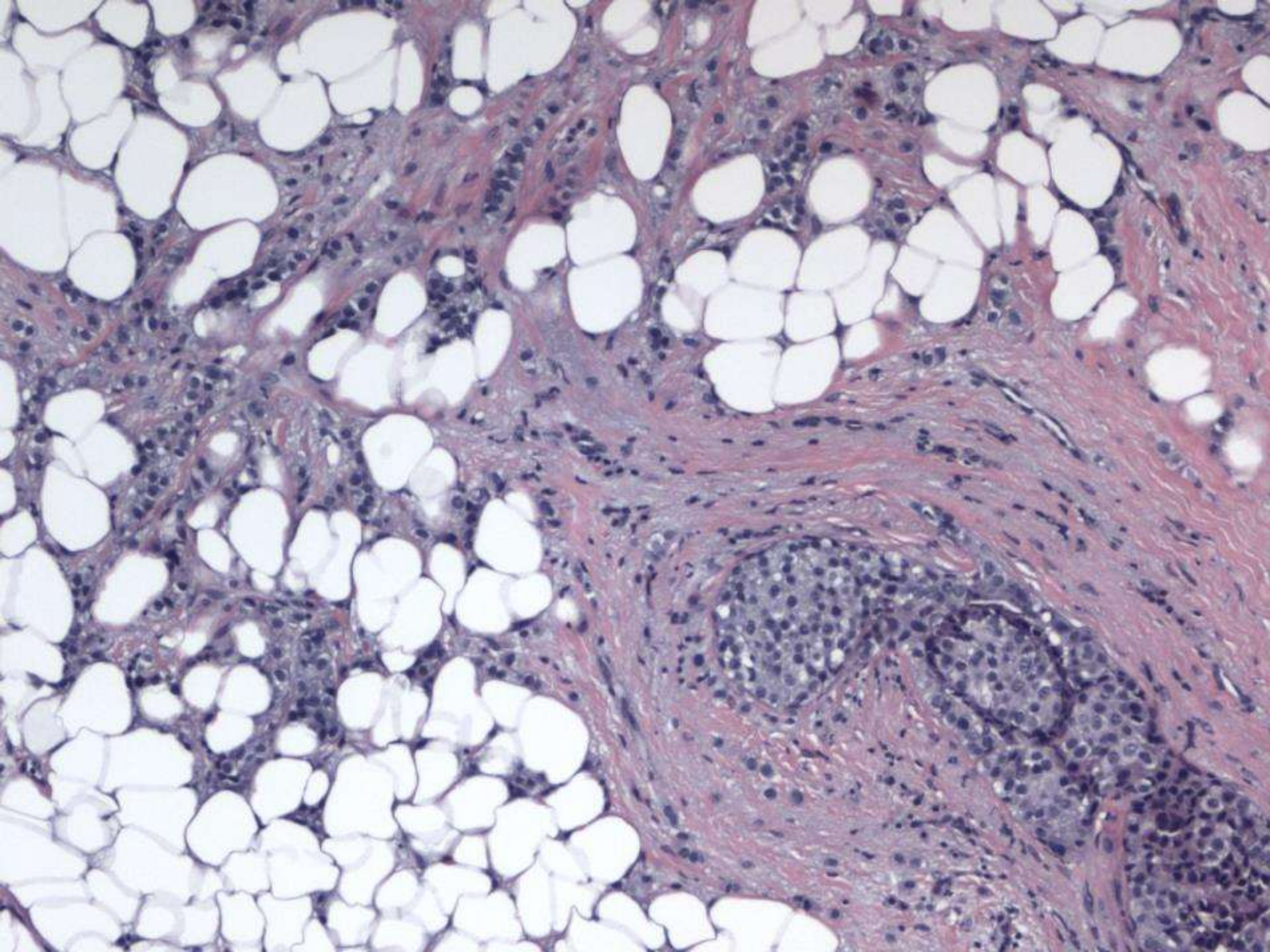
- Invasive ductal versus invasive lobular
 - No significant difference in disease free or overall survival
 - Why is it important?
 - Differences between DCIS and LCIS
 - DCIS is a precursor lesion while LCIS is a risk lesion
 - Differences between IDC and ILC
 - IDC is generally unifocal and ILC is not infrequently multifocal
 - Pattern of metastases are different
 - Differences in pre-operative evaluation and treatment

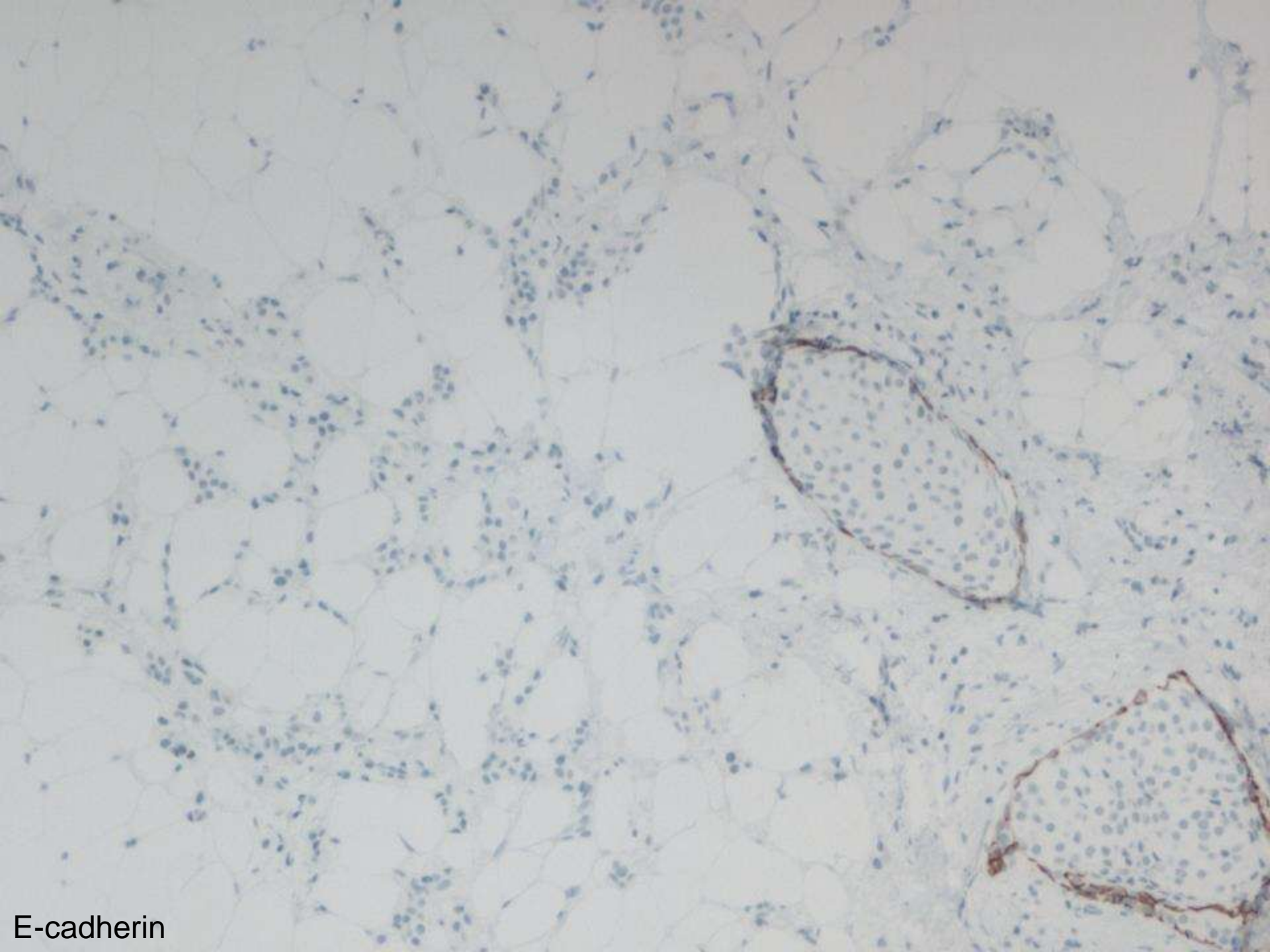
Ductal versus Lobular

- Arguments in favor of using E-cadherin for tumors with ambiguous morphology
 - We want to be correct
 - To avoid confusion in medical records
 - Only a subset of ductal carcinomas show complete response to neoadjuvant chemotherapy
 - Lobular carcinomas are more often multifocal and/or the microscopic extent is much greater than routine clinical or gross estimation
 - If health care cost containment is an issue, then MRI should be performed for lobular tumors only

Ductal versus Lobular

Lack of staining with E-cadherin is a
hallmark of lobular lesions

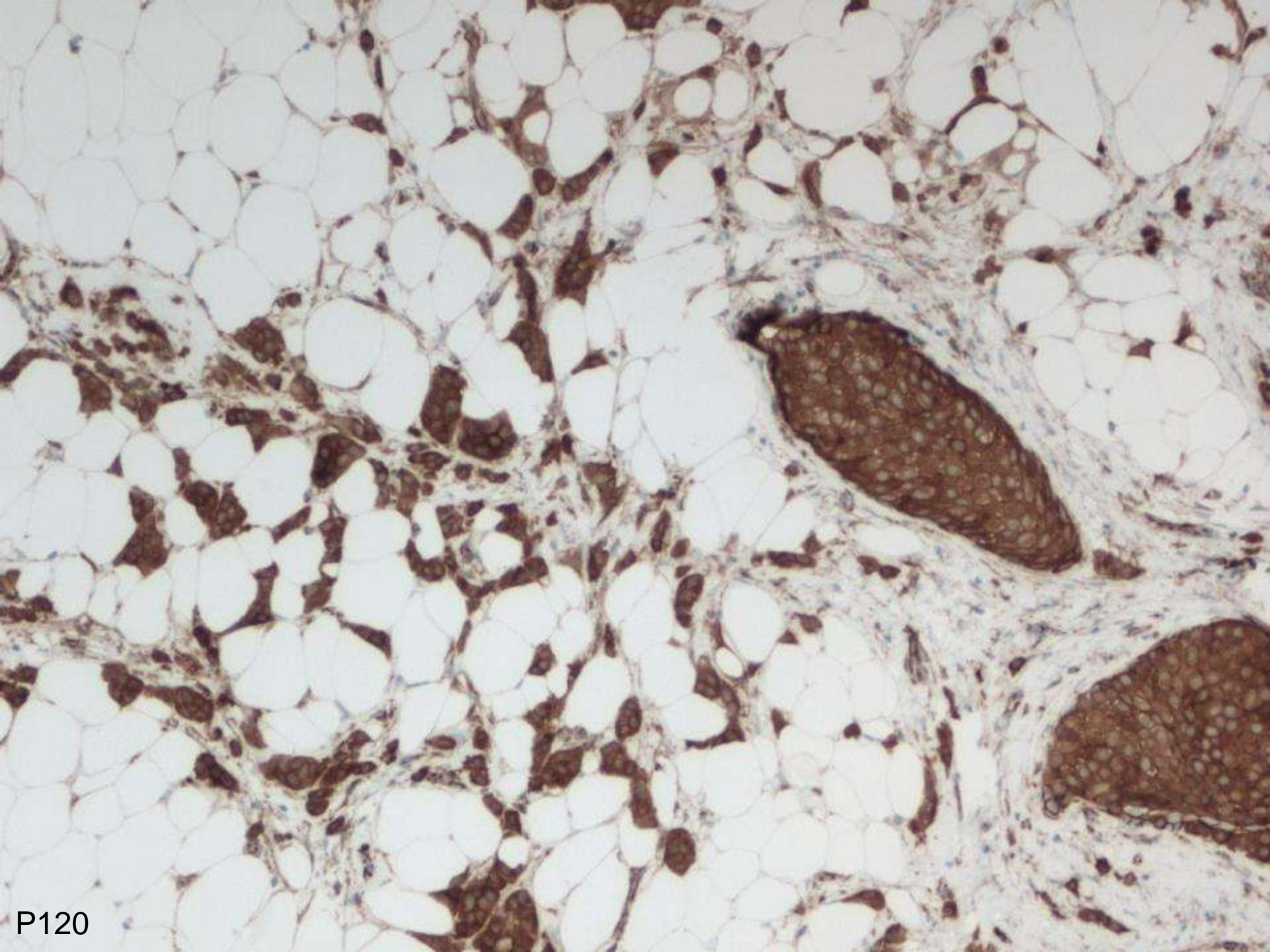




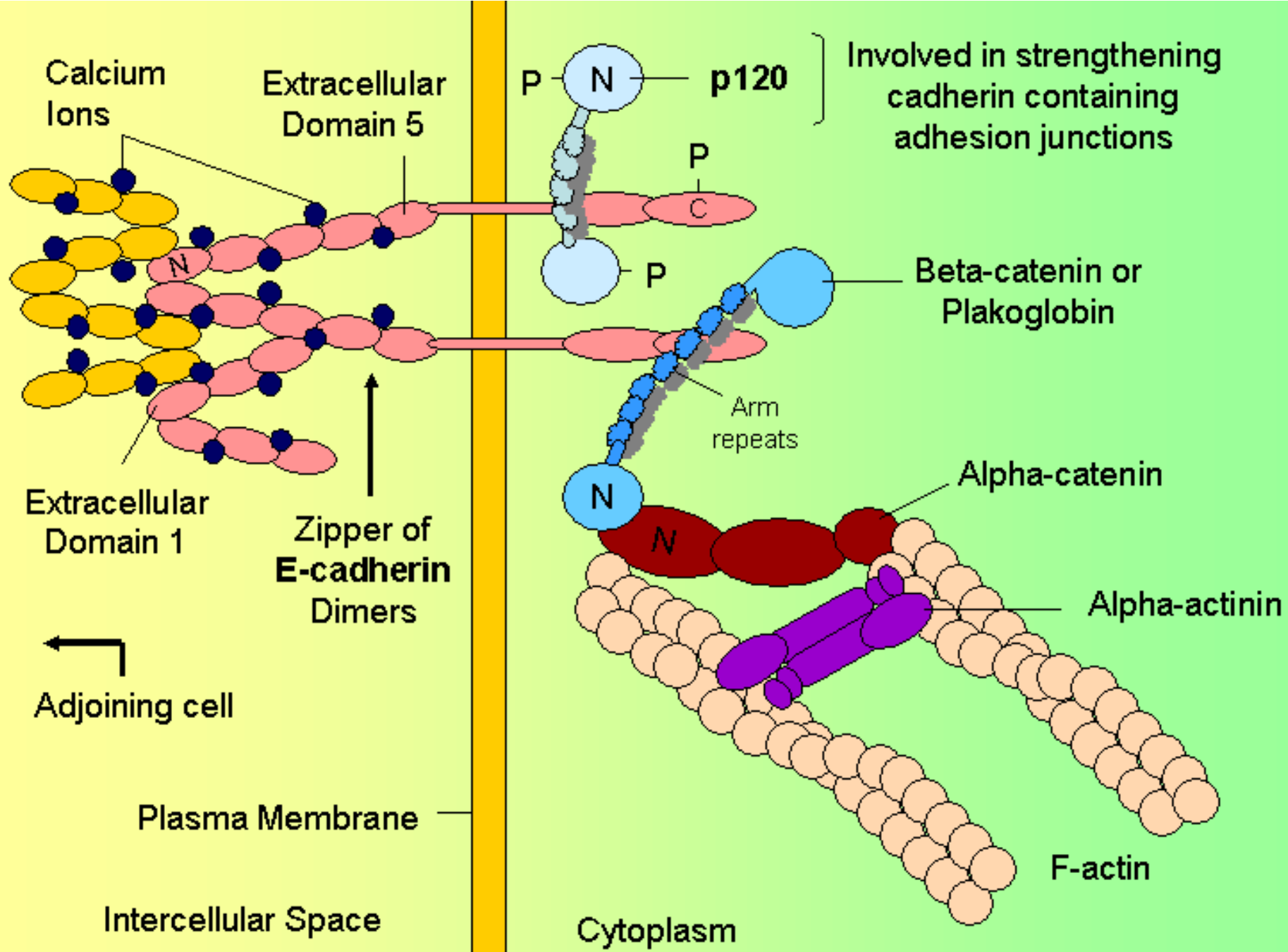
E-cadherin

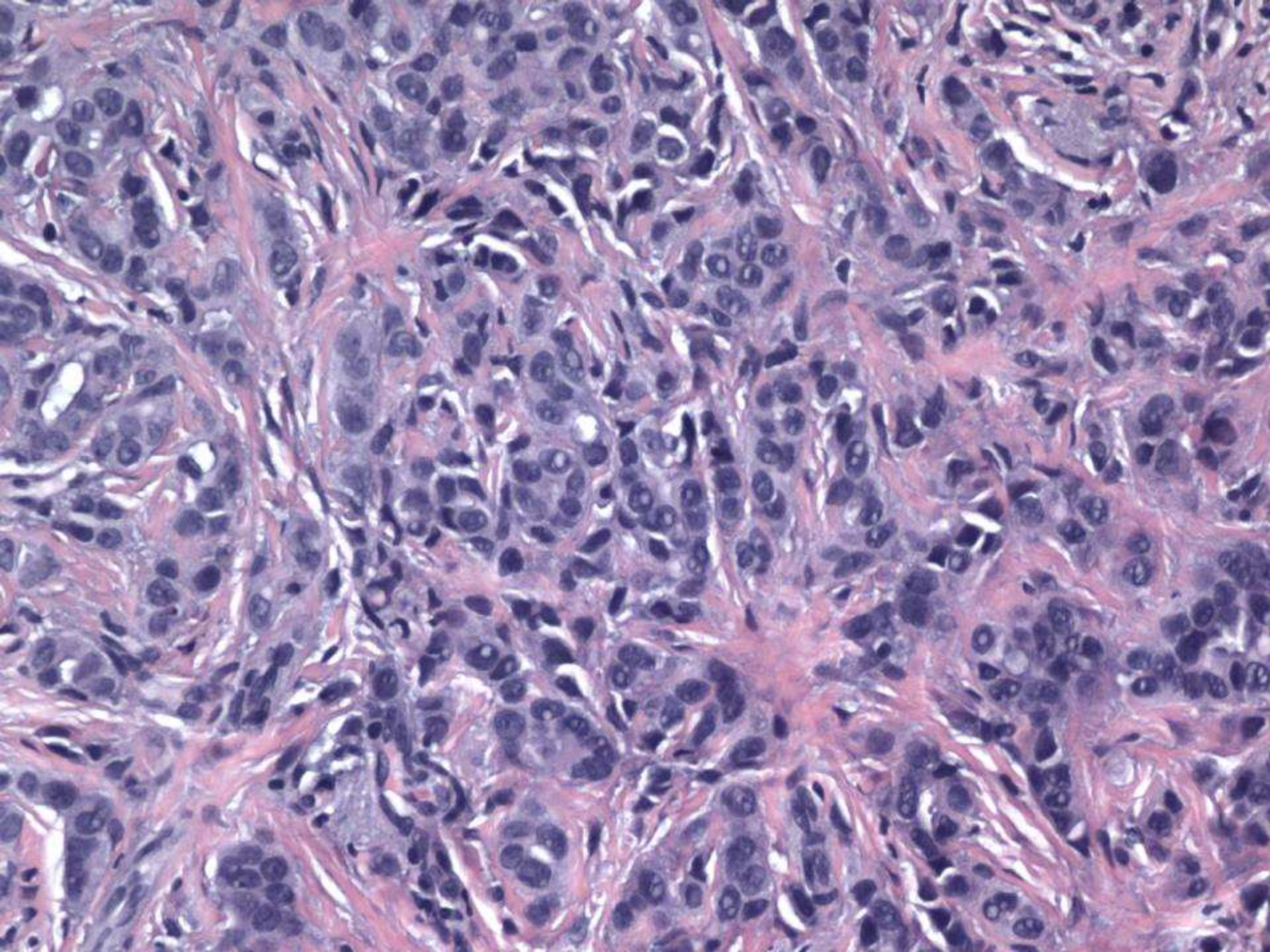
What do we do if E-cadherin staining is equivocal, aberrant, or difficult to interpret?

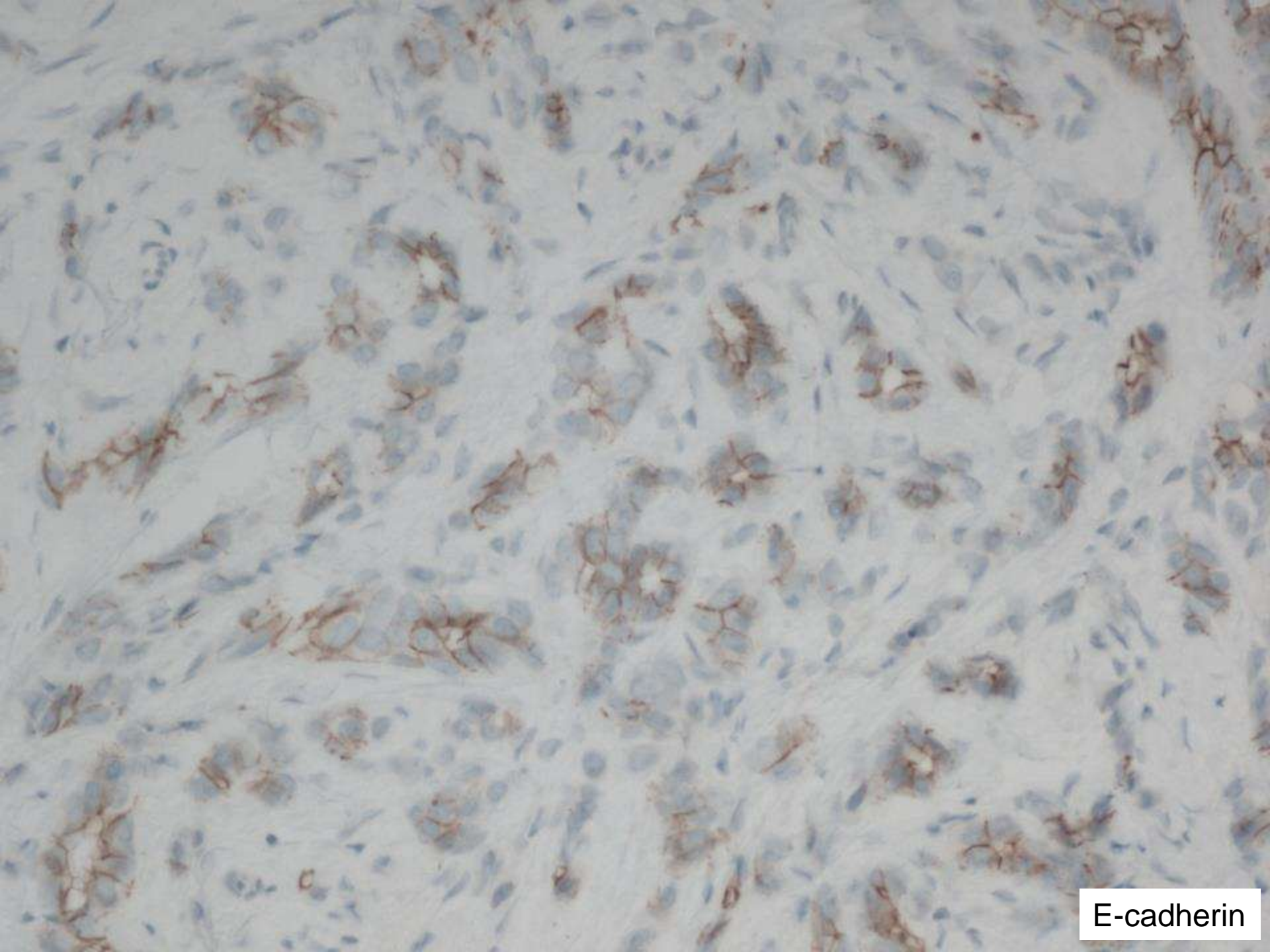
p120



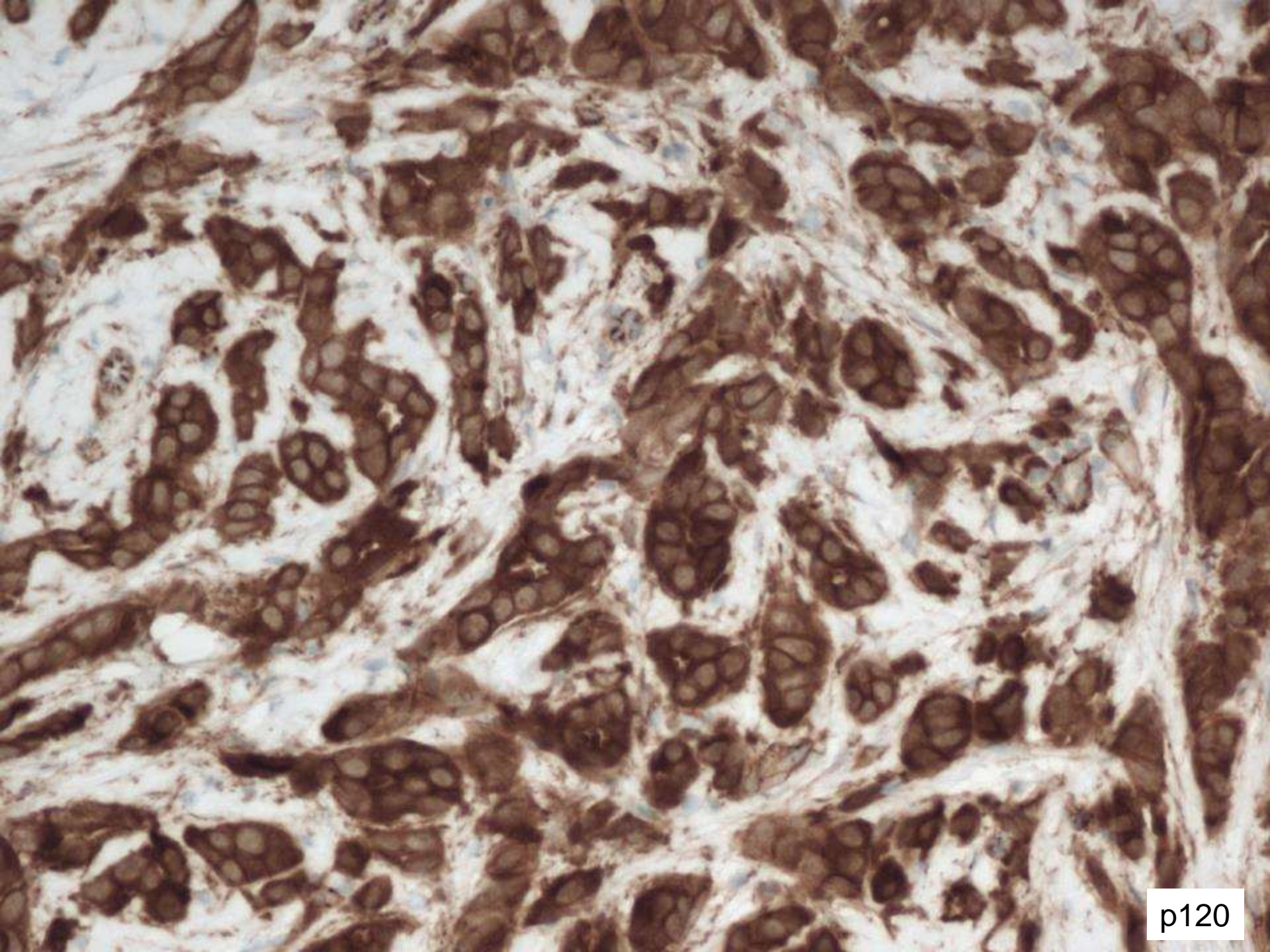
P120

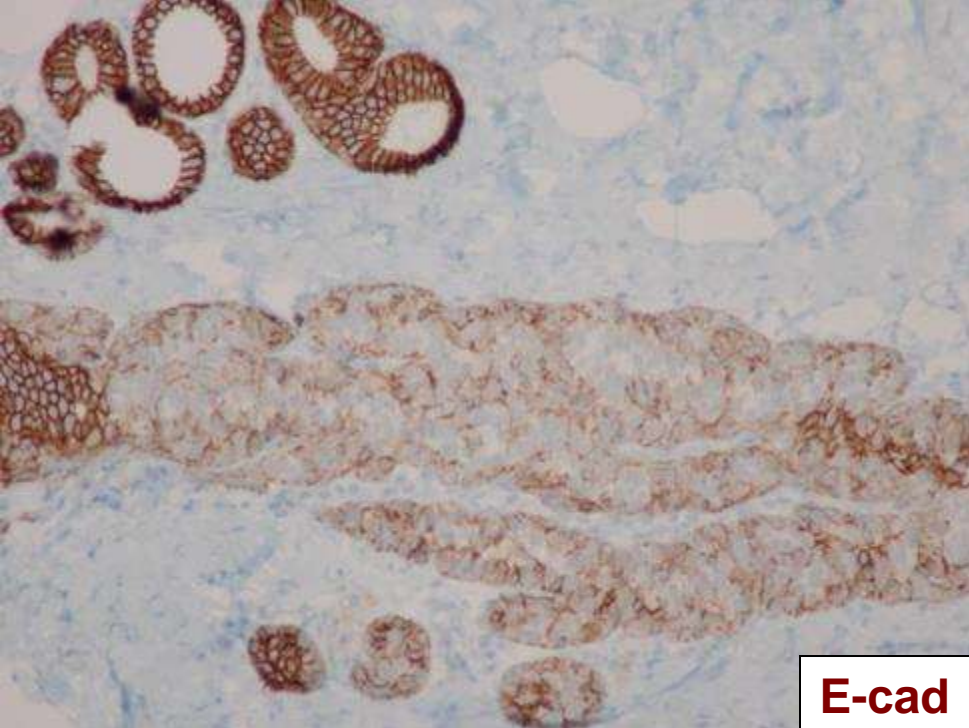



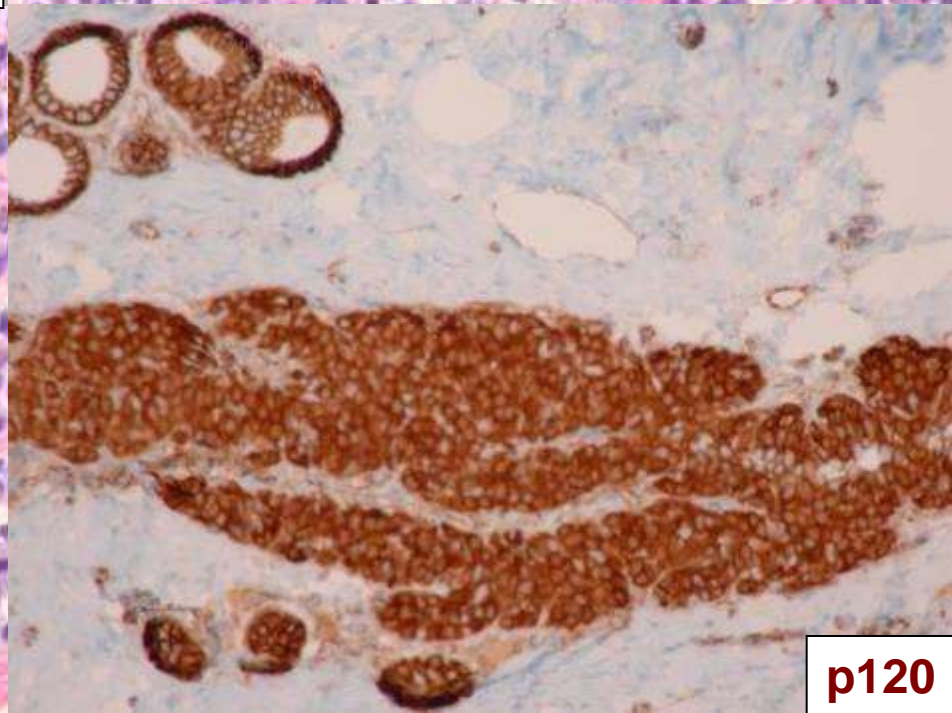
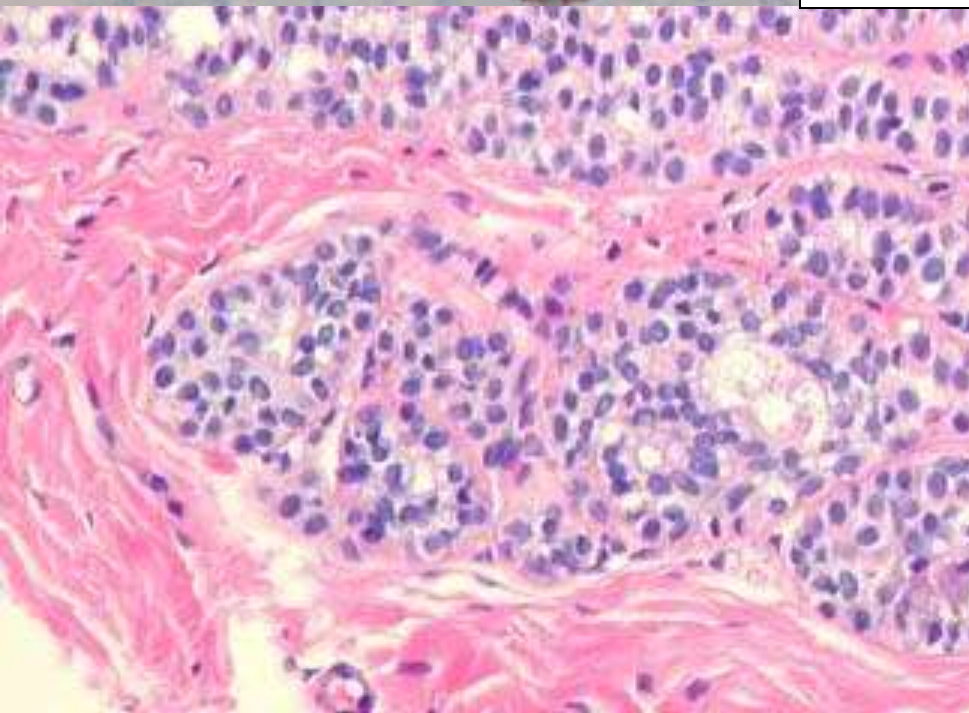
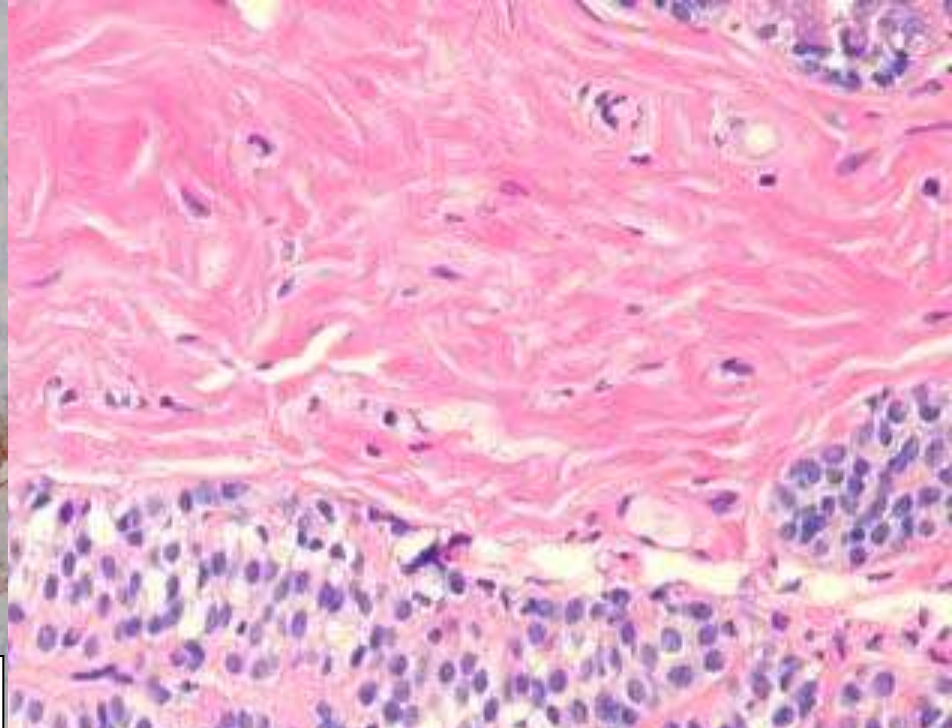


E-cadherin

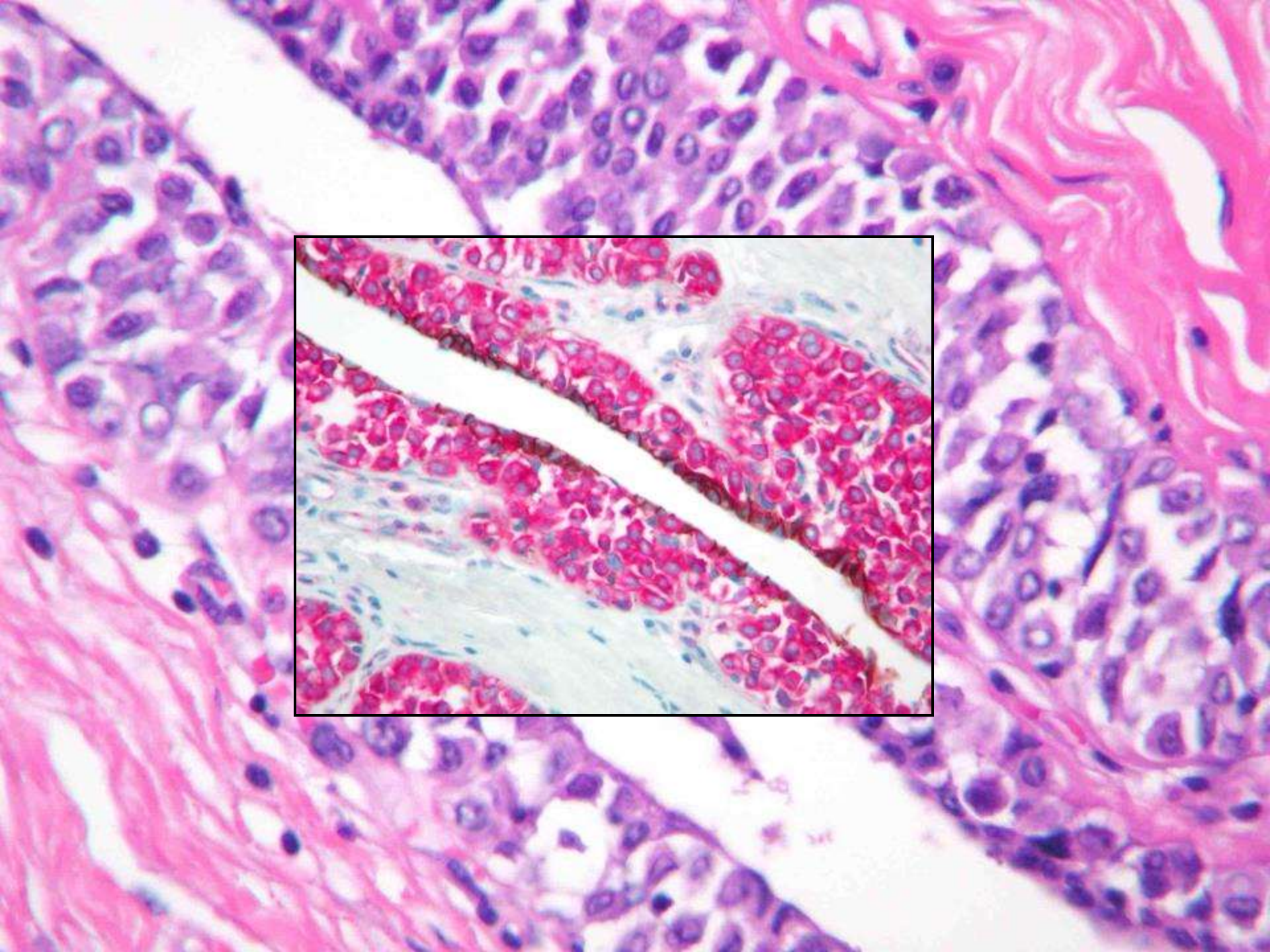




E-cad

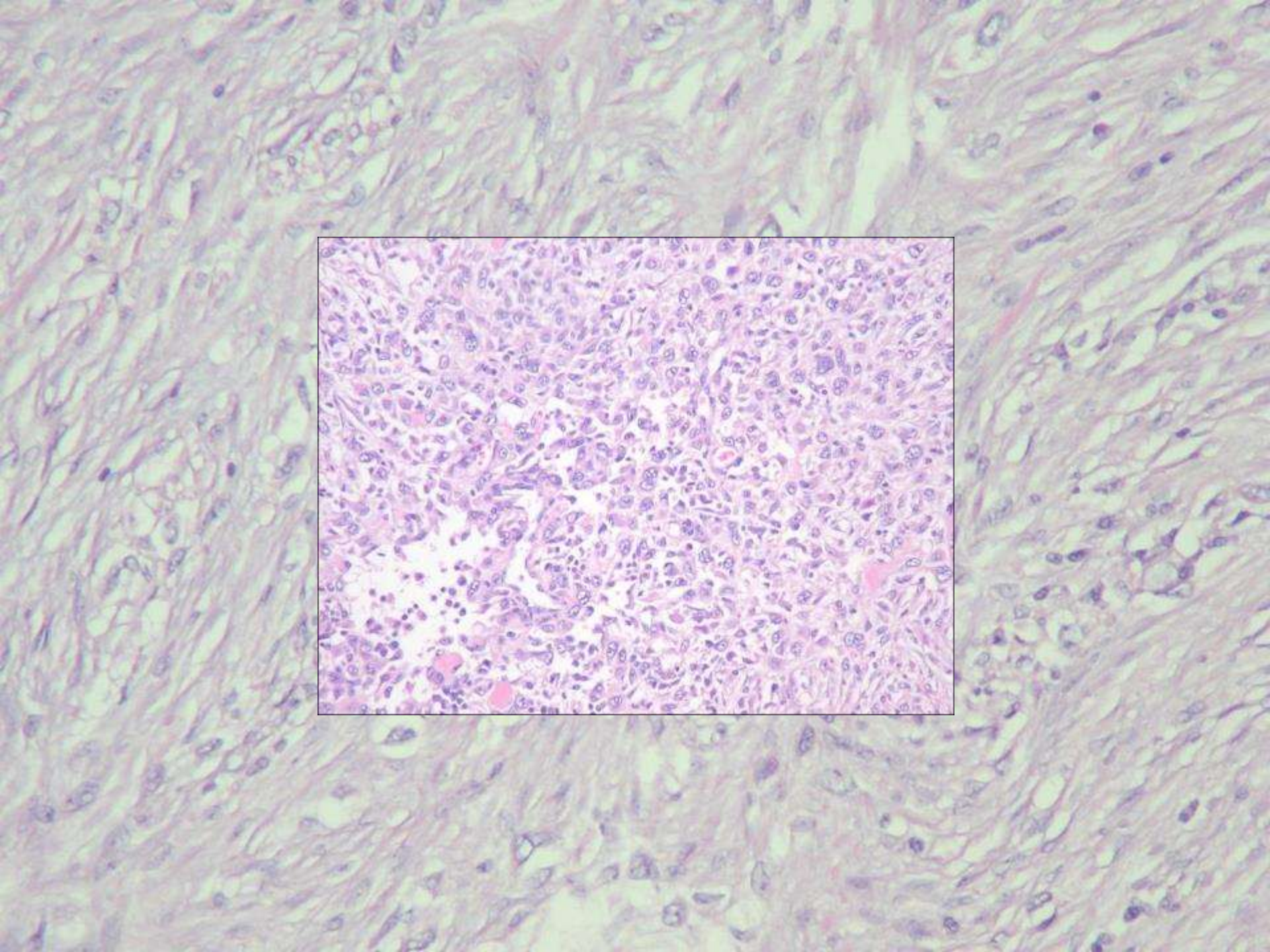


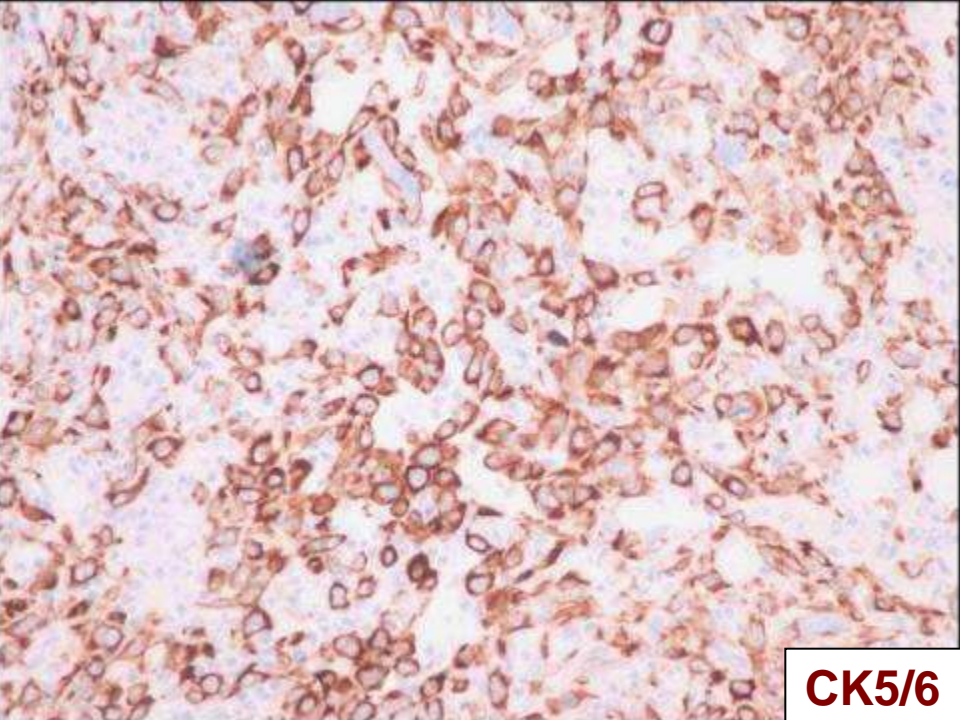
p120



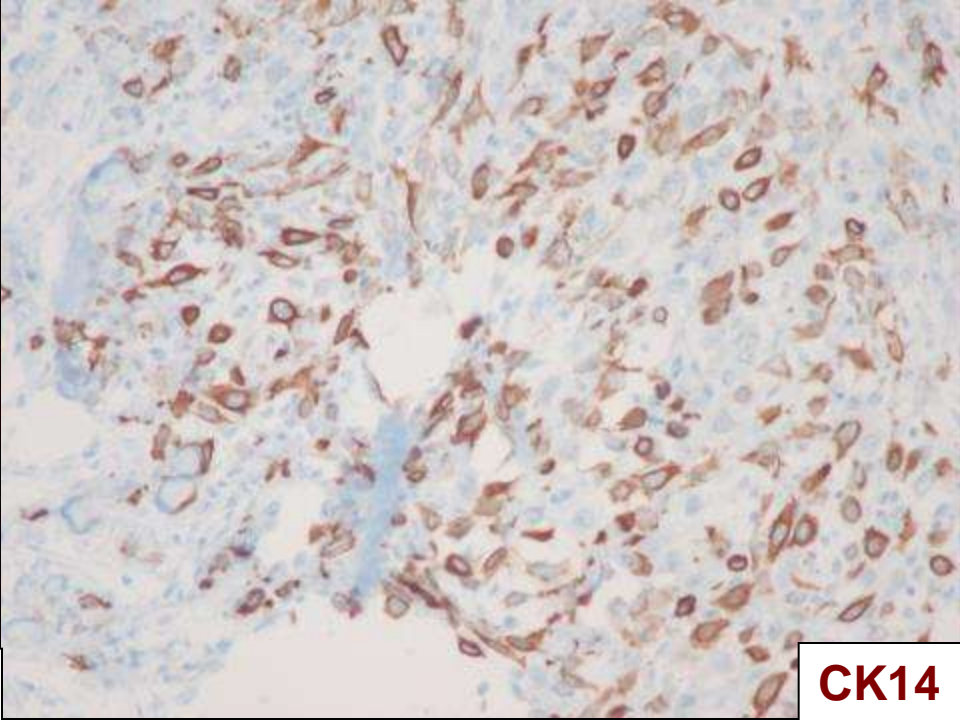
Spindle Cell Lesions and Metaplastic Carcinoma

- Metaplastic carcinomas are heterogeneous
 - Squamous, adenosquamous, chondroid or osseous differentiation
- Diagnostically problematic cases are the ones which show predominant spindle cell morphology
 - IHC is used mainly to prove epithelial nature of the lesion and exclude a sarcoma or melanoma

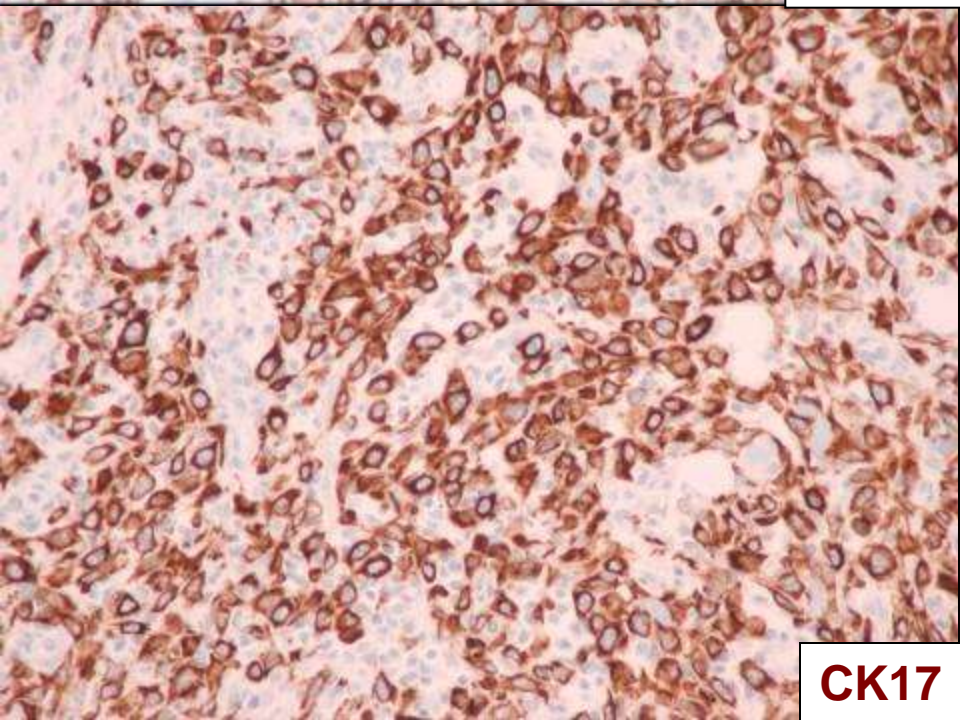




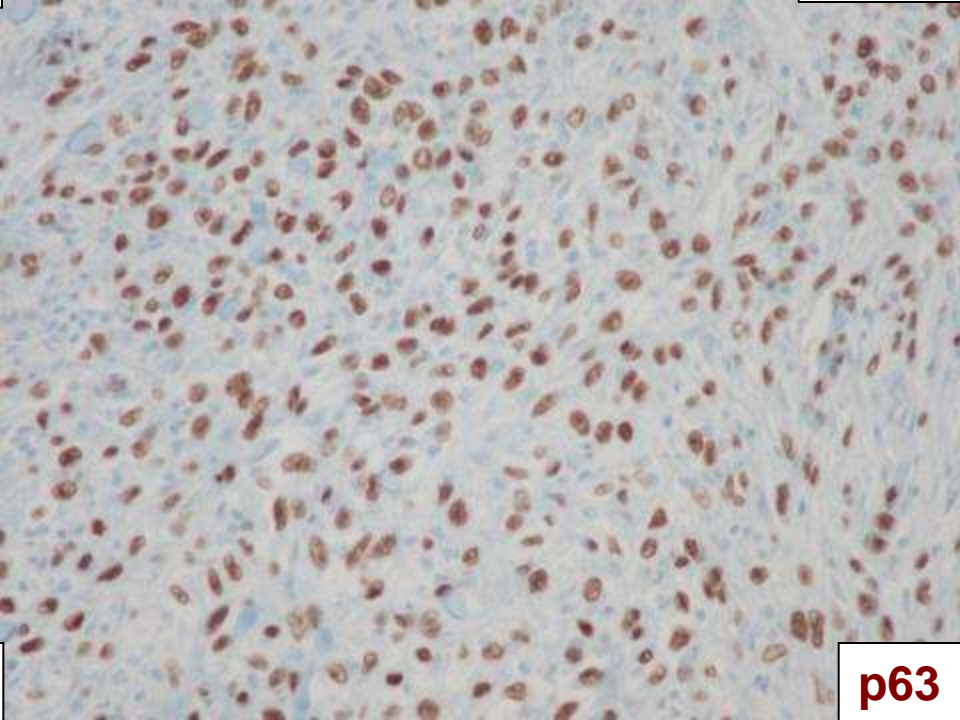
CK5/6



CK14

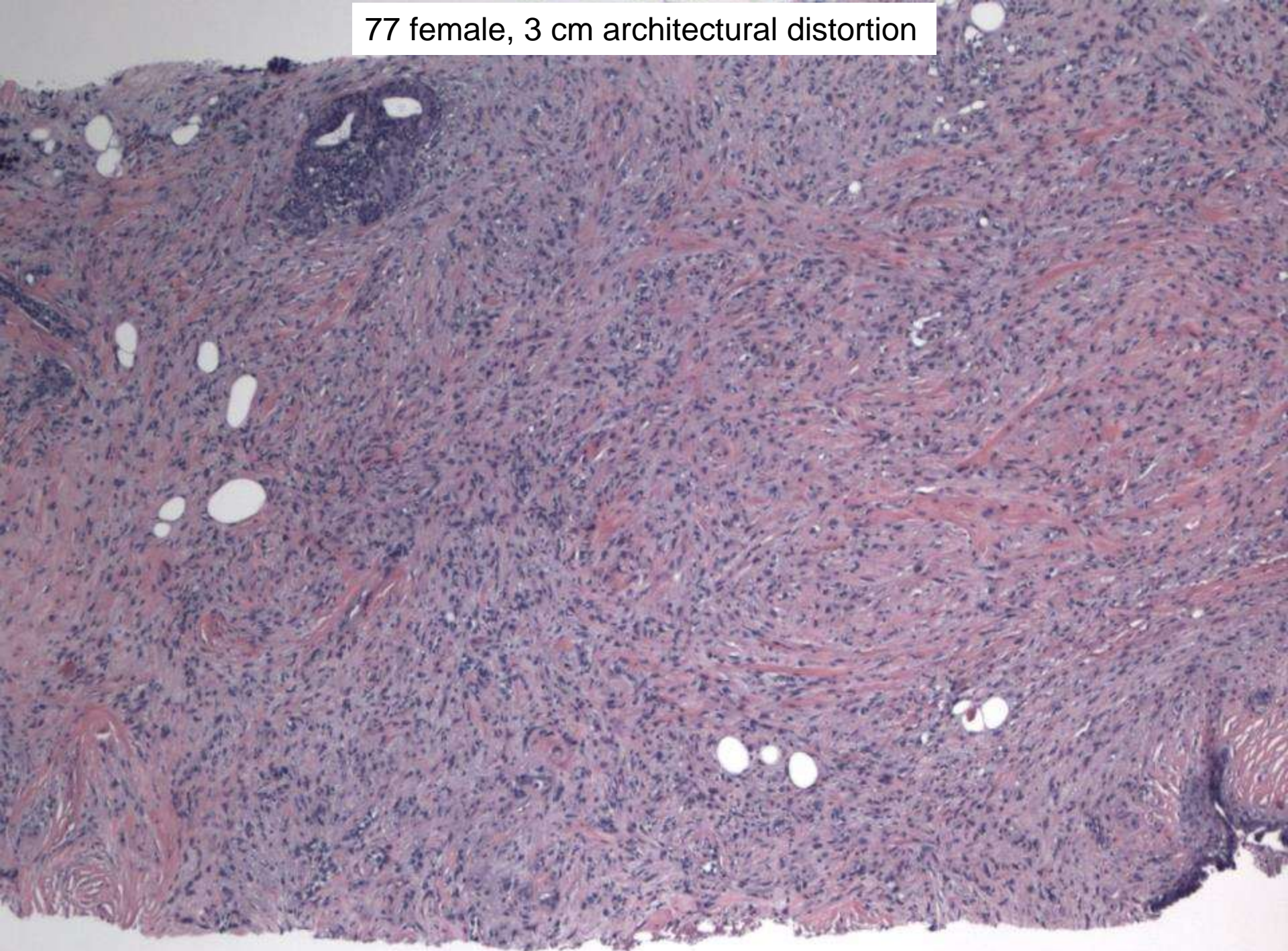


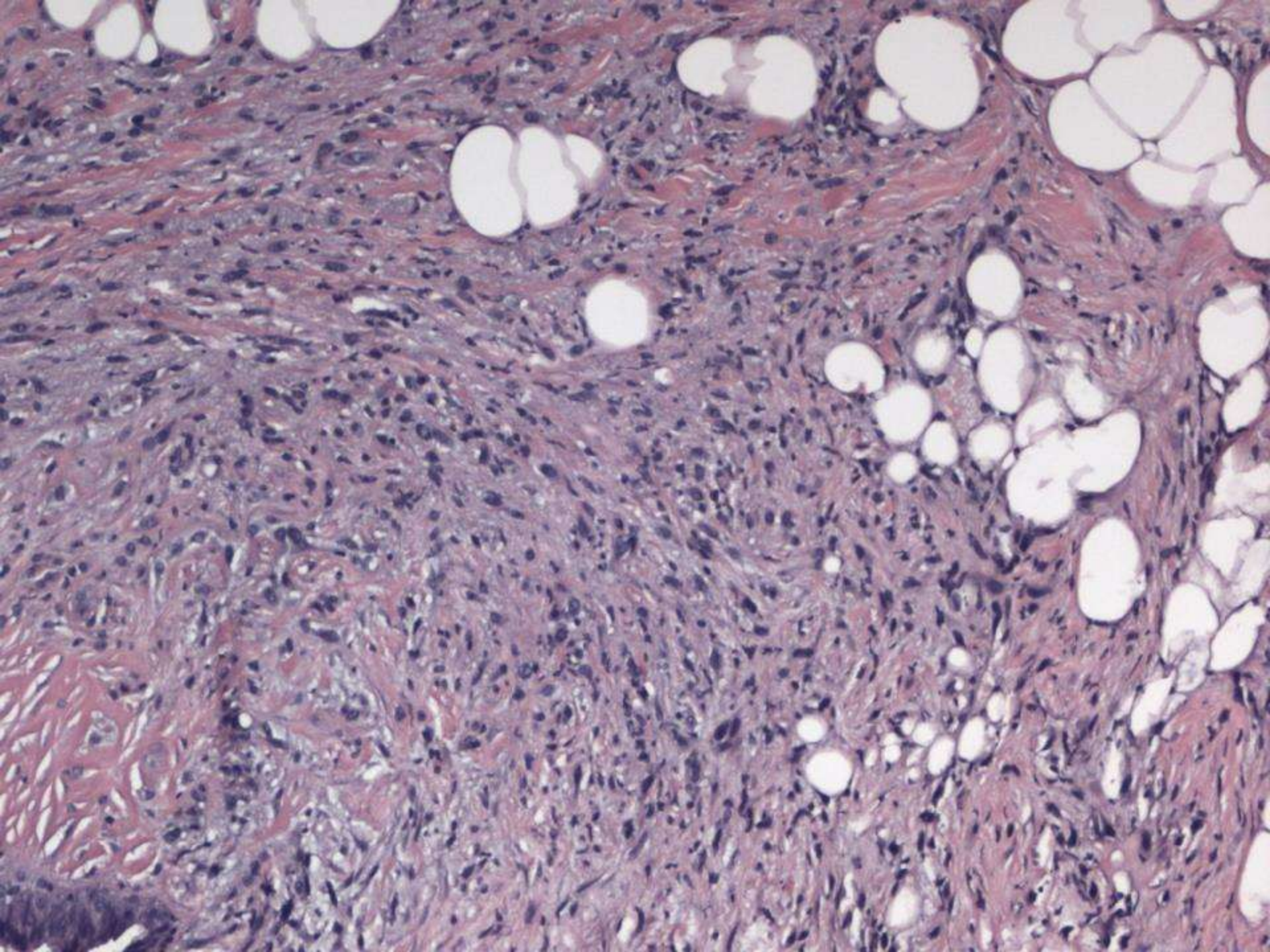
CK17

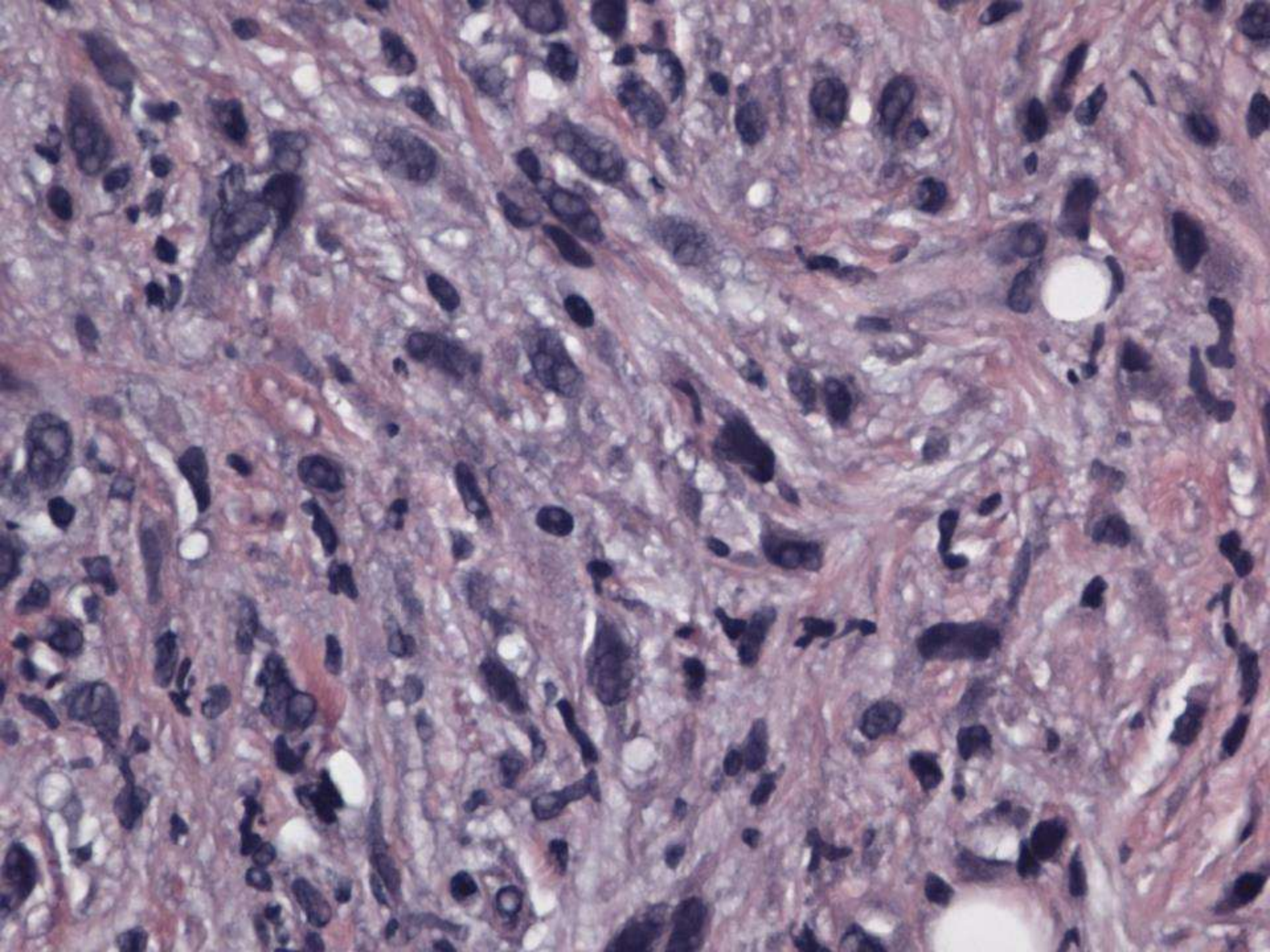


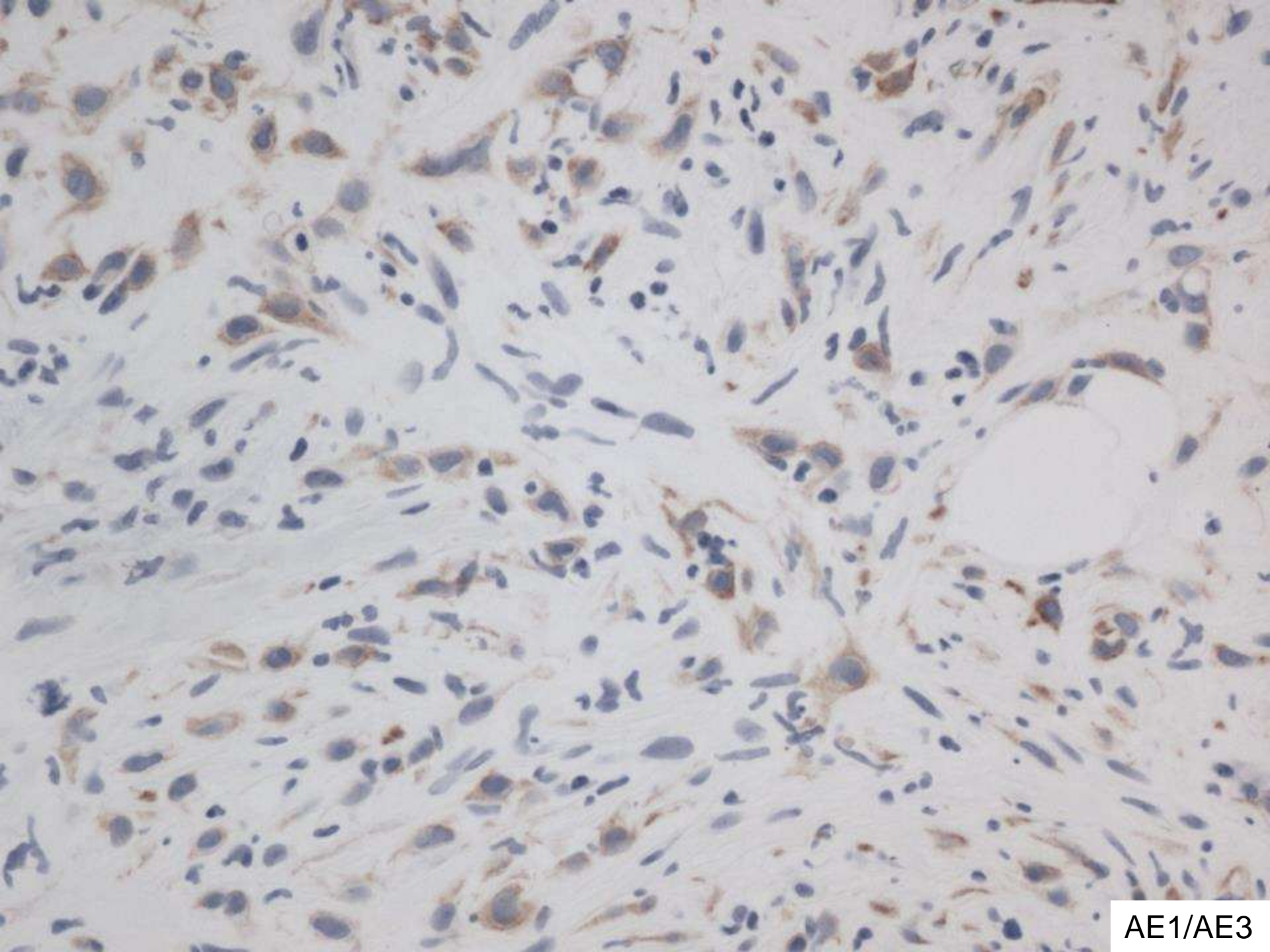
p63

77 female, 3 cm architectural distortion

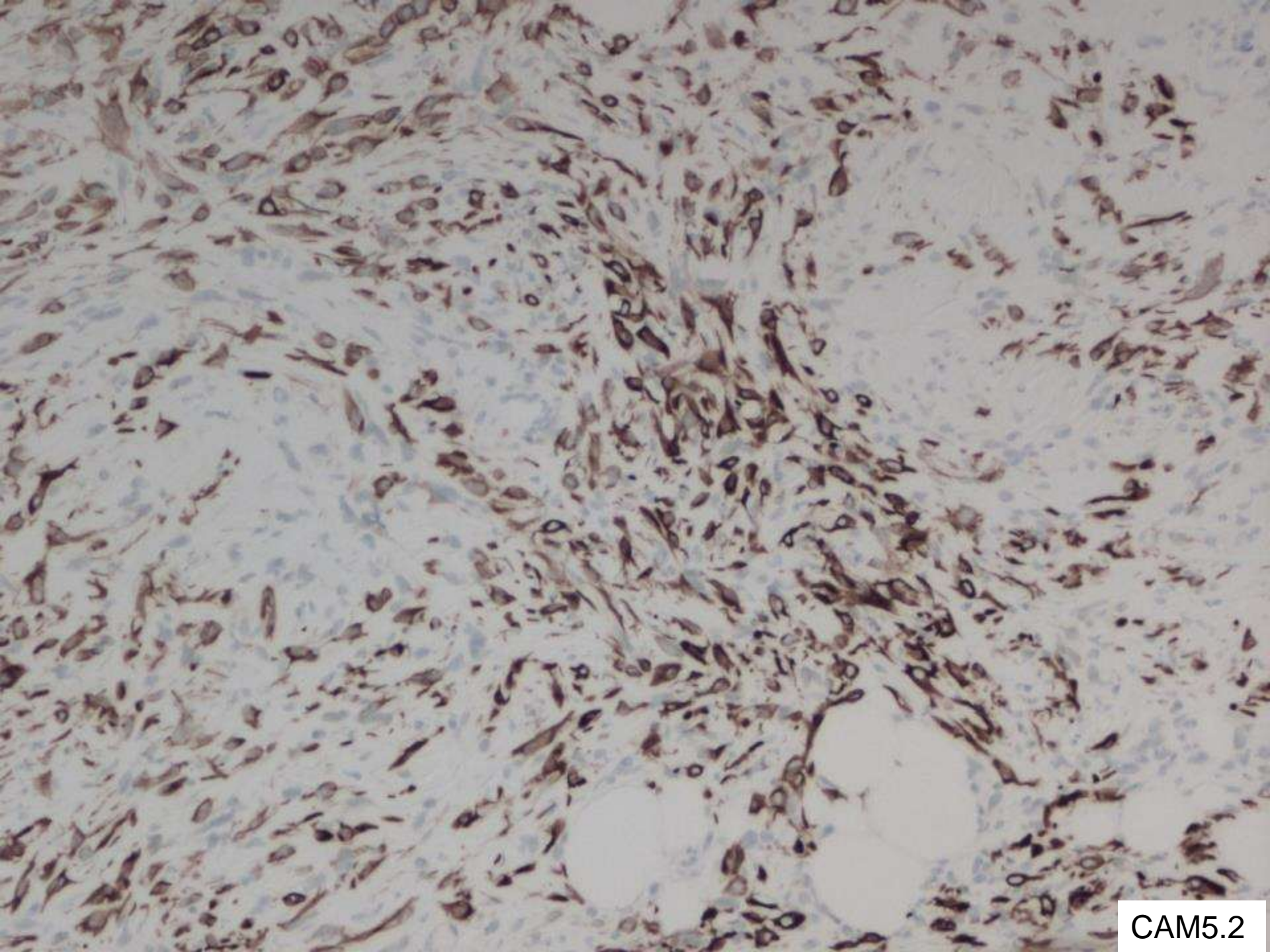






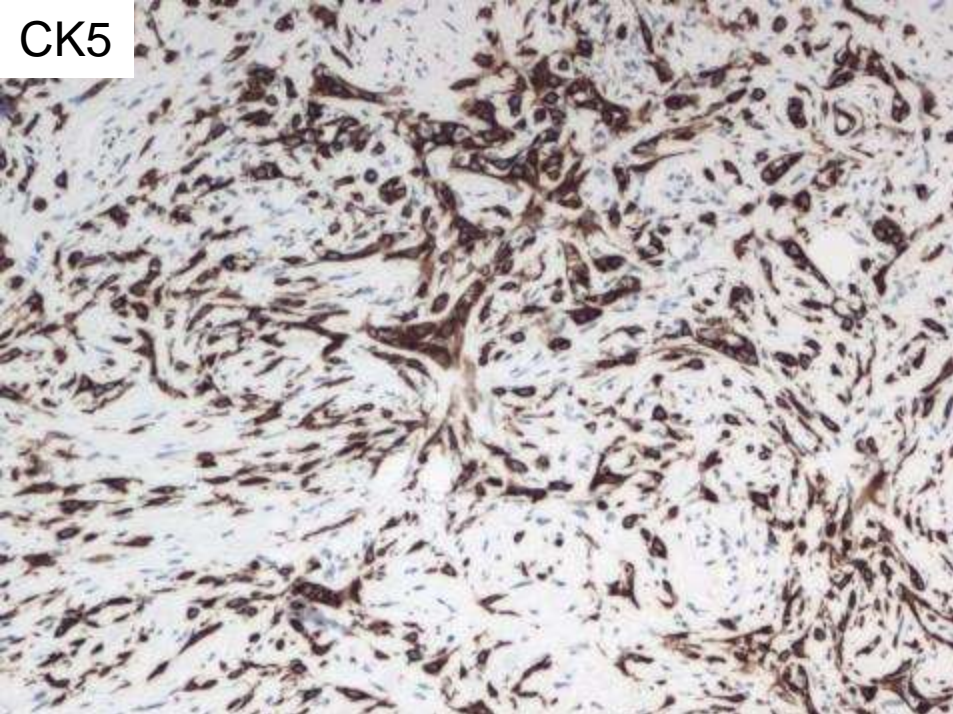


AE1/AE3

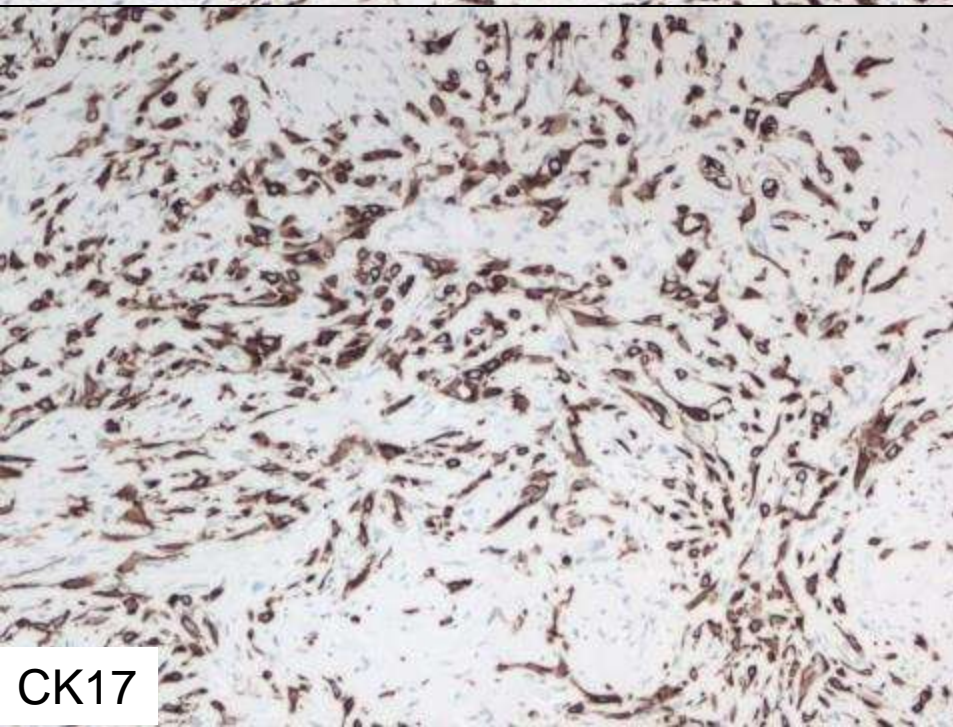
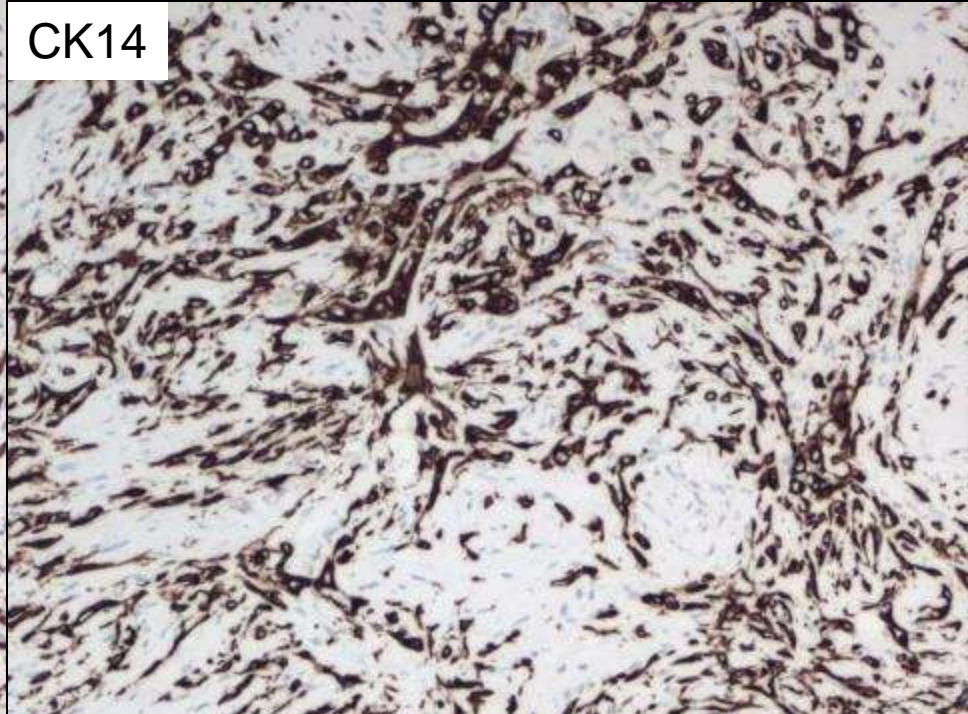


CAM5.2

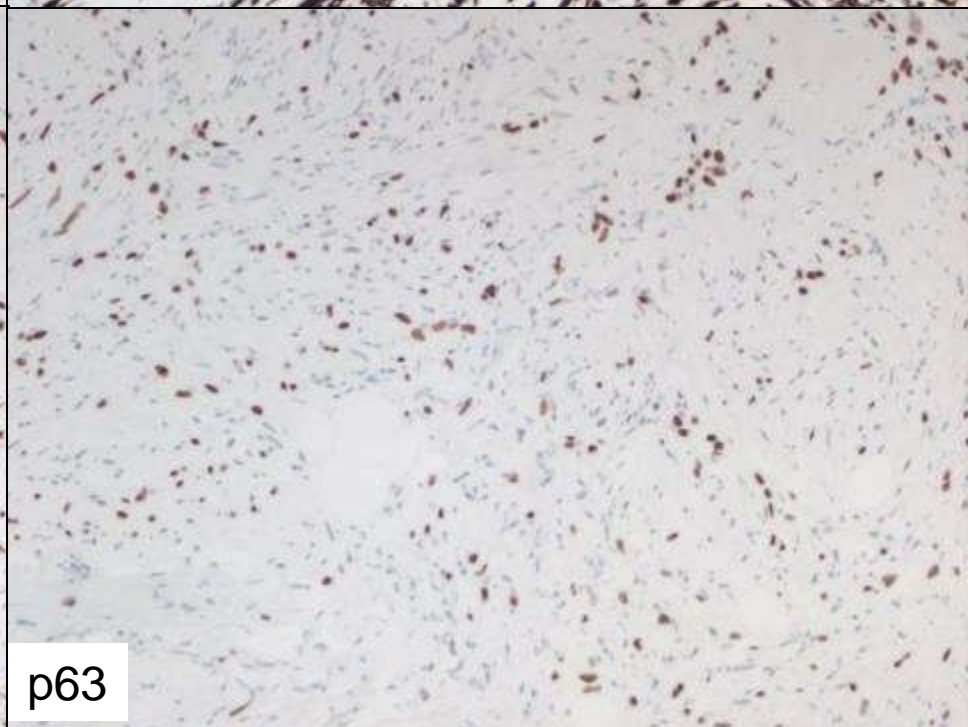
CK5



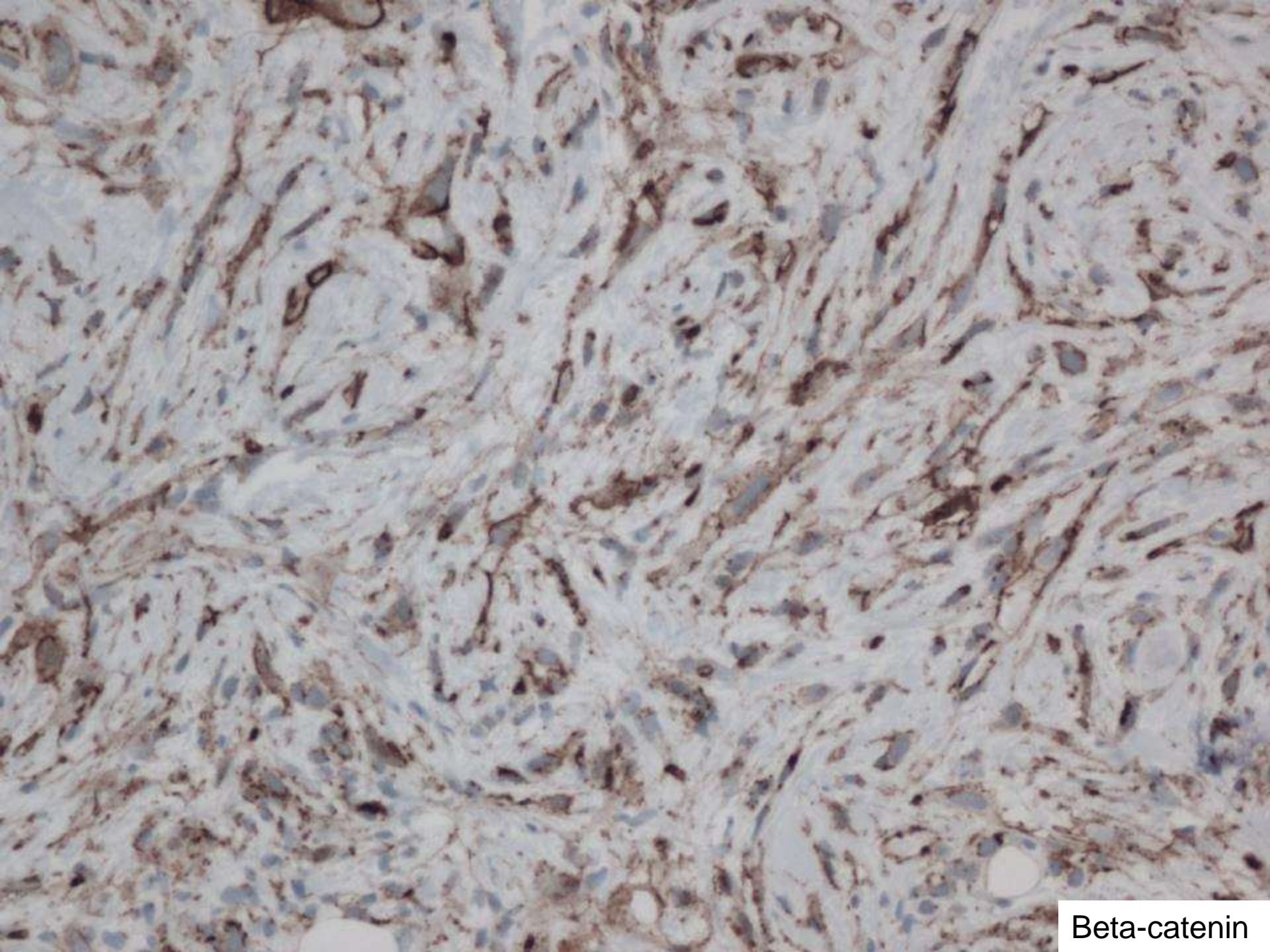
CK14



CK17



p63



Beta-catenin

IHC

POSITIVE STAINS

- CK5
- CK14
- CK17
- P63
- AE1/AE3 (very weak and focal)
- CAM 5.2

NEGATIVE STAINS

- Beta-catenin
- Actin
- Desmin
- CD34
- ER
- PR
- HER2
- EMA

Diagnosis: Spindle cell metaplastic carcinoma

Metaplastic Carcinoma

- Stains to rule in spindle cell metaplastic carcinoma
 - AE1/3
 - CAM5.2
 - EMA
 - 34betaE12
 - p63
 - Basal-type cytokeratins
 - CK5/6 or CK5 (better than CK5/6)
 - CK14
 - CK17

p63 and CK5 are 2 most helpful positive stains in spindle cell metaplastic carcinoma

Metaplastic Carcinoma

- Stains to rule out metaplastic carcinoma
 - S100
 - HMB-45
 - Melan A
 - CD31
 - CD34
 - Factor VIII

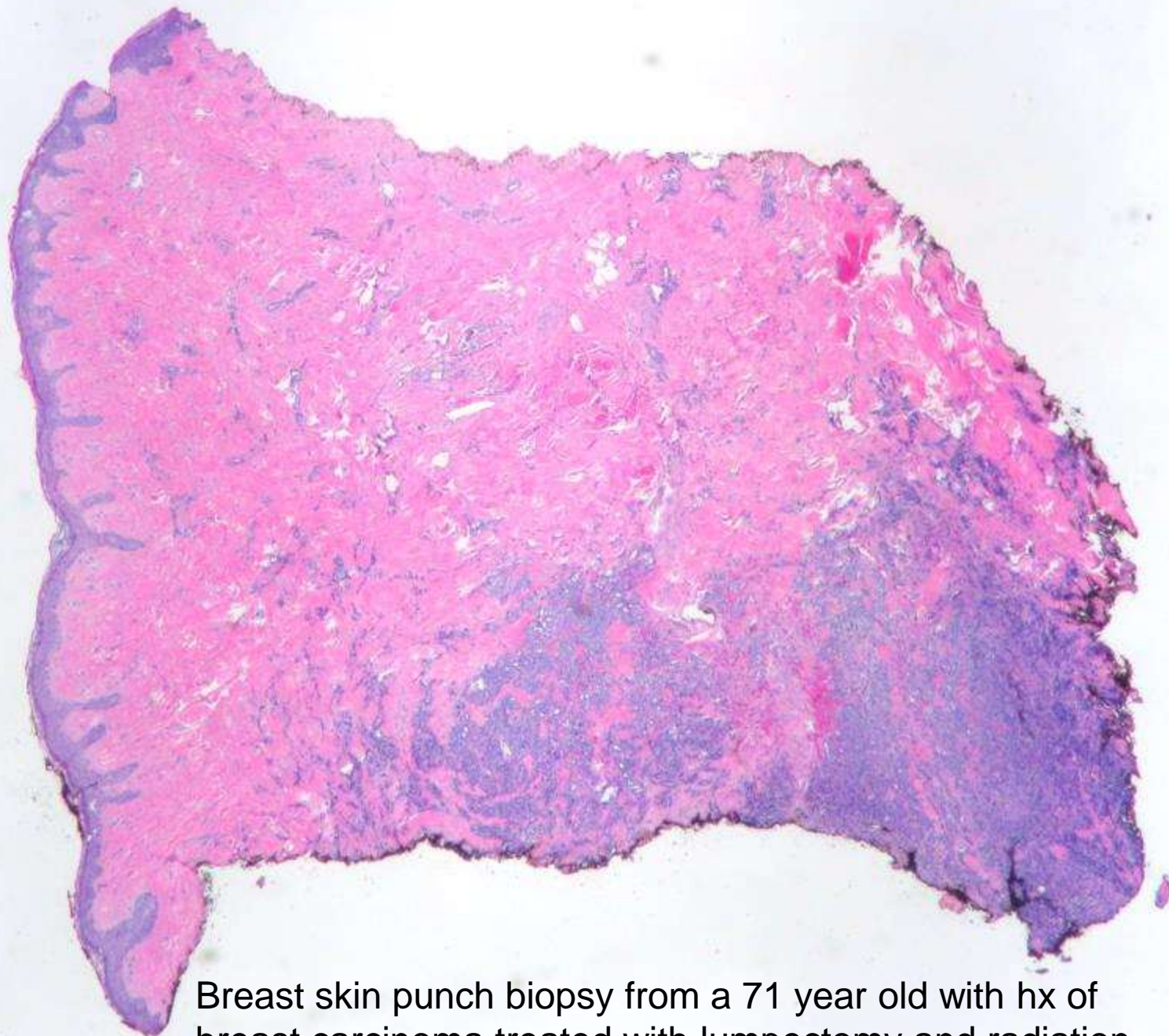Other Spindle Cell Lesions

- Stroma of phyllodes tumor (CD34+ in ~50%)
- Angiosarcoma (CD31 and CD34+)
- Melanoma (S100, HMB45 and Melan A+)

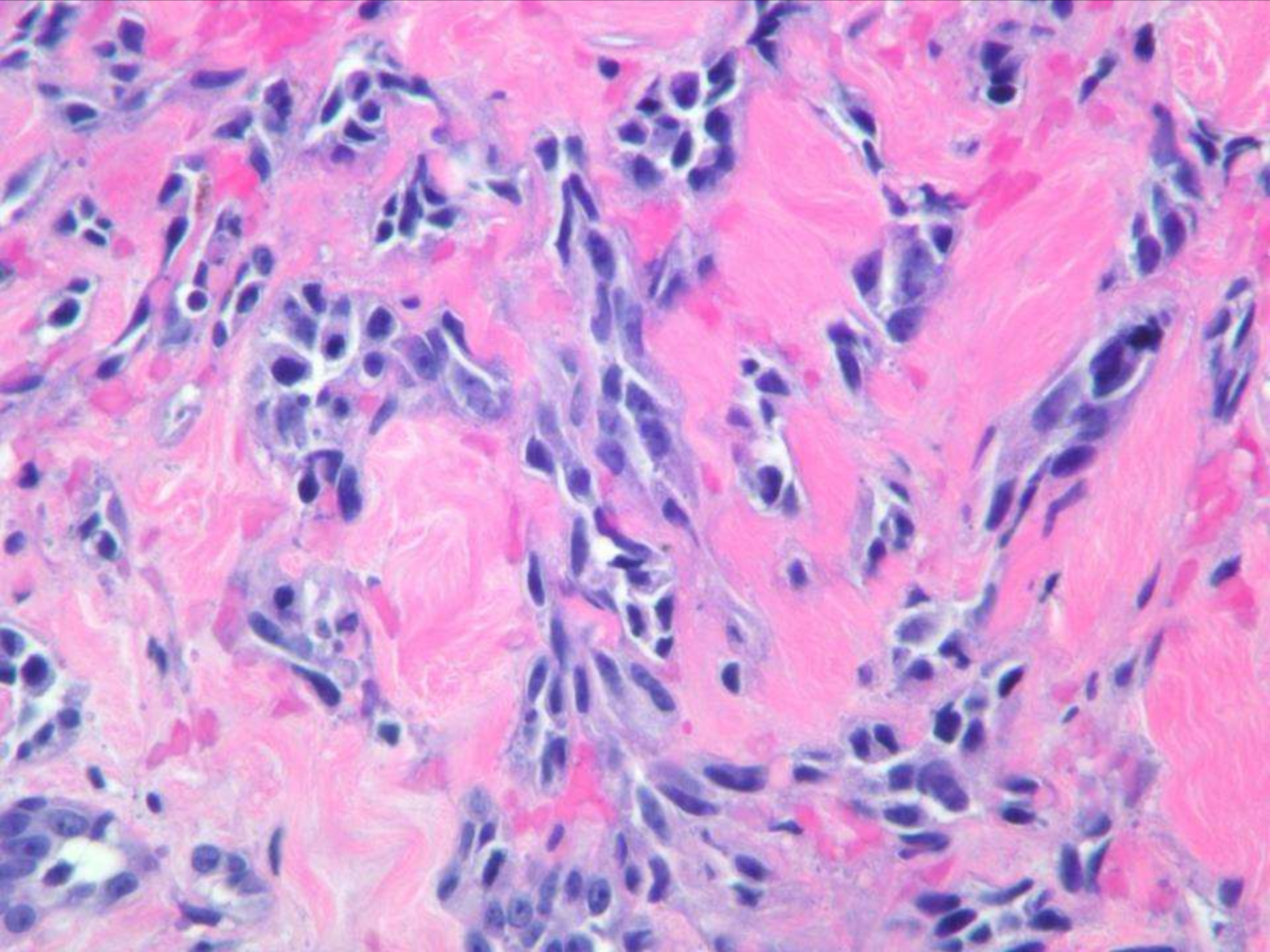
Spindle cells with cytologic atypia

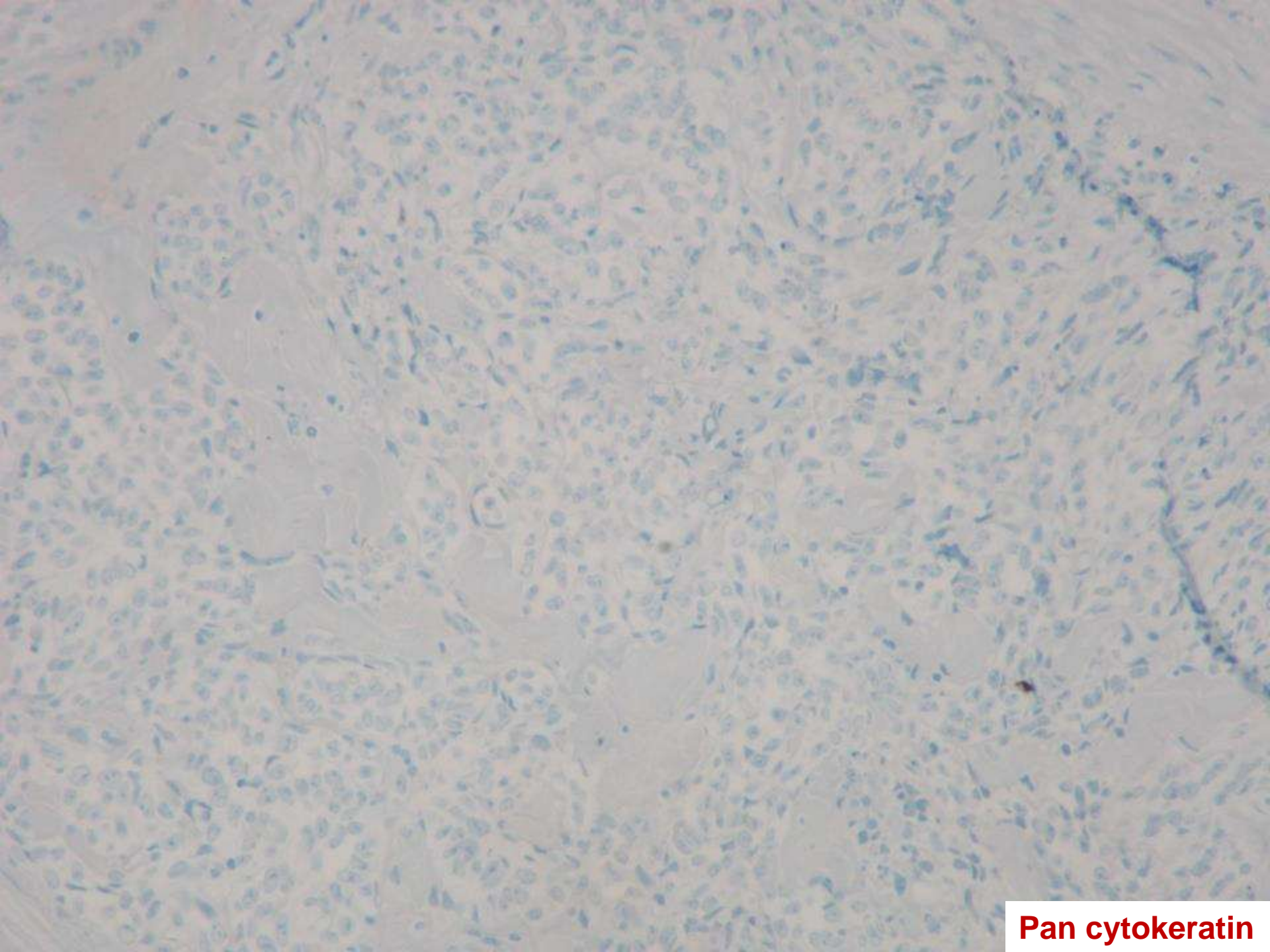
Bland spindle cells

- Fibromatosis (CD34 neg, nuclear β -catenin+)
- Myofibroblastoma (CD34+, ER+)
- Cellular PASH (CD34+)

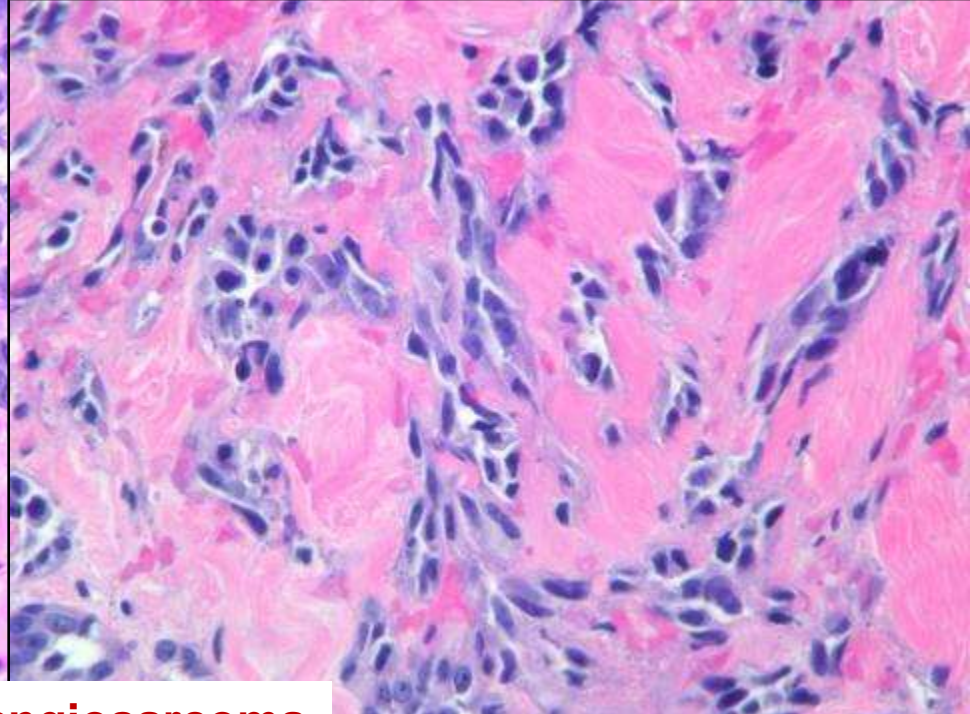
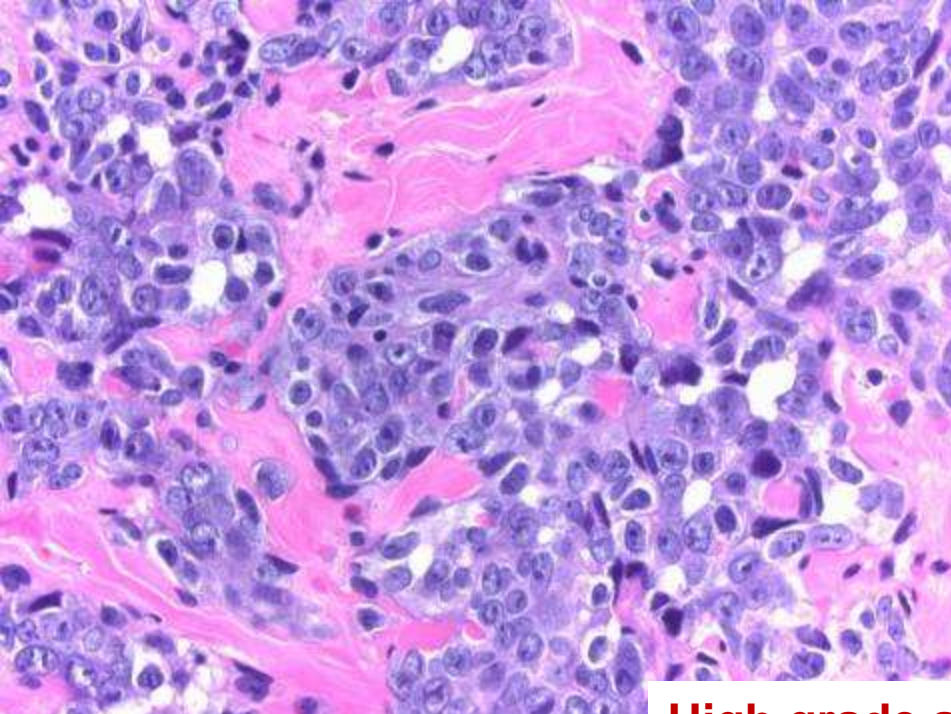


Breast skin punch biopsy from a 71 year old with hx of breast carcinoma treated with lumpectomy and radiation

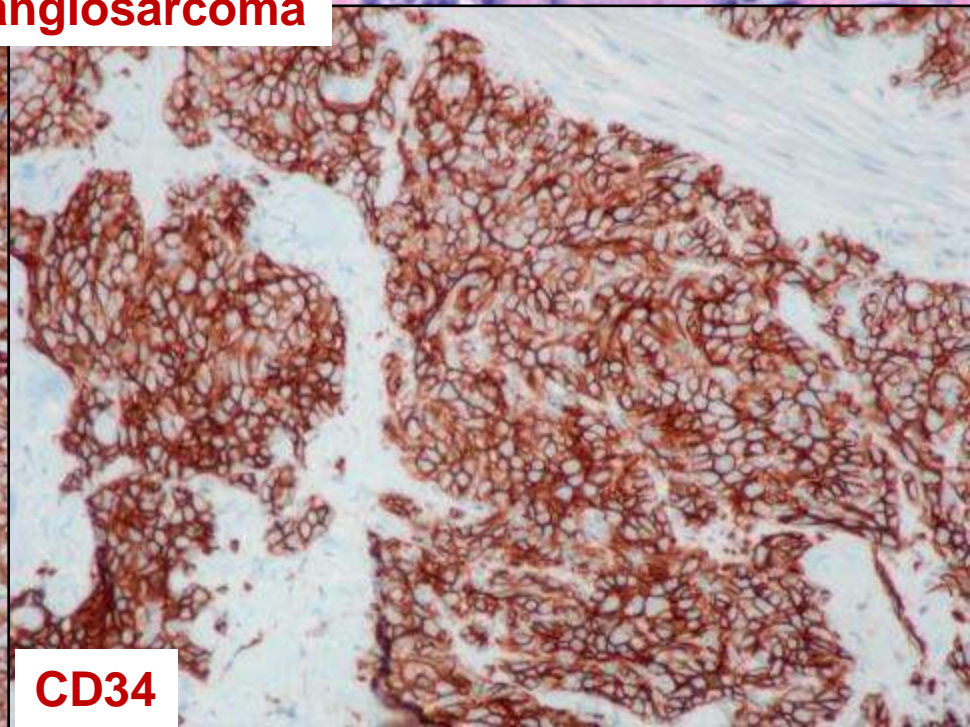
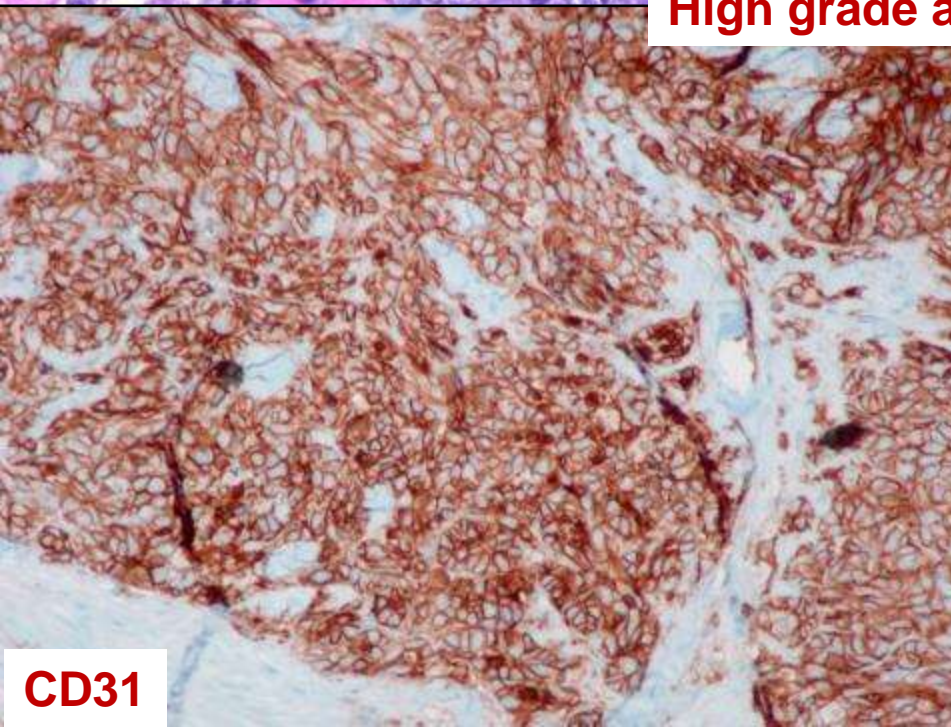




Pan cytokeratin



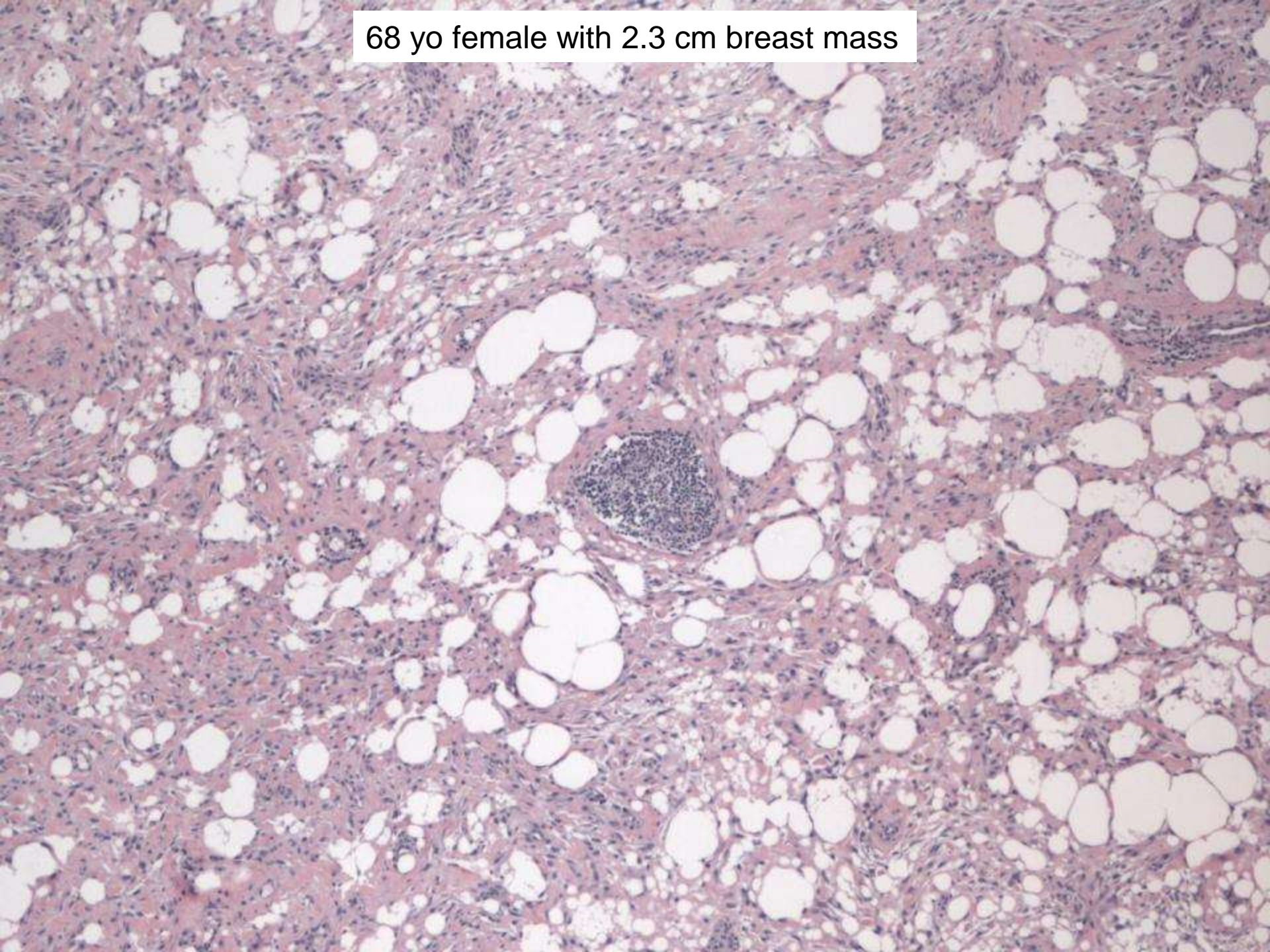
High grade angiosarcoma

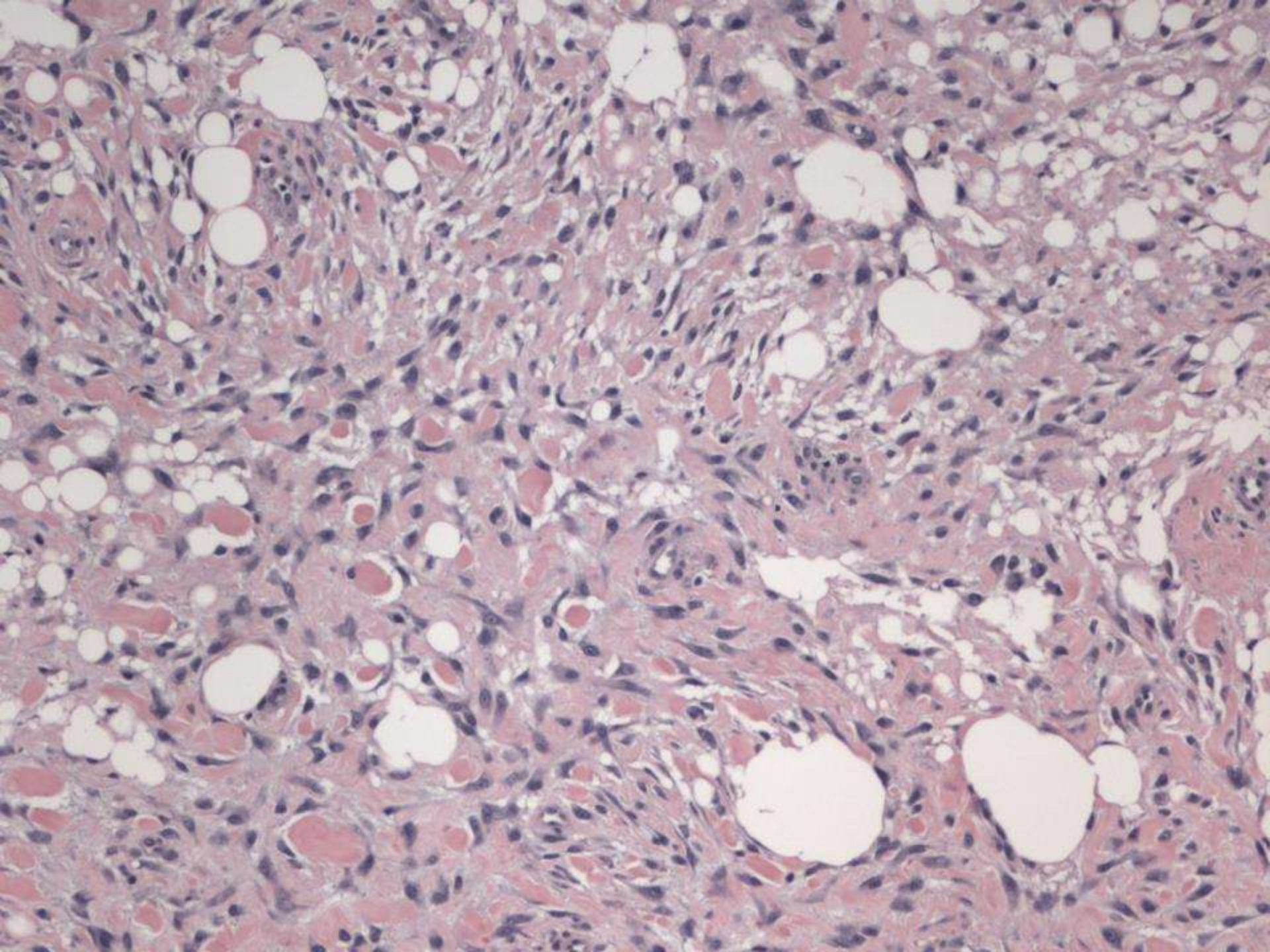


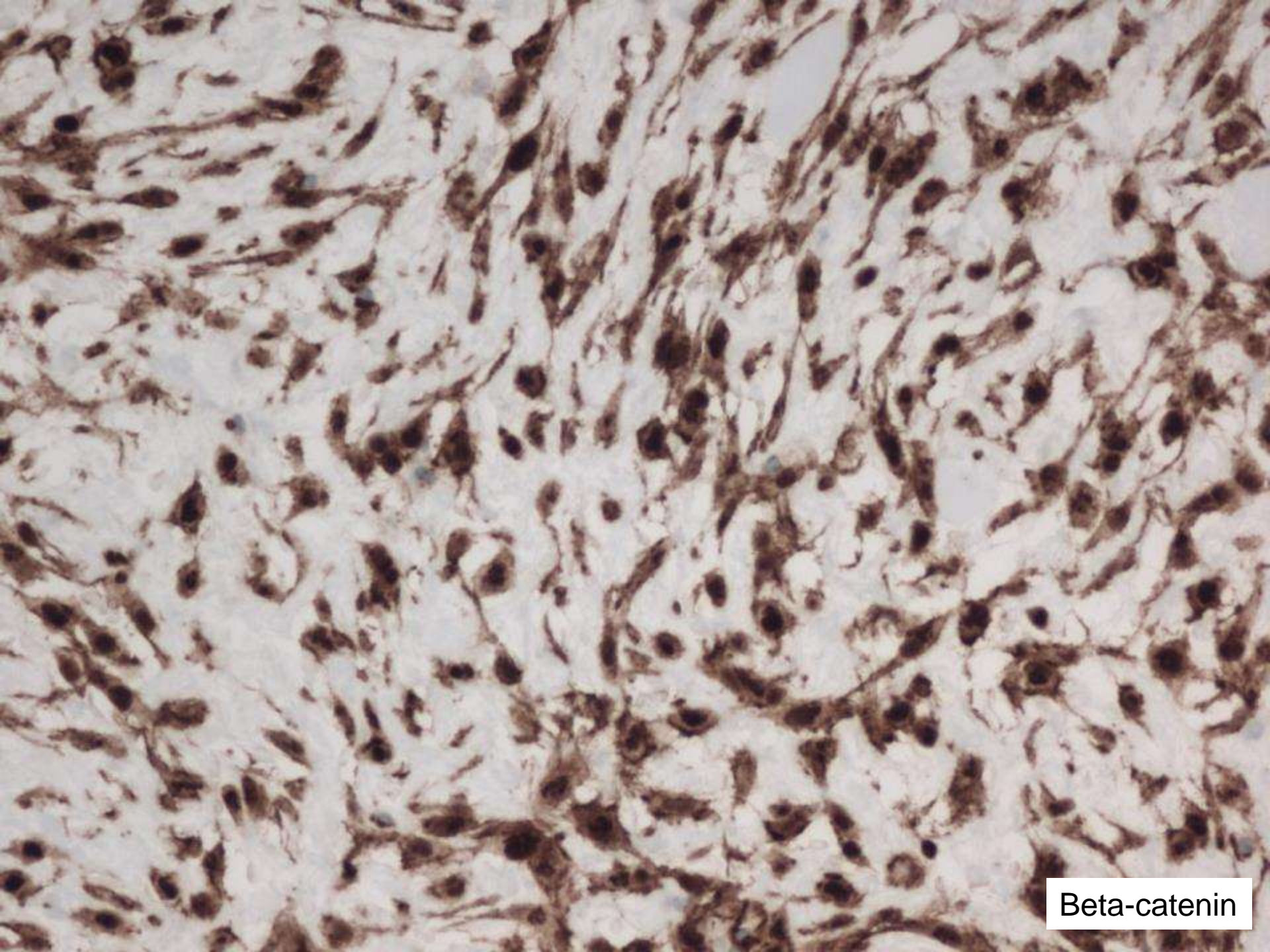
CD31

CD34

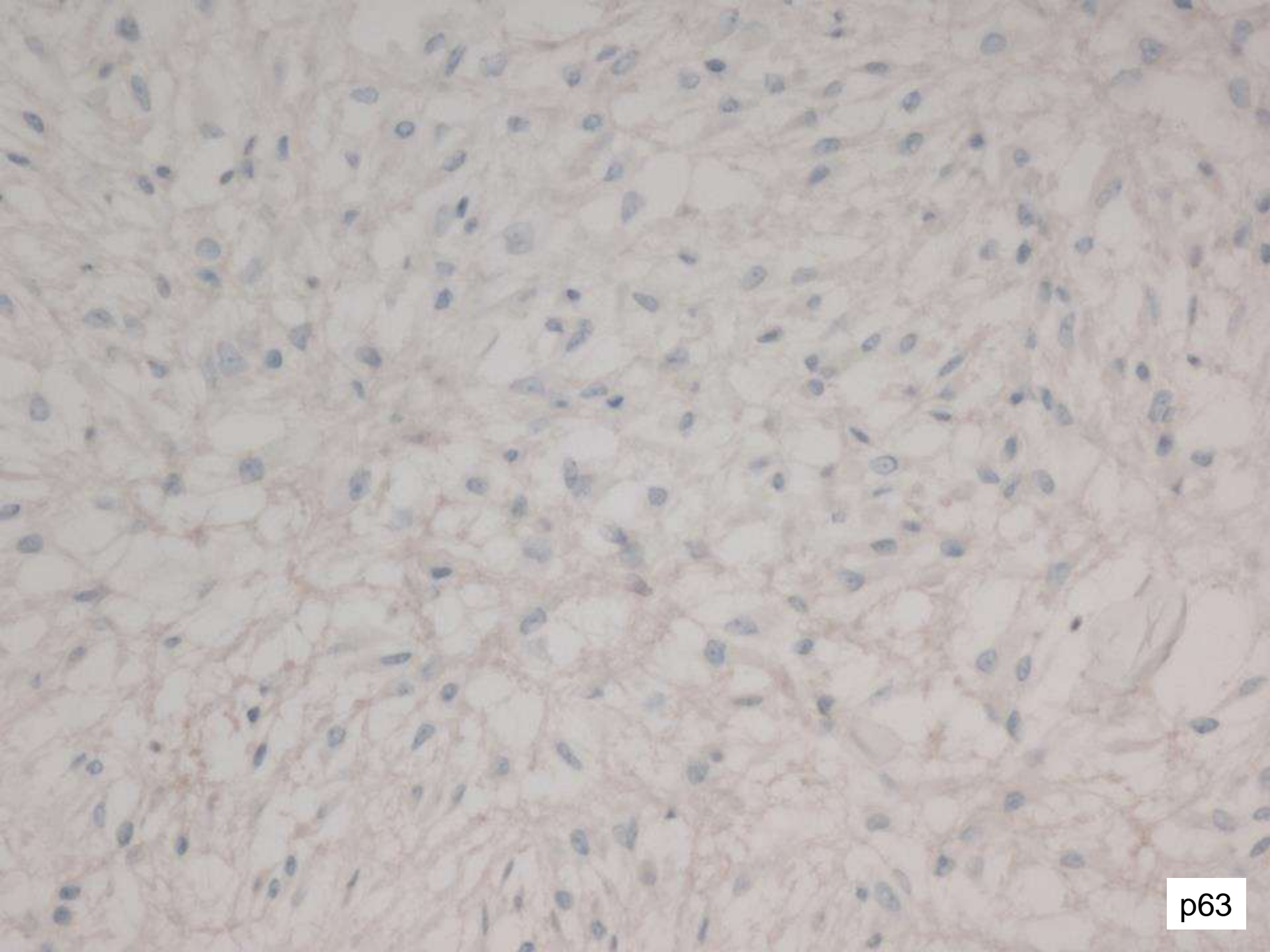
68 yo female with 2.3 cm breast mass







Beta-catenin



Immunohistochemistry

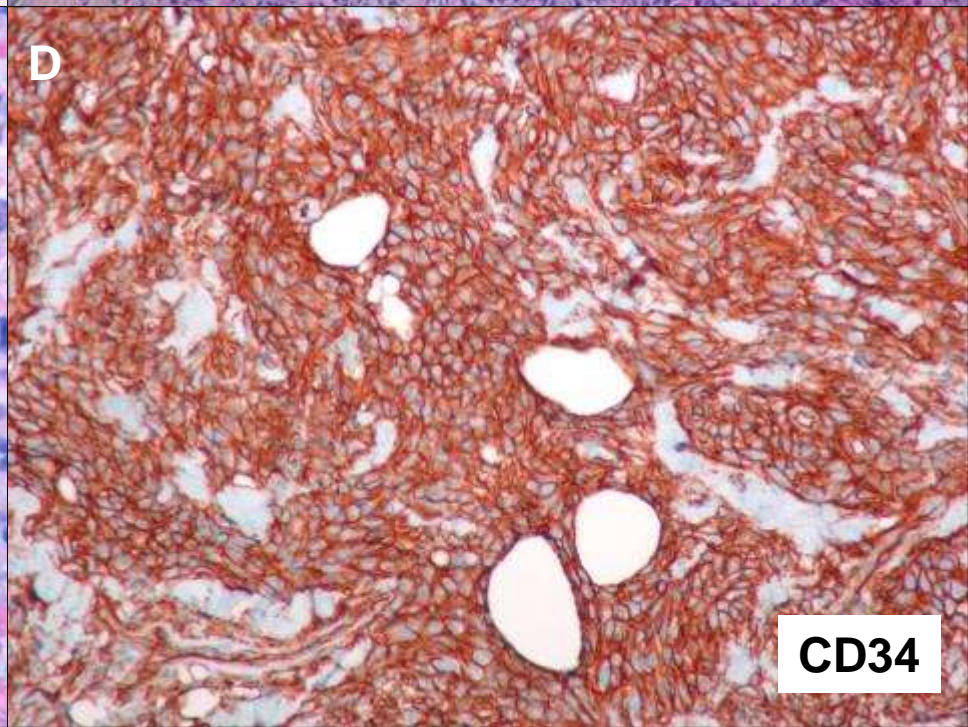
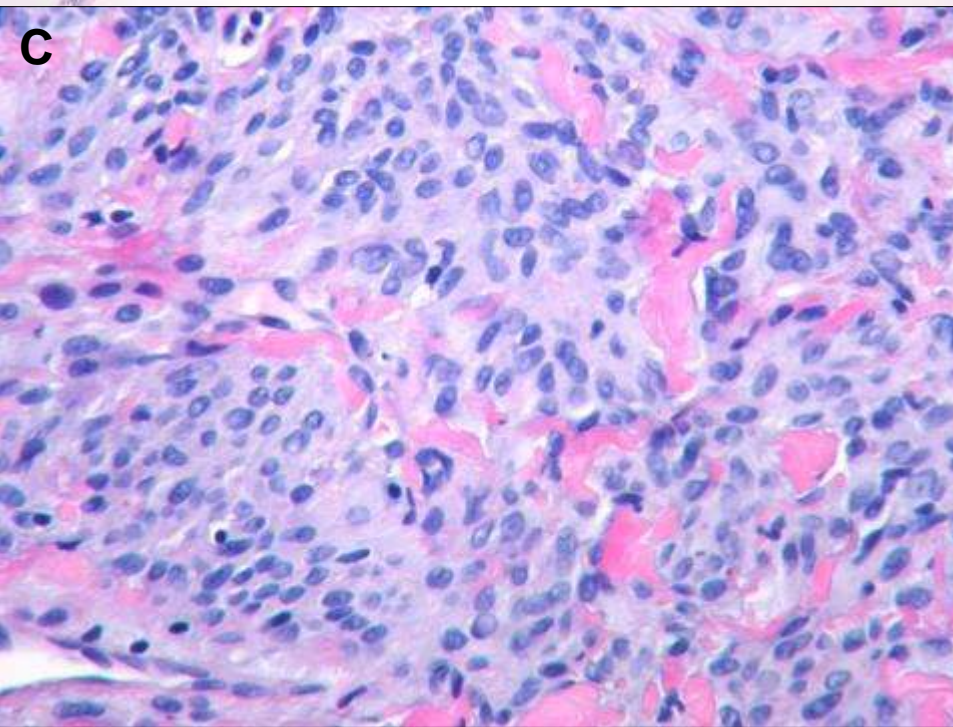
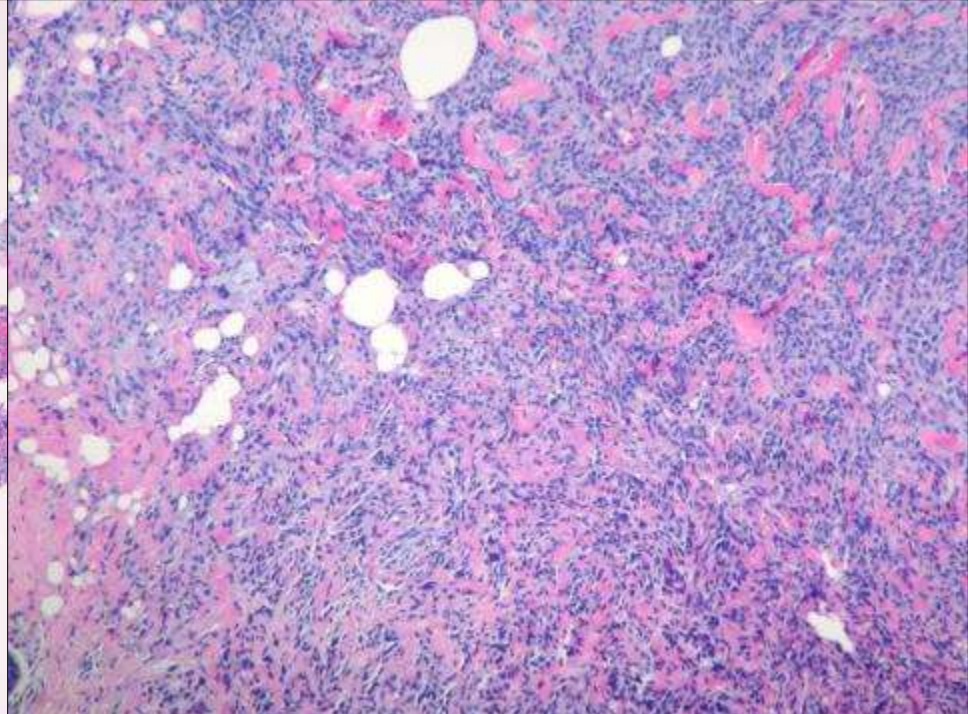
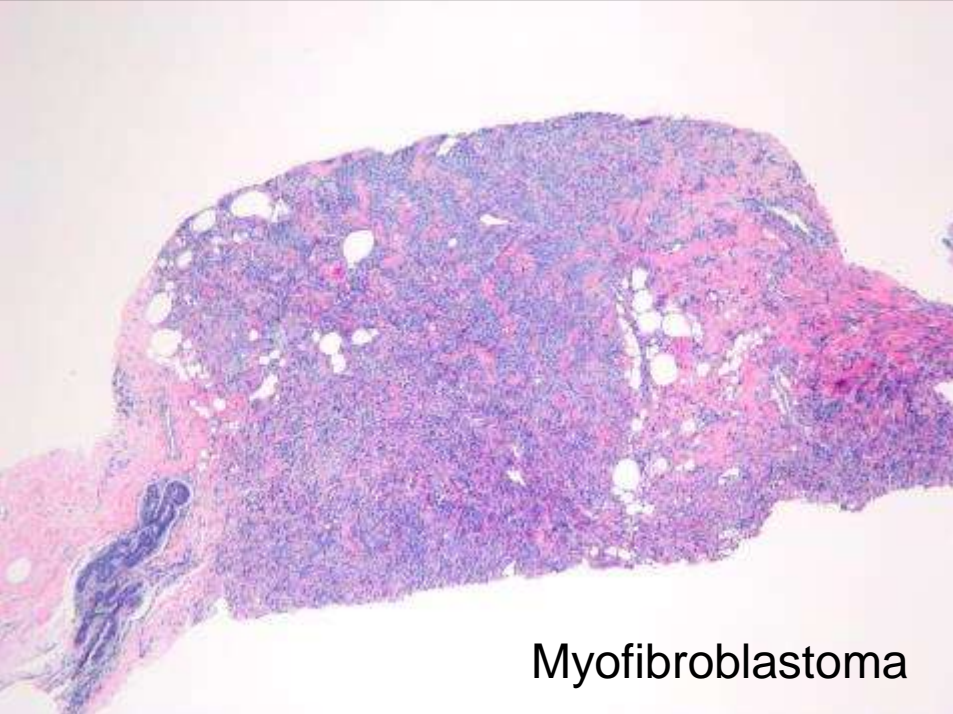
POSITIVE STAINS

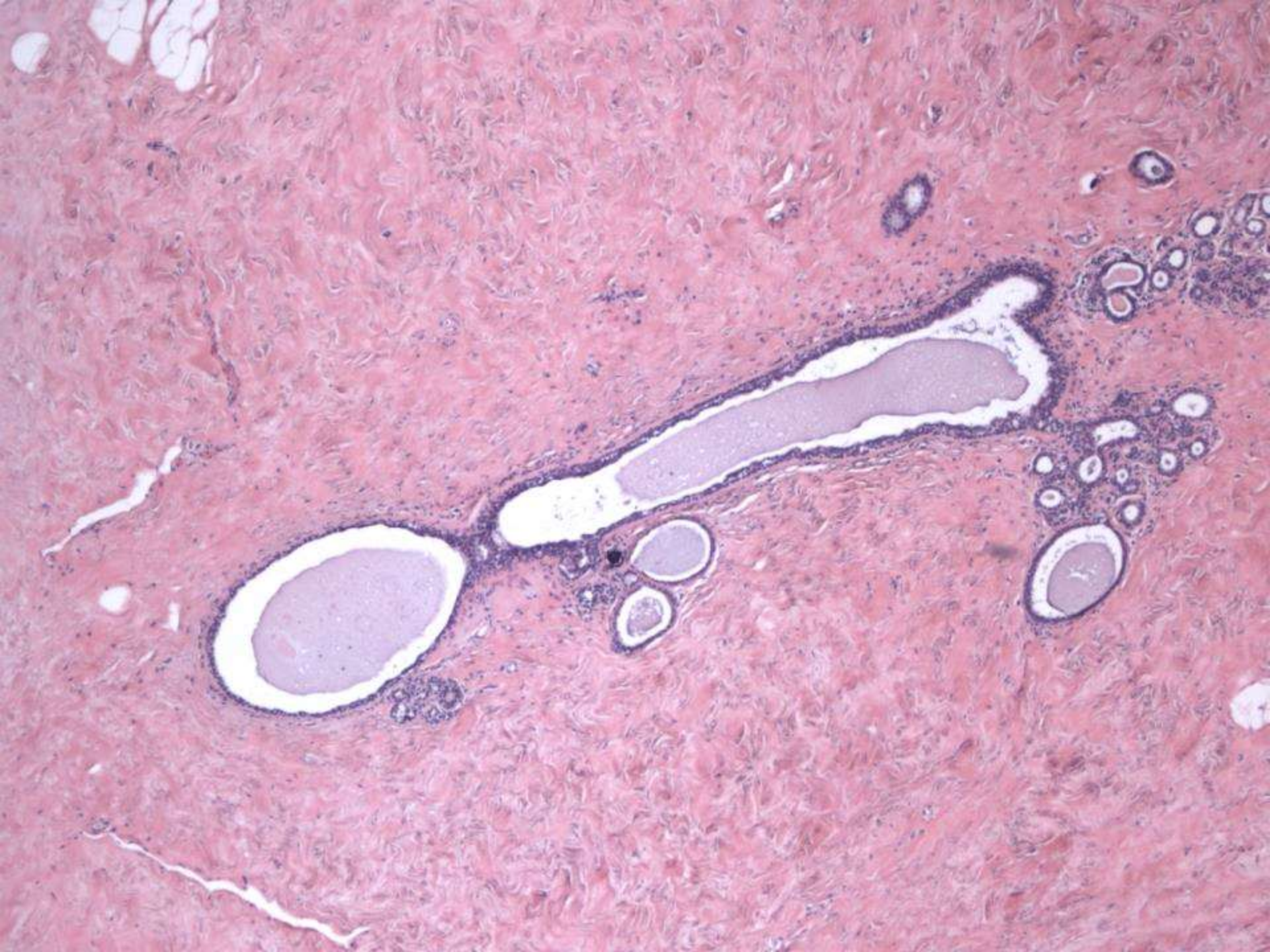- Beta-catenin
- Vimentin
- Desmin (scattered reactivity)

NEGATIVE STAINS

- Keratins
 - AE1/AE3, CAM 5.2, CK5, CK14, CK17, CK7, CK20
- P63
- SMA
- ER/PR
- CD34

Diagnosis: Fibromatosis

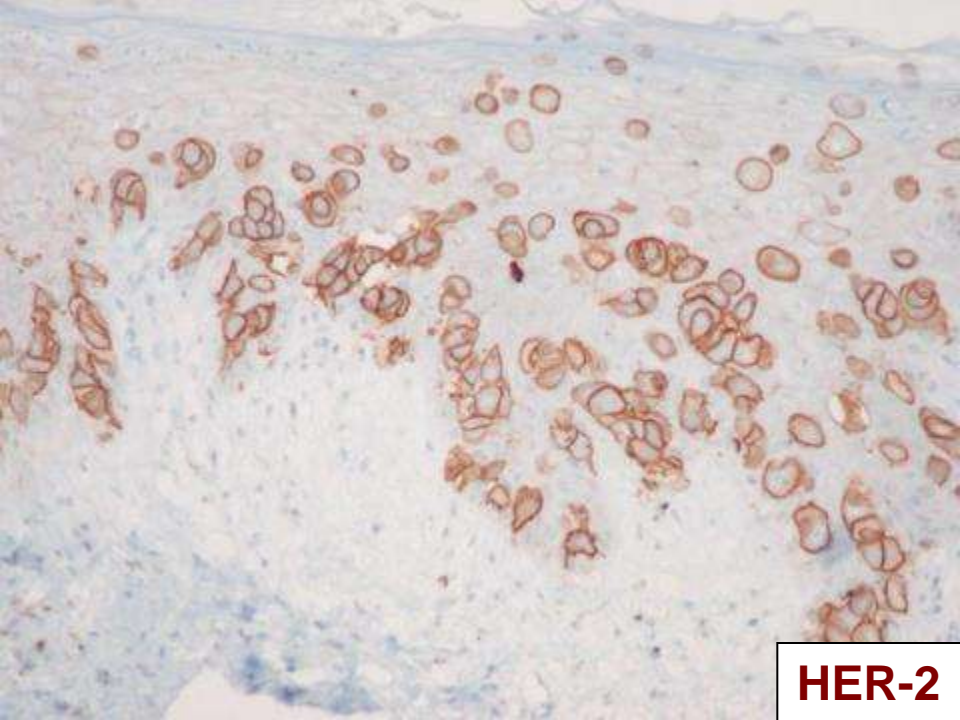
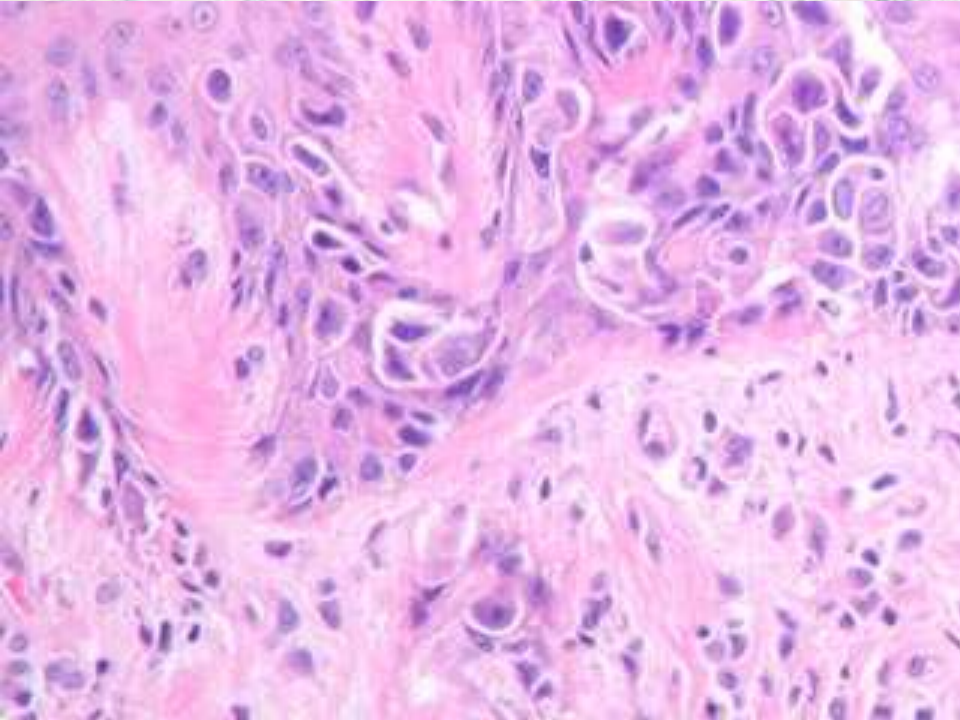
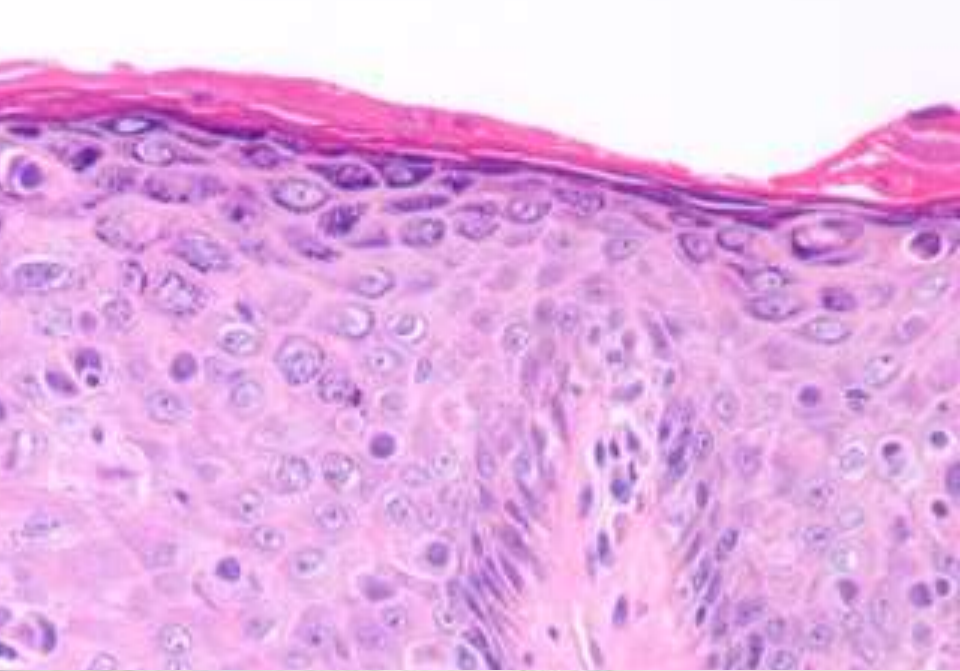
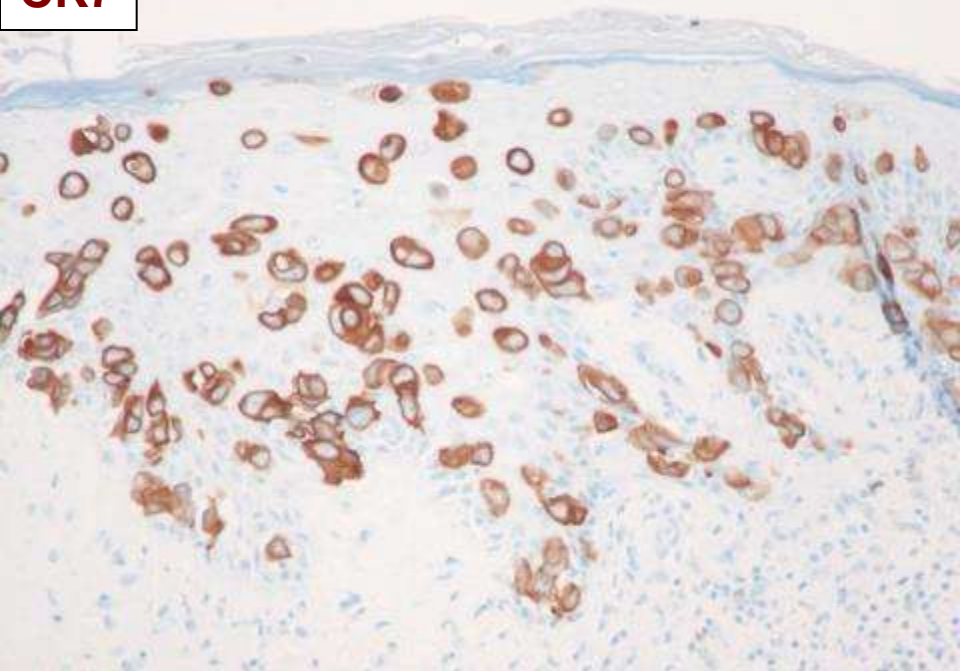




Paget's Disease

- Involvement of nipple epidermis by underlying breast carcinoma
- Differential diagnosis includes
 - Bowen's disease (squamous cell carcinoma in situ)
 - Melanoma
- Positive stains for Paget's
 - CK7
 - HER2

CK7



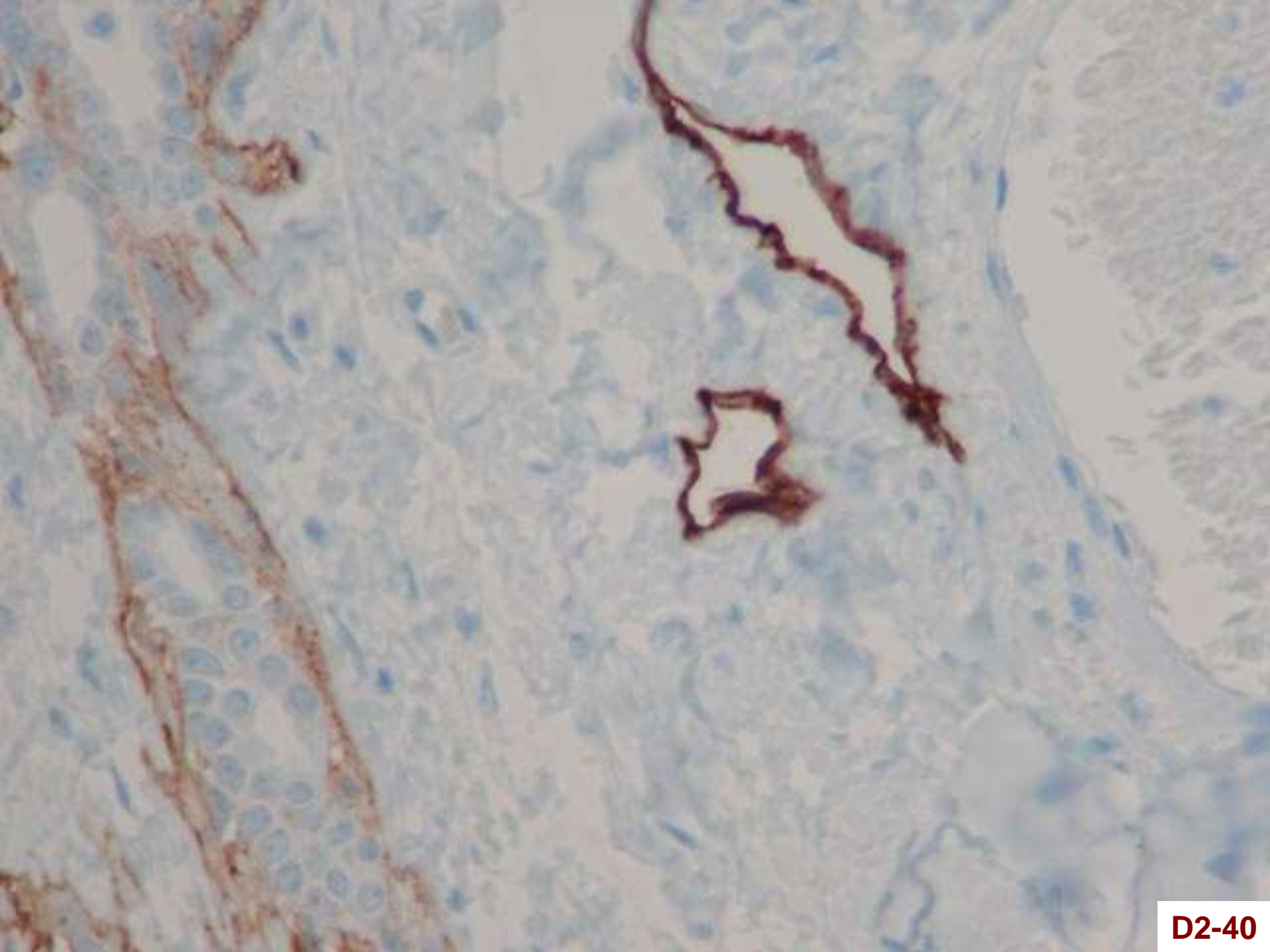
HER-2

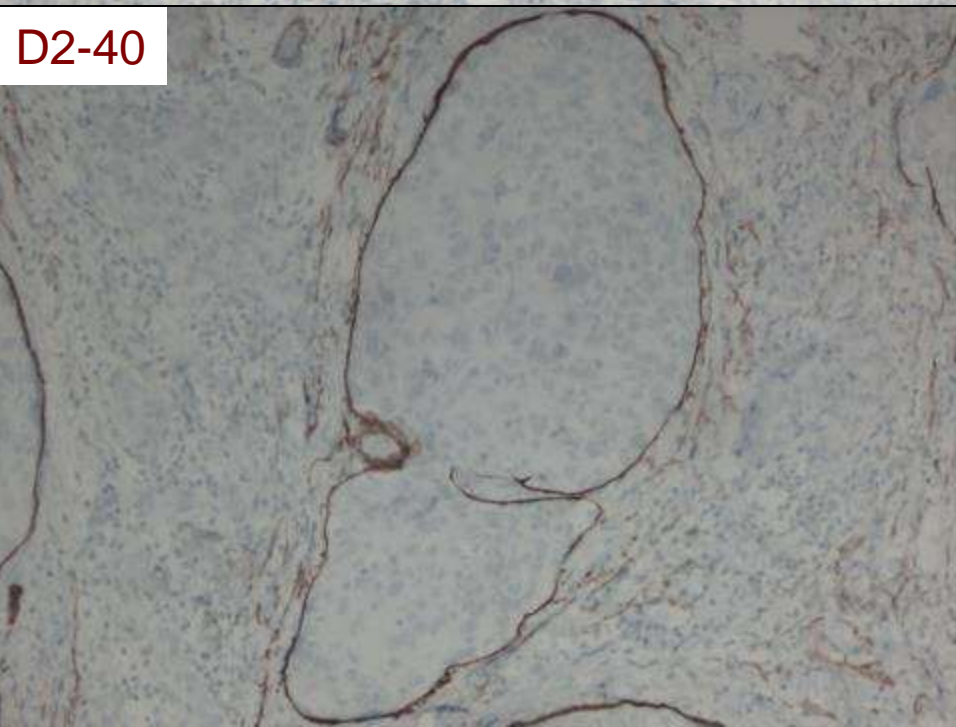
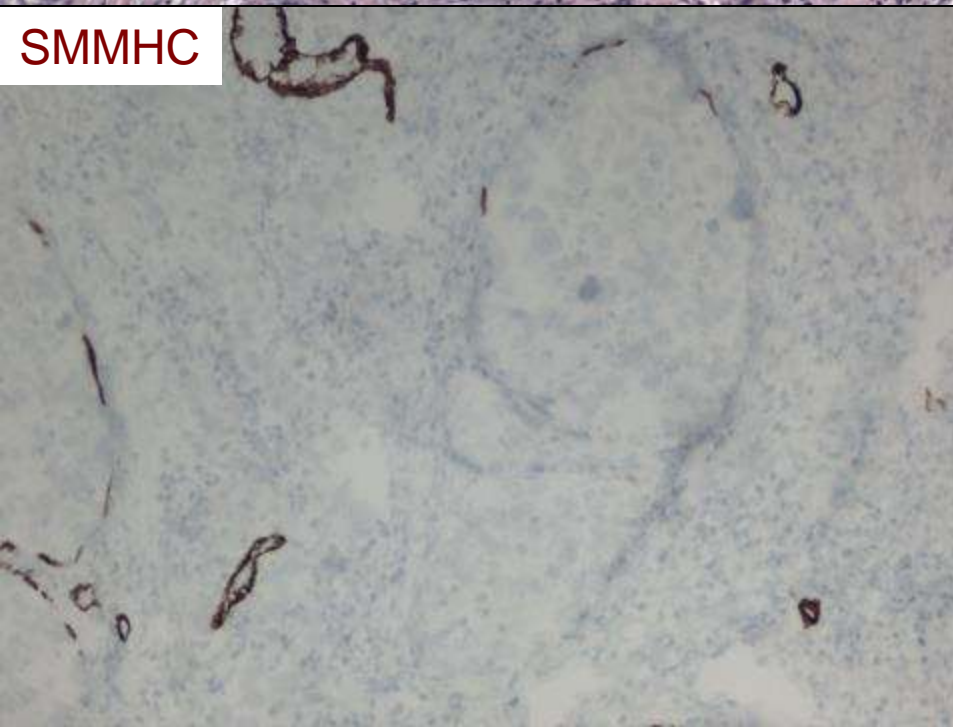
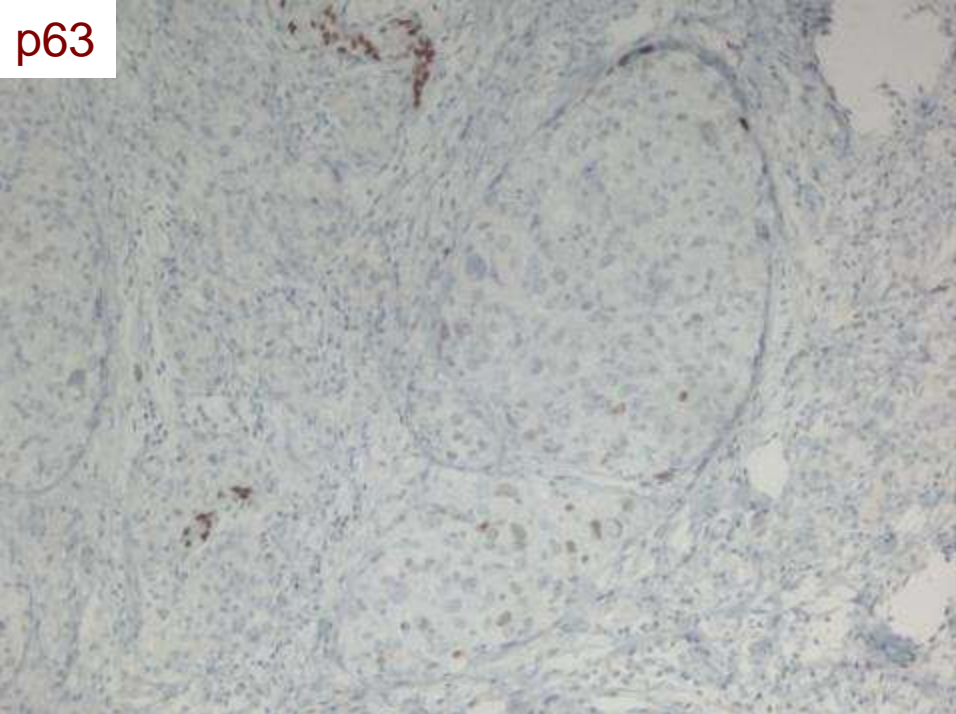
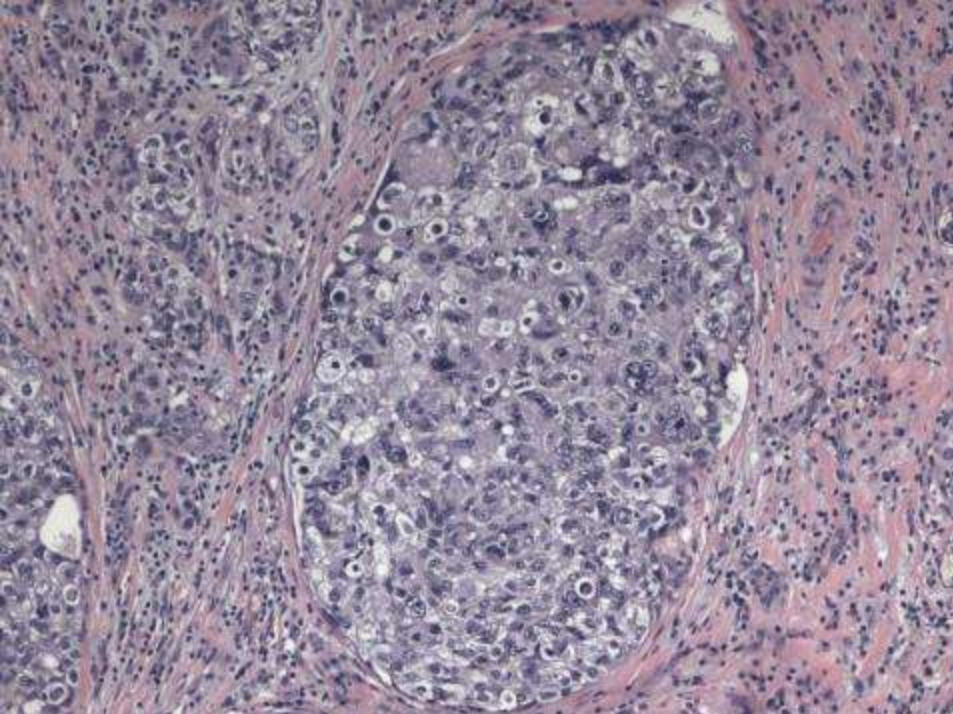
Paget's Disease

- Helpful negative stains
 - CK5/6, p63, S100, HMB-45, Melan A
- Less helpful positive stains
 - ER, GCDFP-15, CEA
- Pitfalls of IHC
 - CK7+ cells
 - Intraepidermal clear cells
 - Inter-epithelial extension of lactiferous duct cells
 - S100 is positive in 18% of Paget's disease

Assessment of Lymphatic Space Invasion by D2-40

- Peritumoral lymphatic space invasion is predictive of lymph node metastasis
- D2-40 is a selective lymphatic endothelial marker
 - Helpful in identifying lymphatic space invasion
 - Helpful in identifying lymphatic tumor emboli in cases of inflammatory carcinoma
- Pitfall
 - Moderate staining at periphery of ducts





p63

SMMHC

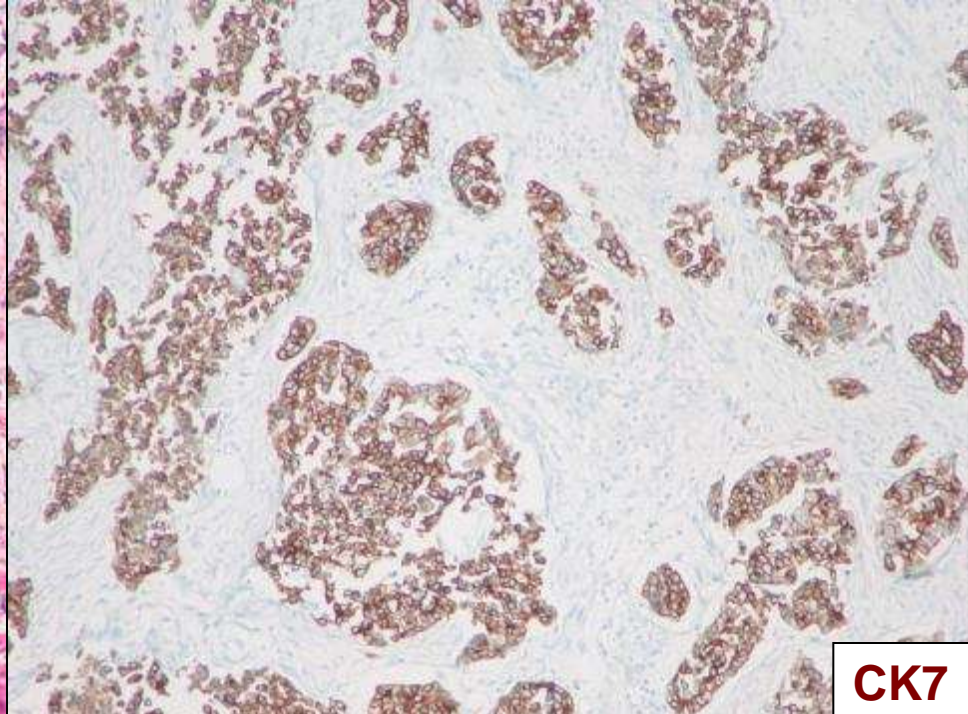
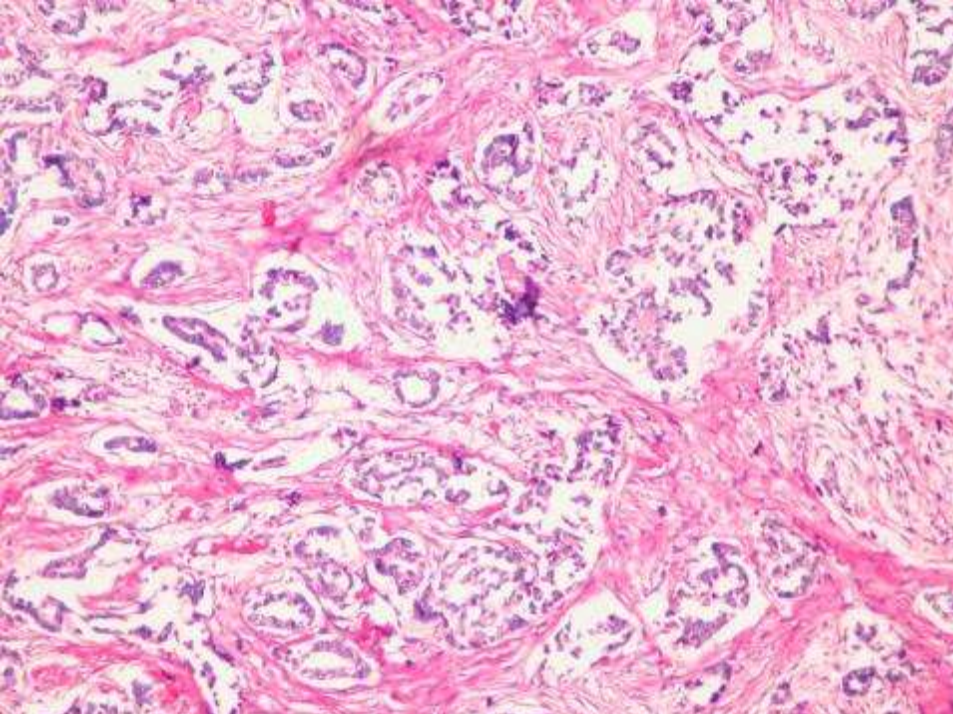
D2-40

Metastases from Breast Carcinoma

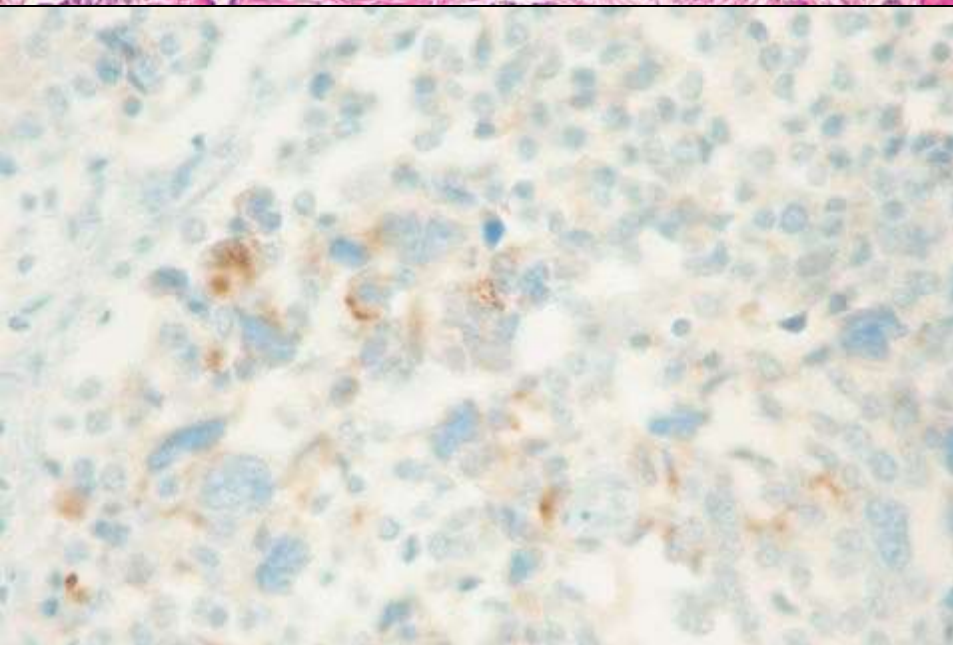
- Breast tumors are not uncommon to present as carcinoma of unknown primary
 - Most frequent site is axillary lymph node
- Breast tumors can recur/metastasize years after primary diagnosis
 - Immunohistochemical profile of metastatic tumor generally resemble the primary

Metastases from Breast Carcinoma

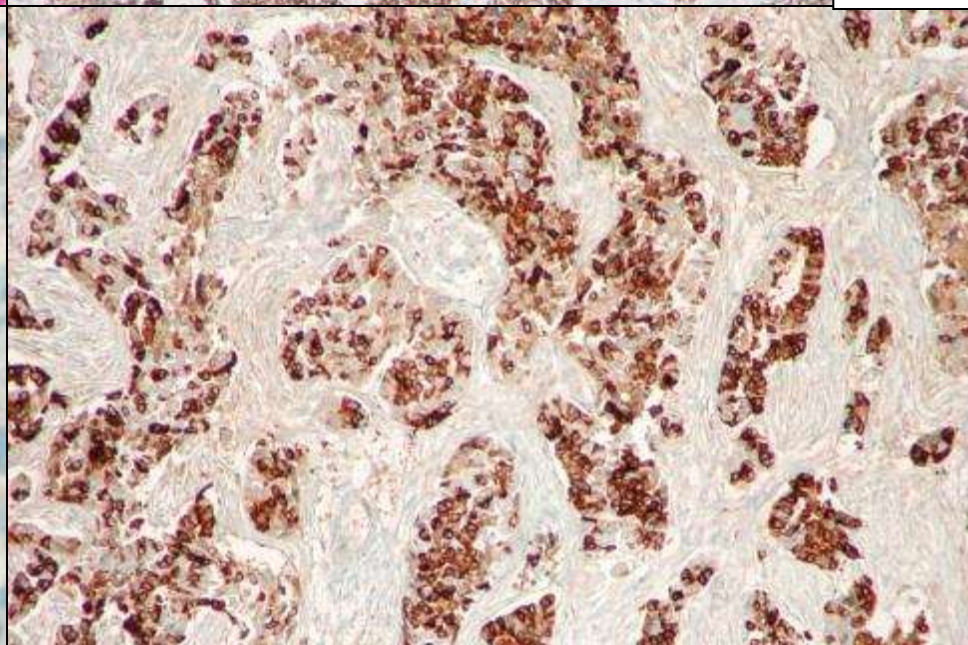
- Positive immunohistochemical stains
 - CK7, ER, GCDFP-15, mammaglobin
- Negative stains
 - CK20, TTF-1, WT1
- Tumors that mimic breast carcinoma by morphology and IHC
 - Skin adnexal tumors
 - Salivary gland ductal carcinomas GATA3 (positive in breast)
 - ~~■ Upper GI, pancreatic, hepato-biliary~~
 - ~~■ Endometrioid tumors of the ovary and endometrium~~ PAX8 (negative in breast)



CK7



GCDFP-15



Mammaglobin

IHC Profile of Breast Cancer

Appl Immunohistochem Mol Morphol. 2015 Mar;23(3):202-8. doi: 10.1097/PAI.0000000000000076.

Immunohistochemical profile of breast cancer with respect to estrogen receptor and HER2 status.

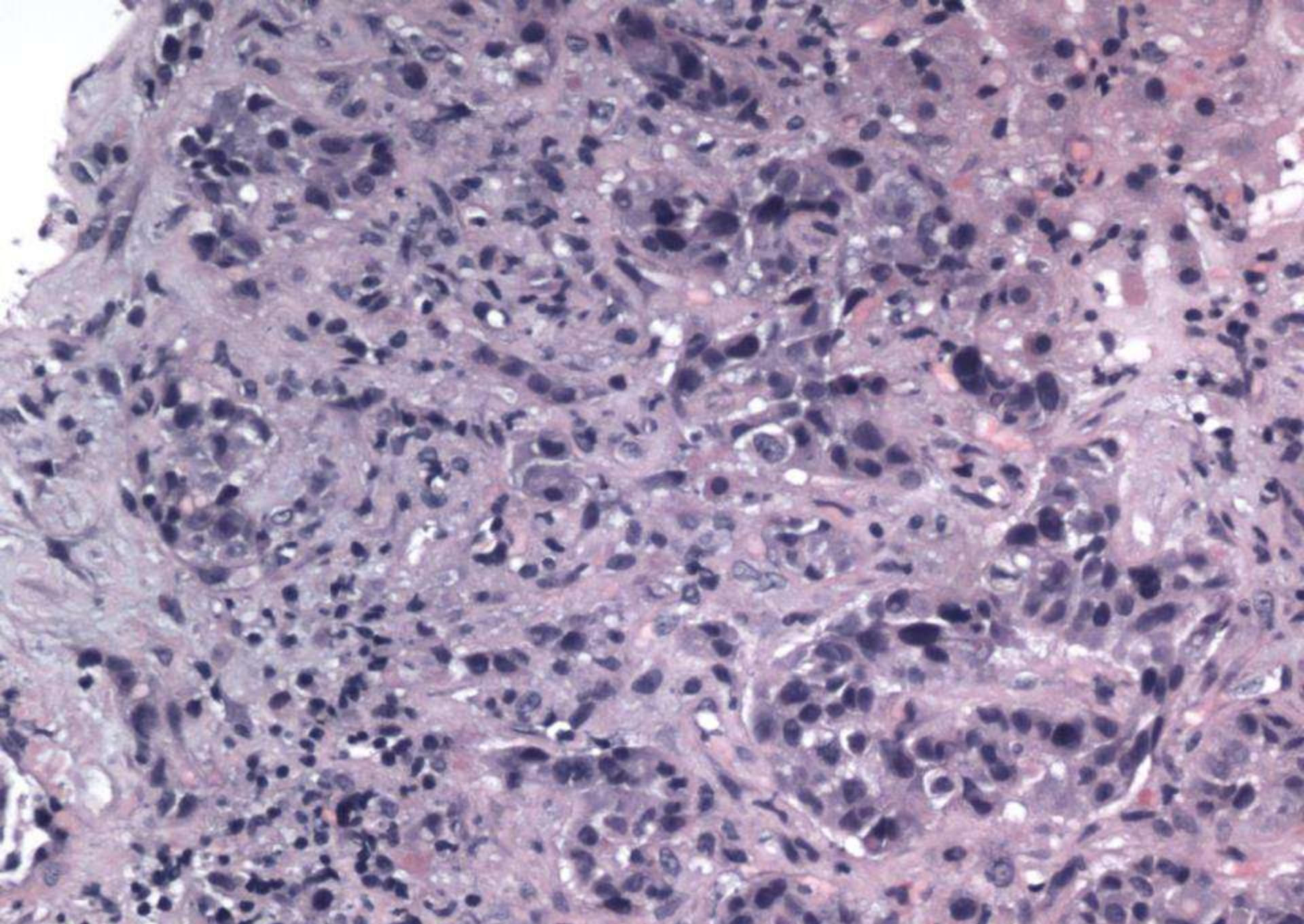
Gloyeske NC¹, Woodard AH, Elishaev E, Yu J, Clark BZ, Dabbs DJ, Bhargava R.

Author information

Abstract

There are a few studies that have evaluated a panel of stains on a single large data set of breast cancers, which is required for direct comparison between antibodies. The immunohistochemical panel in this study was chosen to include breast-specific markers and markers that are expressed in tumors resembling breast cancer. The individual marker positivity in decreasing order was 95% (177/186) for GATA-3, 92% (172/186) for cytokeratin (CK)7, 80% (151/189) for AR, 80% for estrogen receptor (158/198), 69% for progesterone receptor (137/198), 55% (105/190) for NY-BR-1, 52% (99/189) for mammaglobin, 31% (59/191) for vimentin, 26% (51/195) for GCDP-15, 0.5% (1/186) for CK20, and 0% (0/188) for PAX-8. When tumors were categorized based on estrogen receptor and HER2 status, a total of 45 profiles were identified. In addition, some tumors showed an unconventional profile-although the majority of breast carcinomas were CK7-positive/CK20-negative, a CK7-negative/CK20-negative profile was seen in ~8% of the cases. Such a profile can create confusion in investigation of a carcinoma of unknown origin. The results define the individual sensitivity of each marker and establish a baseline diagnostic profile of breast cancer in a large data set. In addition, the results support the use of immunohistochemical panel for confirming or determining breast as the source of metastasis.

PMID: 25356941 [PubMed - in process]



71 years old with hx of breast cancer few yrs ago (outside hospital), now with liver lesion

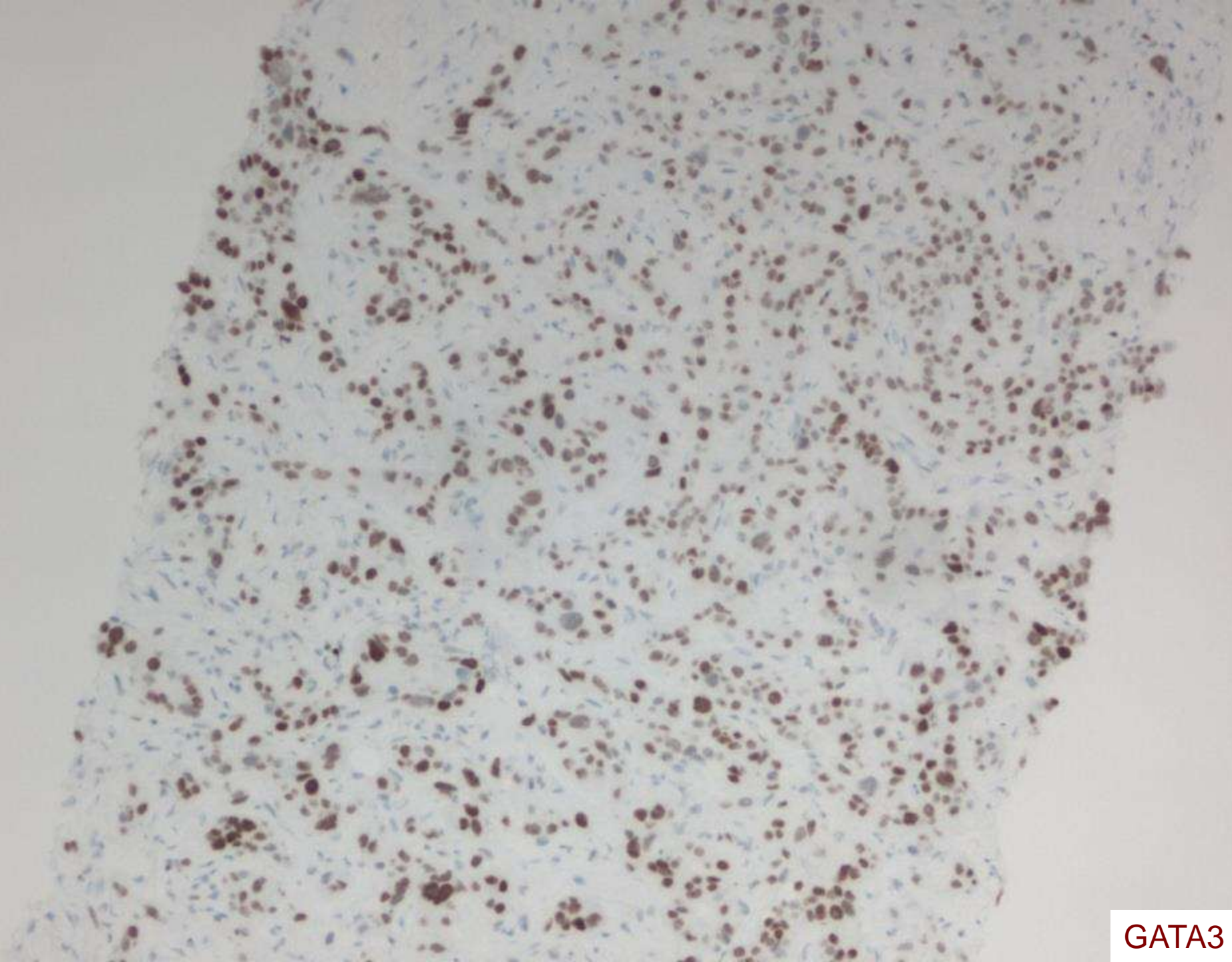
Immunohistochemistry

POSITIVE STAINS

- CK7

NEGATIVE STAINS

- CK20
- GCDFP-15
- Mammaglobin
- TTF₁
- PAX8
- CDX₂
- ER/PR
- HER₂



GATA3

Summary

- IHC is frequently used in diagnostic breast pathology
- Straight-forward in most cases
- Challenging with respect to papillary and spindle cell lesions
- Always correlate IHC with tissue morphology
- Research unusual reactivity or show / ask someone with sub-specialty interest / expertise

