

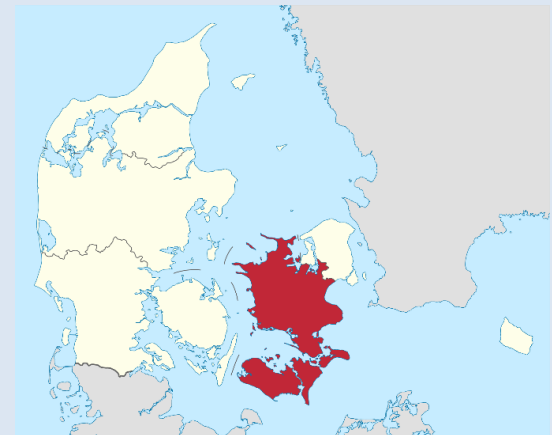# Breast cancer: IHC for diagnostic use

**NordiQC Workshop in Diagnostic Immunohistochemistry 2023**

**Aalborg University Hospital**

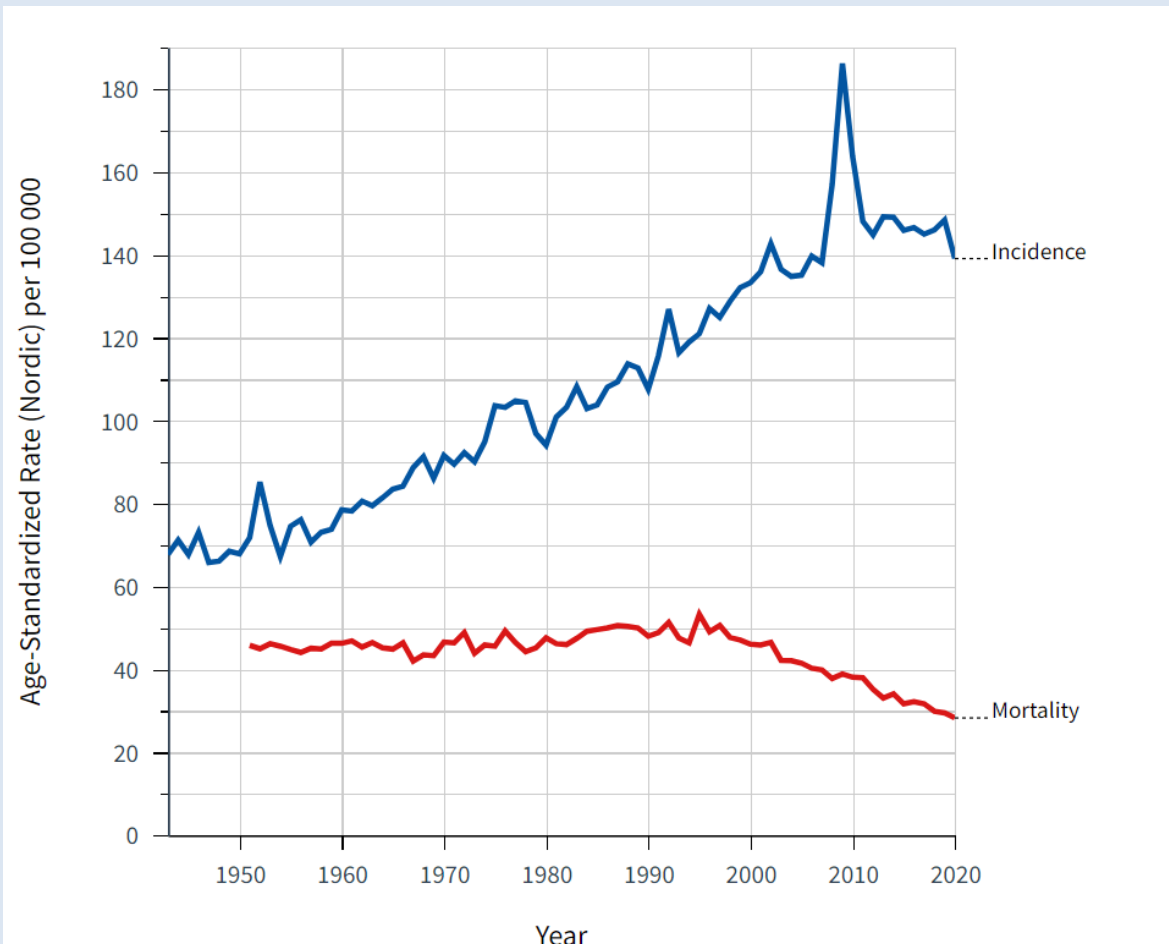
**October 4<sup>th</sup> – 6<sup>th</sup> 2023**

Anne-Vibeke Lænkholm  
Department of Surgical Pathology  
Zealand University Hospital  
Roskilde  
Denmark



# Breast cancer: incidence and mortality

## Denmark



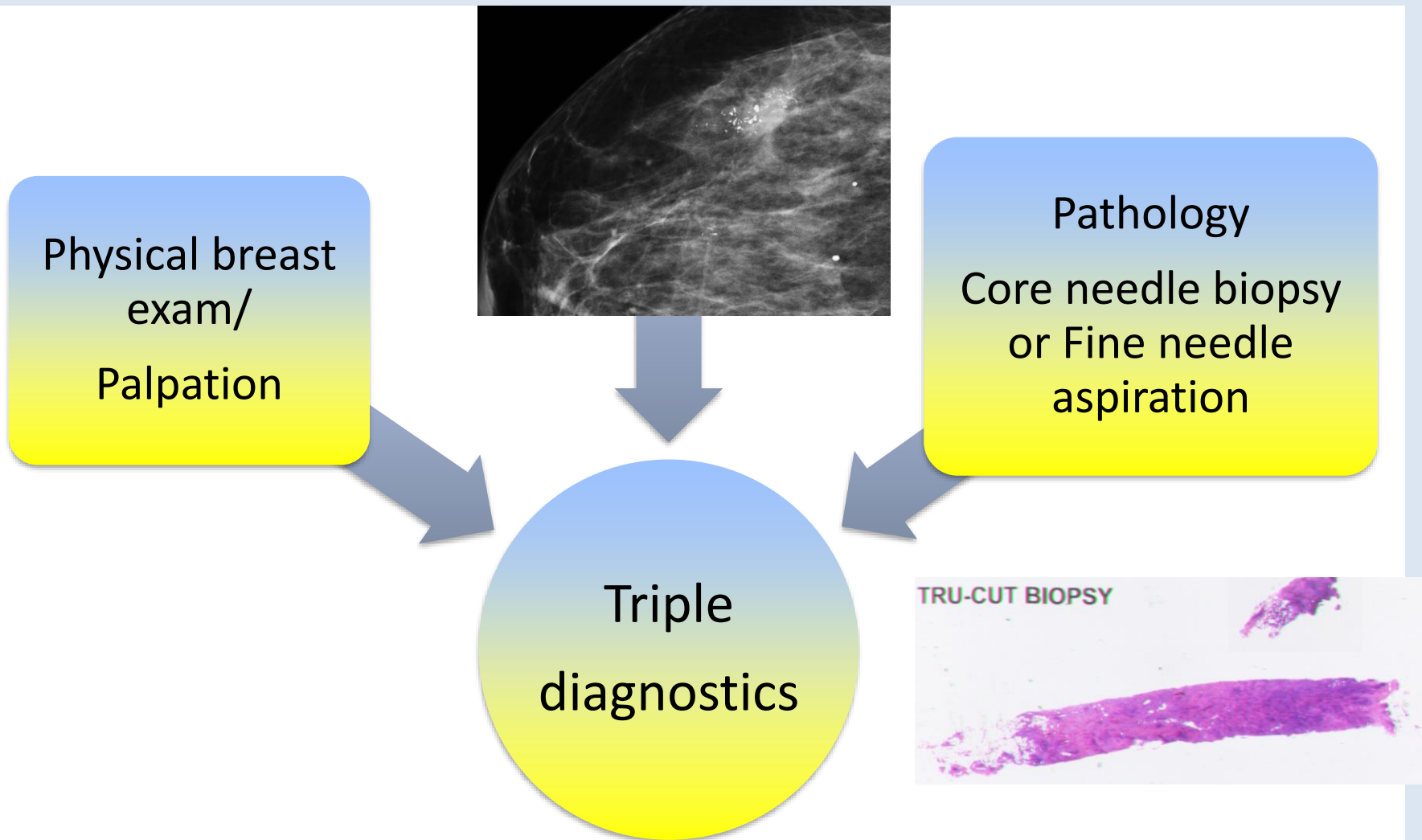
Annually  
app 4700-  
5000 new  
cases

# Agenda

- Immunohistochemical biomarkers for
  - **Diagnostics**
    - Benign Hyperplasia and Ductal Carcinoma in Situ
    - Ductal Carcinoma in Situ and Lobular Carcinoma in Situ
    - Carcinoma In Situ and Invasive Carcinoma
  - **Histological subtype classification**
    - Malignant breast tumors
  - **Predictive/Prognostic markers**
    - Estrogen Receptor
    - Progesteron Receptor
    - HER2 and *HER2 low status*
    - Ki67
    - PD-L1
    - Molecular subtypes

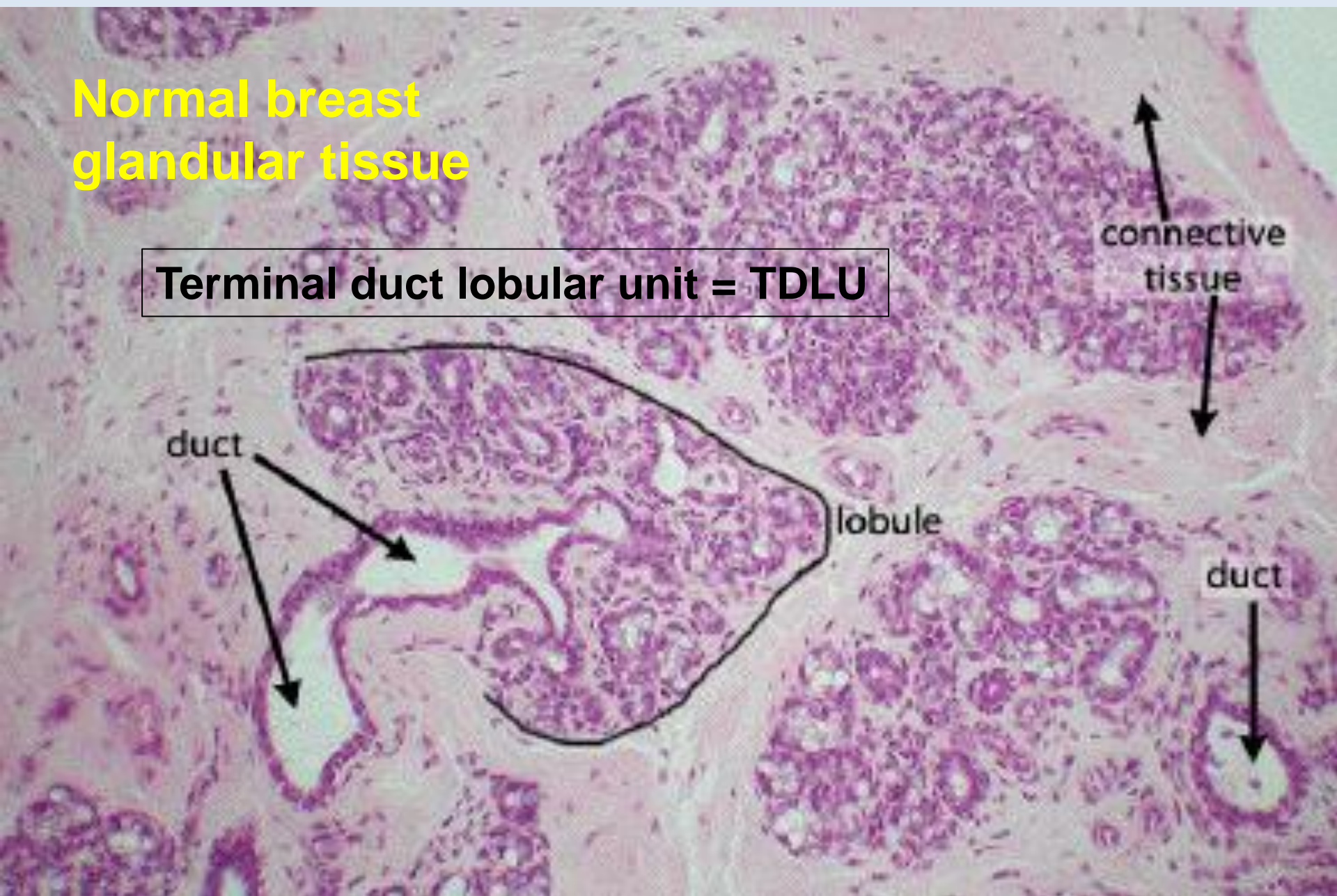
# Triple Test

## Diagnostic approach – Breast Tumours



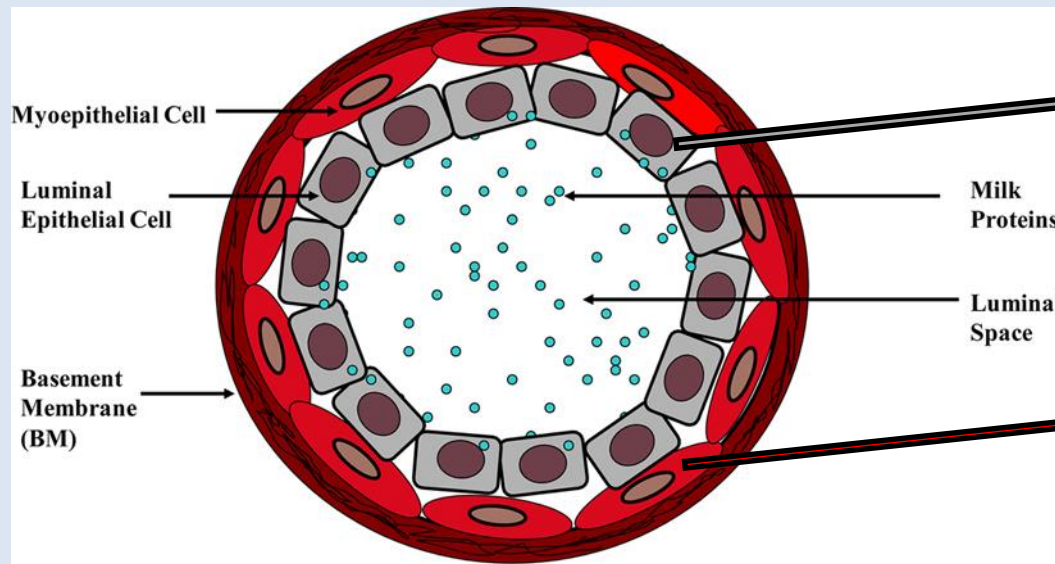
# Normal breast glandular tissue

Terminal duct lobular unit = TDLU





# Epithelial cells with specific immunohistochemical phenotype



**Luminal markers (LMW):**  
CK7, CK8, CK18, CK19

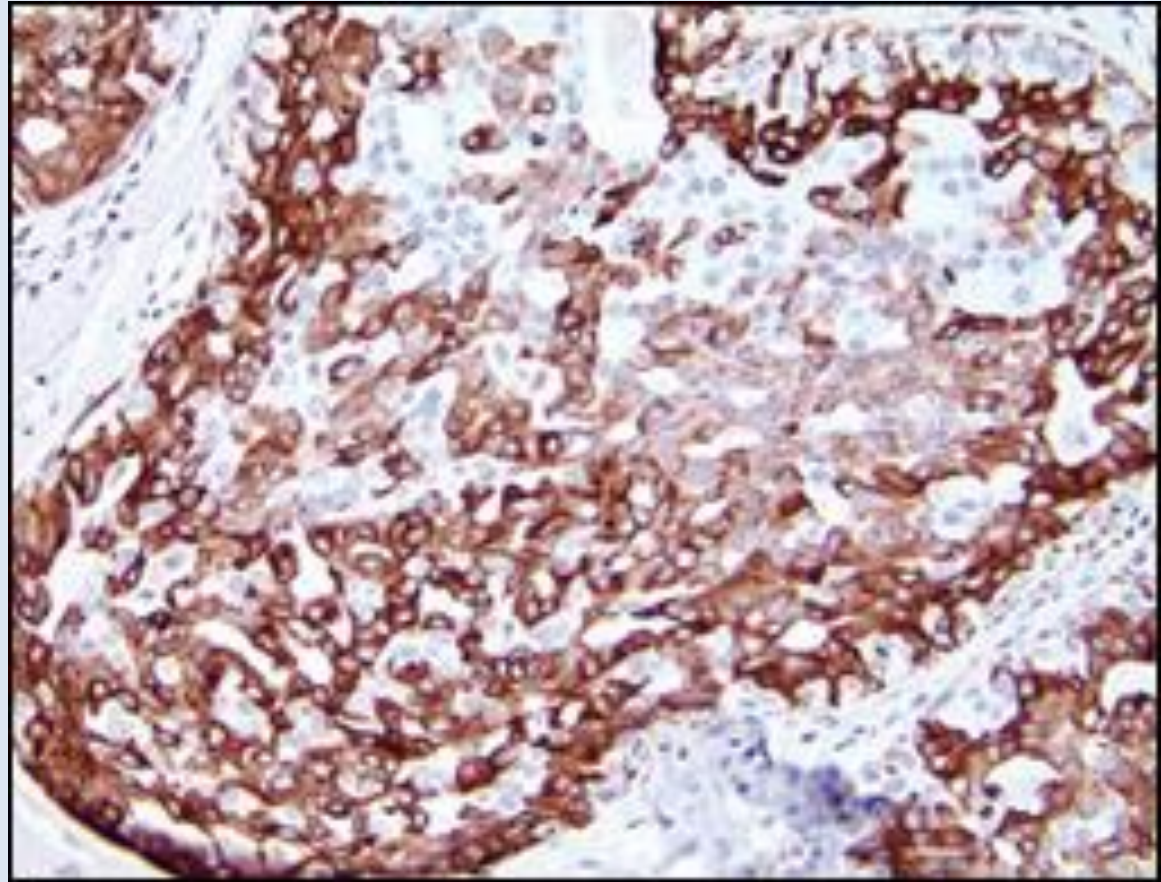
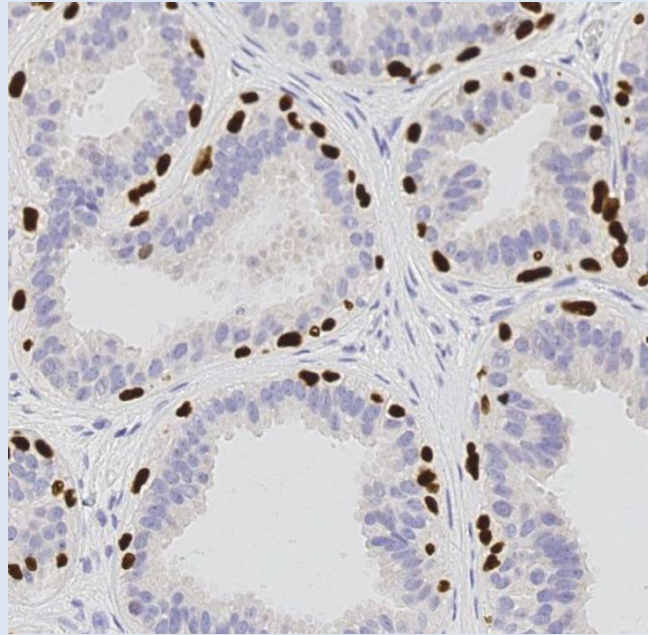
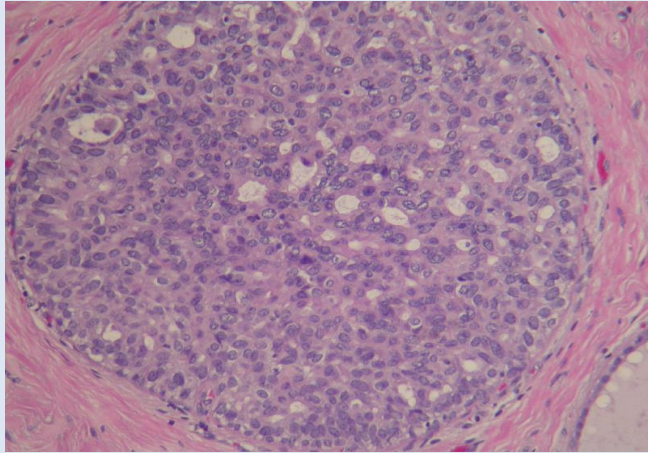
## **Myoepithelial markers:**

*Myo:* p63, SMA, CD10, SMMHC\*  
*Cytokeratins (HMW):* CK5, CK14, CK17

\*Smooth muscle myosin heavy chain

# Benign hyperplasia

## Positive staining for myoepithelial cells



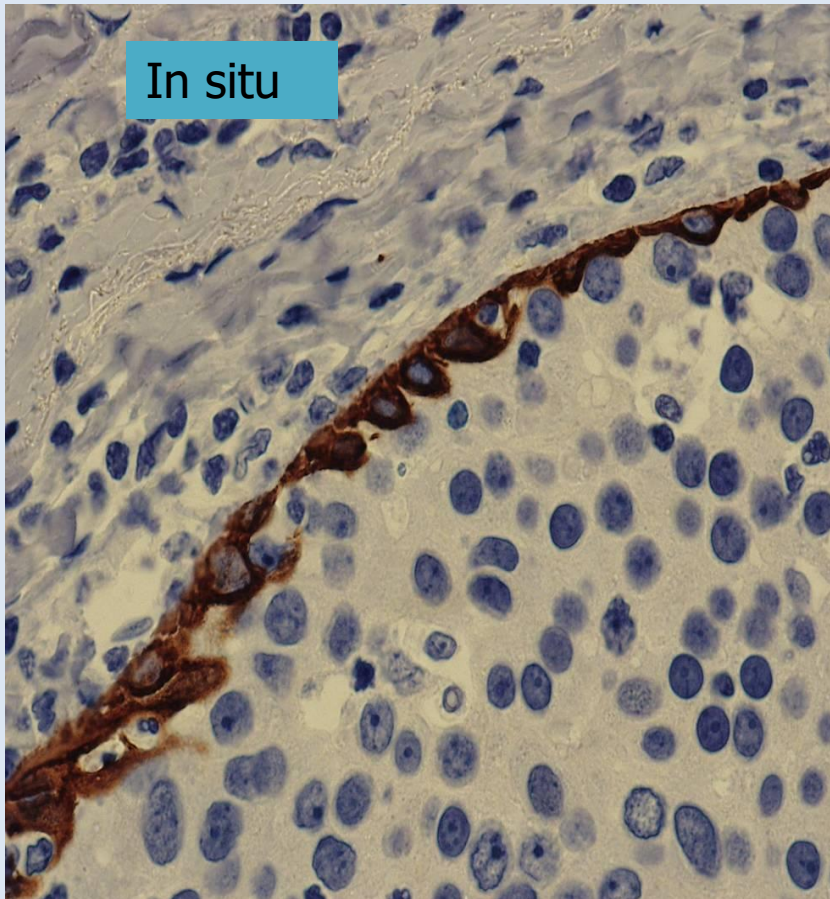
P63

CK5



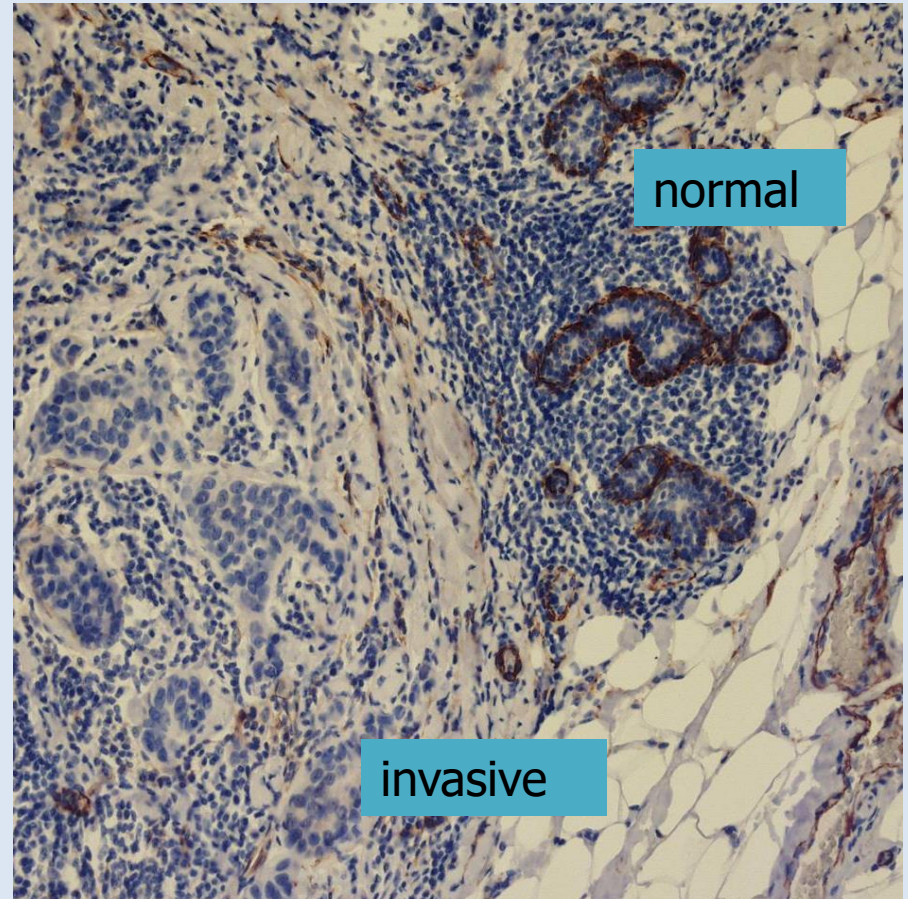
# Differentiation between ductal carcinoma in situ and invasive carcinoma i.e. SMMHC\*

present



Detecting "presence"

Not present



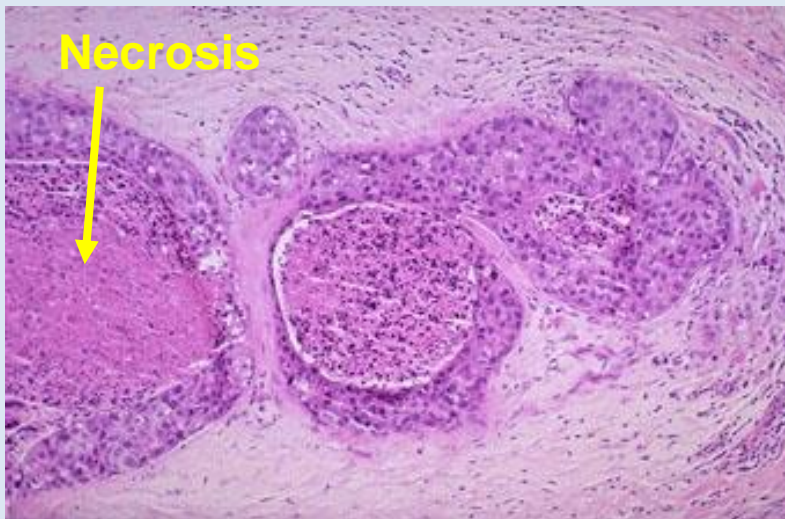
Detecting "absence"

\* Smooth muscle myosin heavy chain, as detected with clone SMMS-1

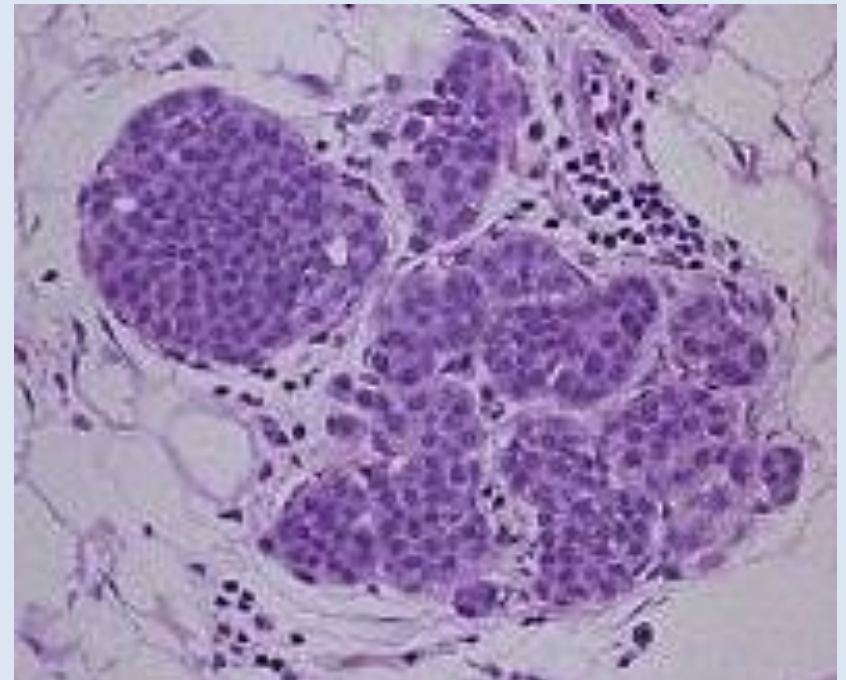


# Carcinoma in situ

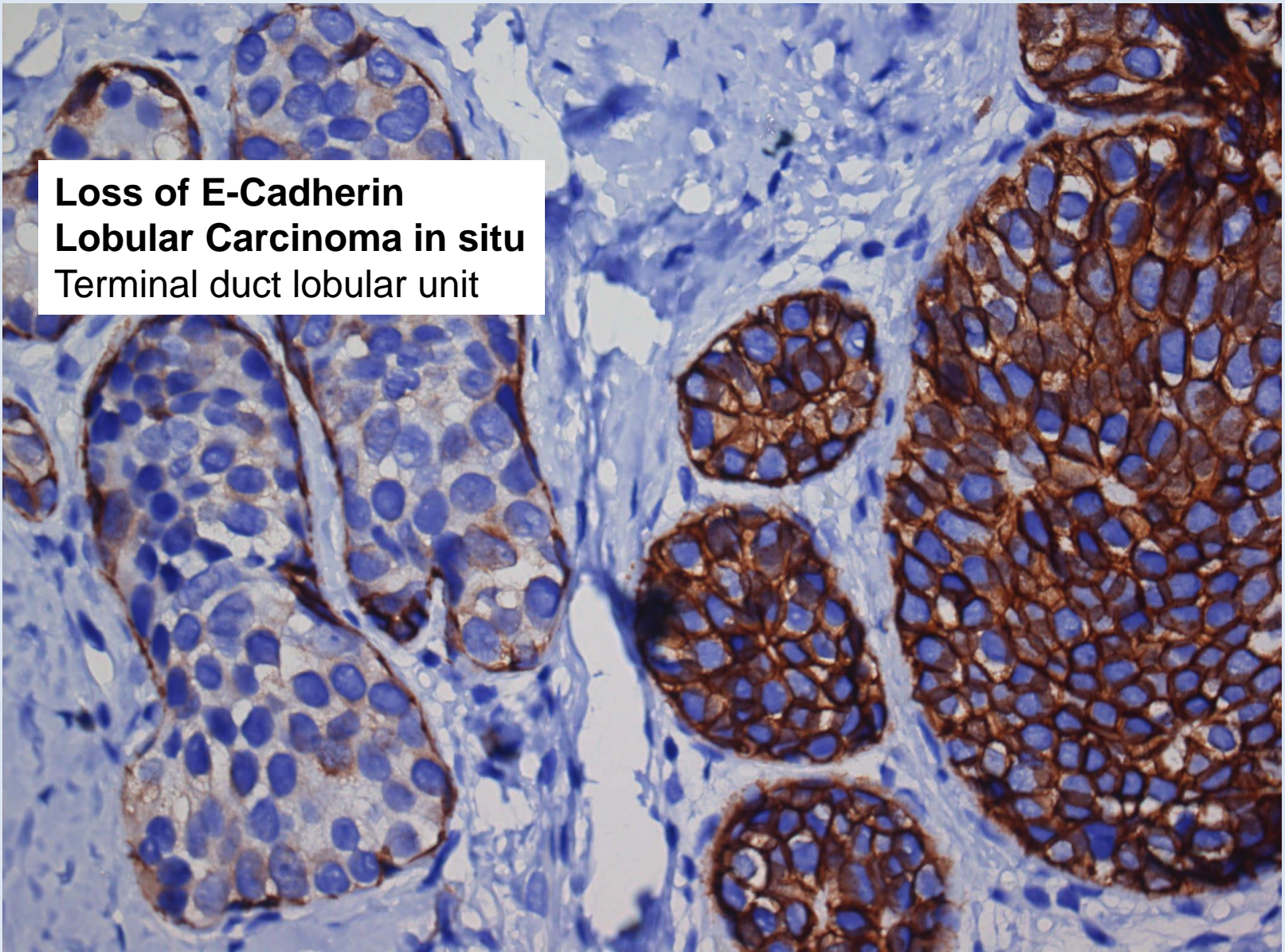
- Ductal carcinoma in situ
  - 12-15% of malignant lesions in the Danish screening population
  - Microcalcifications
  - Risk of progression to invasive carcinoma
  - Surgery with free margins (2 mm)
  - Radiation therapy after breast conserving surgery



- Lobular carcinoma in situ
  - Non obligate precursor
  - Incidence 0.5 – 3.6%
  - Often incidental finding
  - Multifocal and often bilateral
  - Slowly proliferating lesions
  - Observation / screening



**Loss of E-Cadherin**  
**Lobular Carcinoma in situ**  
Terminal duct lobular unit



**E-cadherin: Cell Adhesion Molecule**

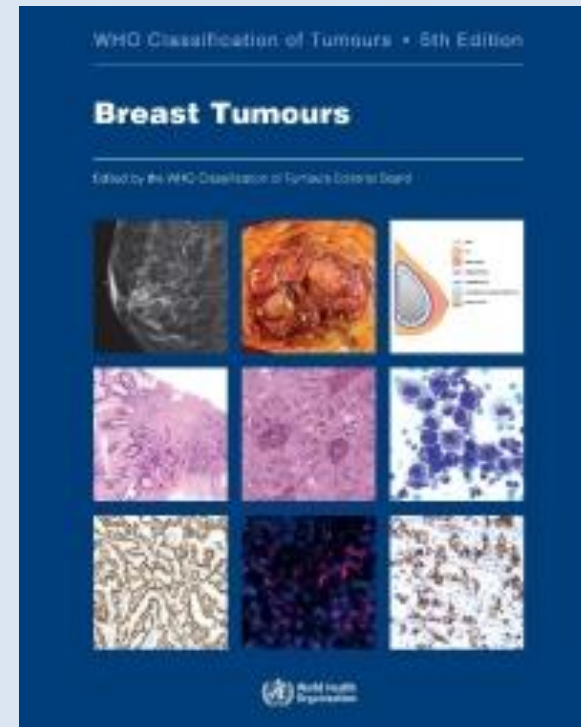

# Classification of malignant tumors of the breast

## WHO blue books

### Histological subtypes (>20)

- Ductal : up to 80%
- Lobular: 5 - 14%
- Tubular: 2 - 8%
- Mucinous: 2 - 4 %
- Apocrine: 1 – 4%
- Papillary 1 – 2%
- Other

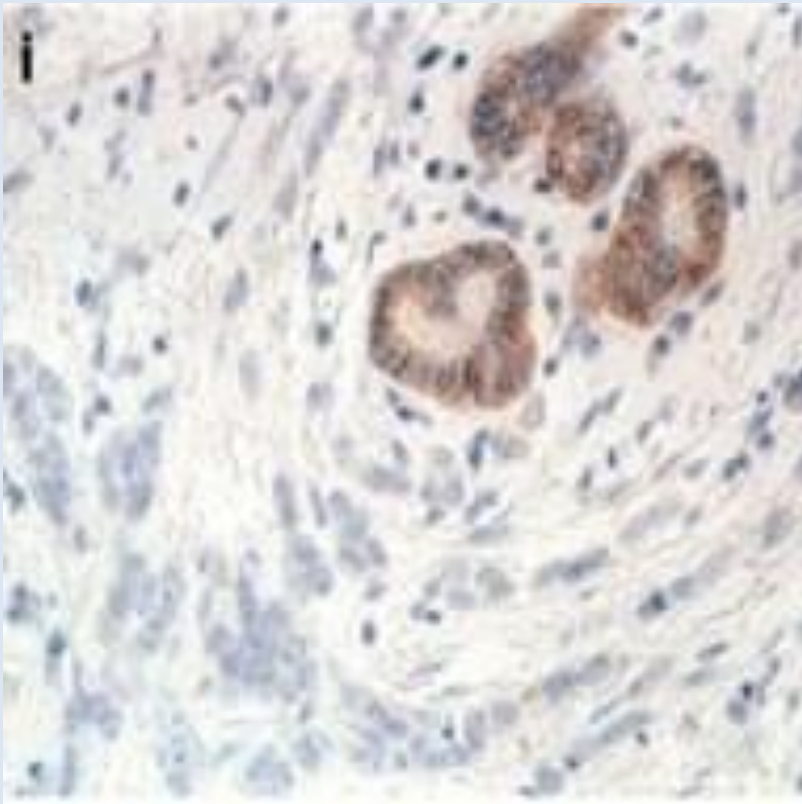




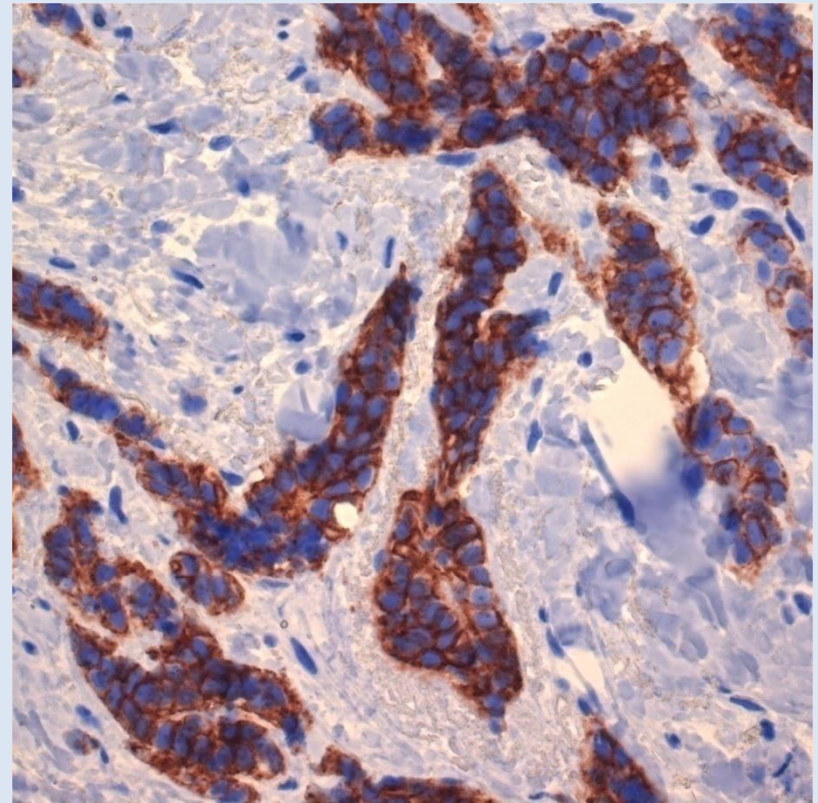
# E-Cadherin

## Cell adhesion molecule

**Loss of E-Cadherin in 90% of  
Invasive lobular Carcinoma**



**E-Cadherin positive  
Invasive Ductal Carcinoma**

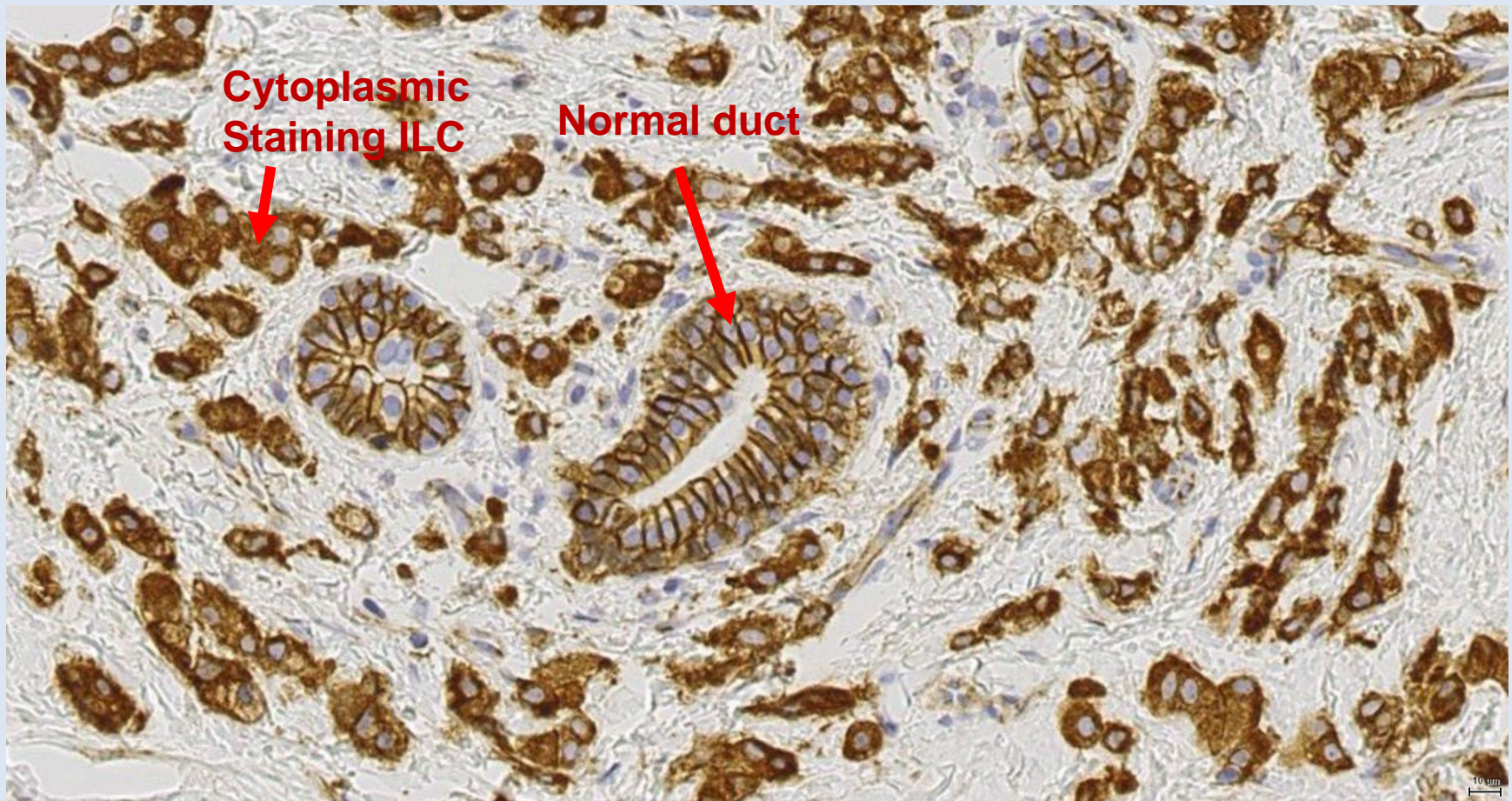


*CDH1* (16q22.1) loss of function mutation or deletion resulting in loss of the adhesion molecule E-cadherin



# P120 catenin dislocated to the cytoplasm in lobular carcinoma (ILC)

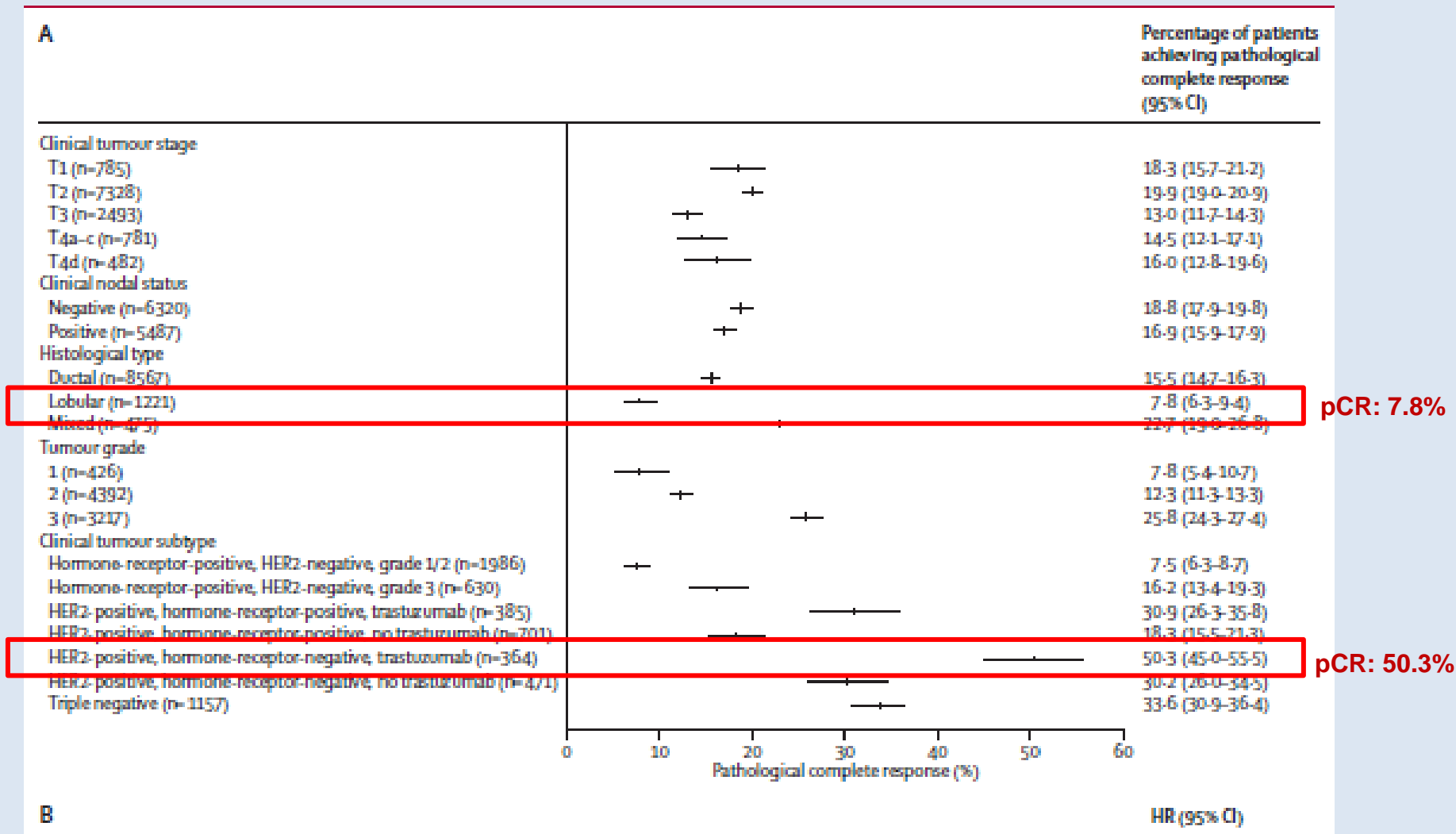
A supplement for classification of lobular neoplasia



Lobular cancer - not candidate for neoadjuvant chemotherapy  
Low proliferating tumors, often luminal A molecular subtype

# Tumor characteristics and association with pCR

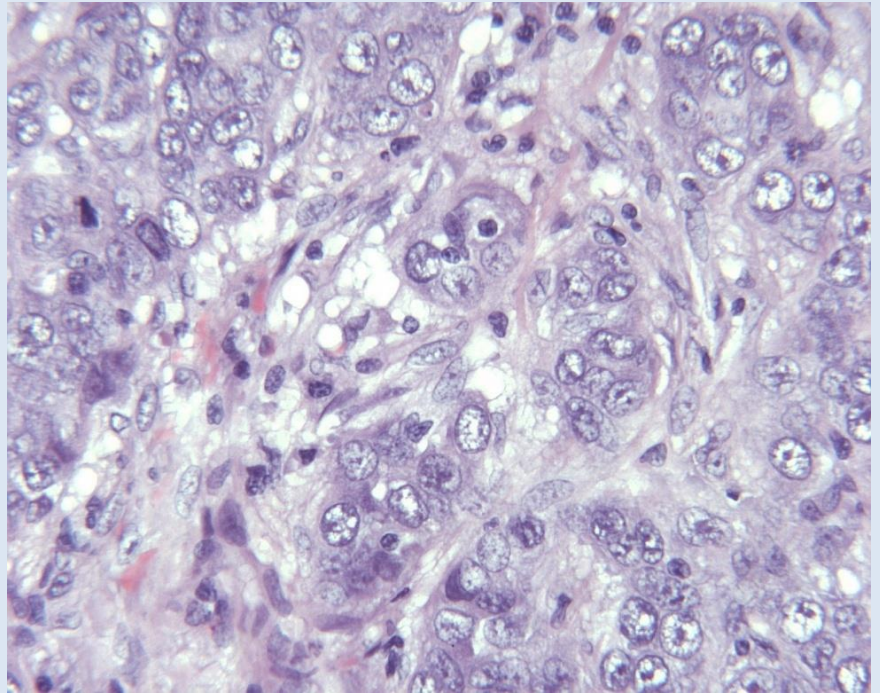
## Neoadjuvant chemotherapy (NACT)



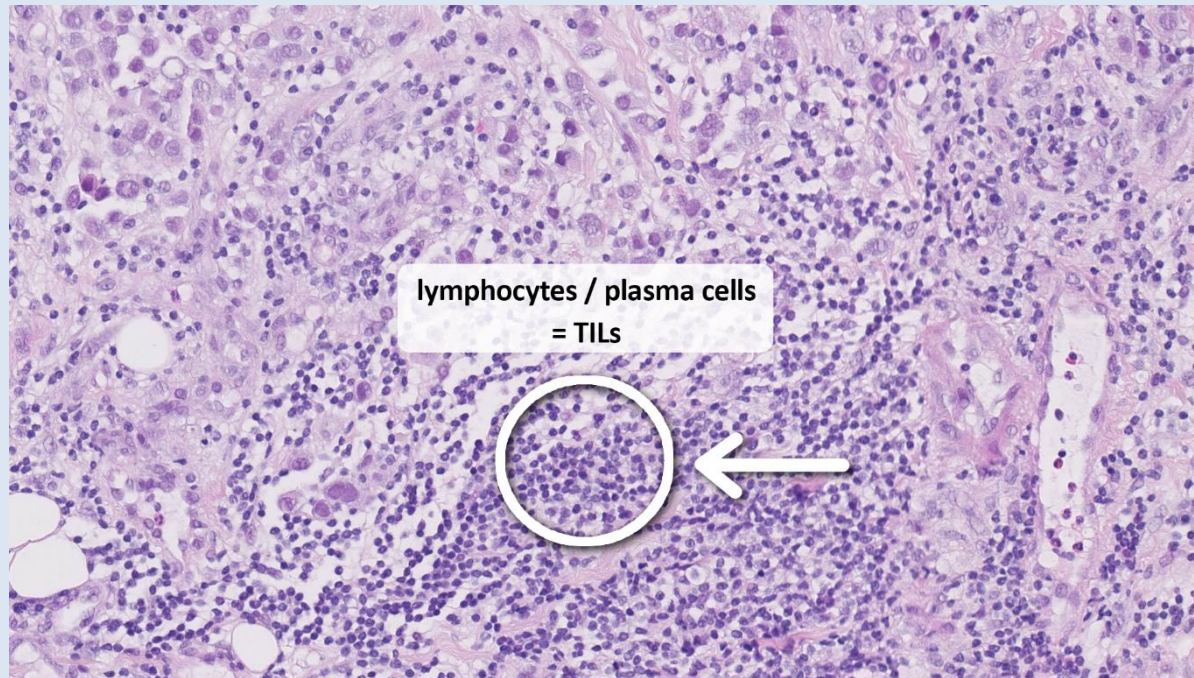


# TNBC : 8-10% of primary breast cancers

- ER, PR and HER2 negative
- Heterogeneous group of tumours
- High grade
- Younger age at diagnosis
- Poor prognosis
- Risk of *gBRCA* mutation



# Tumor infiltrating lymphocytes and TNBC



TNBC is considered to be the most immunogenic breast cancer subtype, with a higher median number of tumor-infiltrating lymphocytes (TILs), PD-L1 expression, both markers associated with tumor microenvironment (TME) immune activity.

Level 1B evidence / prognostic marker

Loi, S., et al., *Tumor-Infiltrating Lymphocytes and Prognosis: A Pooled Individual Patient Analysis of Early-Stage Triple-Negative Breast Cancers*. J Clin Oncol, 2019. **37**(7): p. 559-569.



# Triple-Negative Breast Cancer Histological Subtypes with a Favourable Prognosis

The majority of TNBC are invasive ductal carcinomas (IDC) – Figure 1  
Rare special histological subtypes are low proliferative tumours with good prognosis although being triple negative (Figure 2 and 3).

Cserni G et al. Cancers 2021, PMID: 34830849

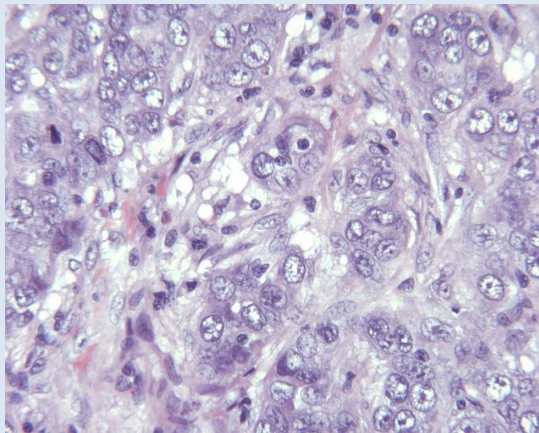


Figure 1  
High grade IDC

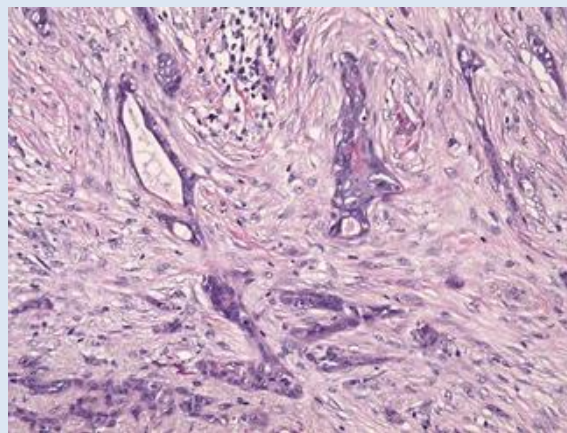


Figure 2  
Low grade adenosquamous carcinoma (subtype of metaplastic carcinoma)  
luminal (CK7, CK8) and basal (CK5, CK14) CKs and squamous (myoepithelial) markers p63 and p40.

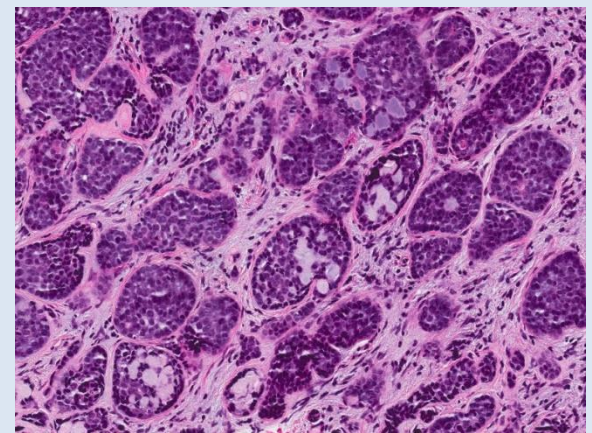
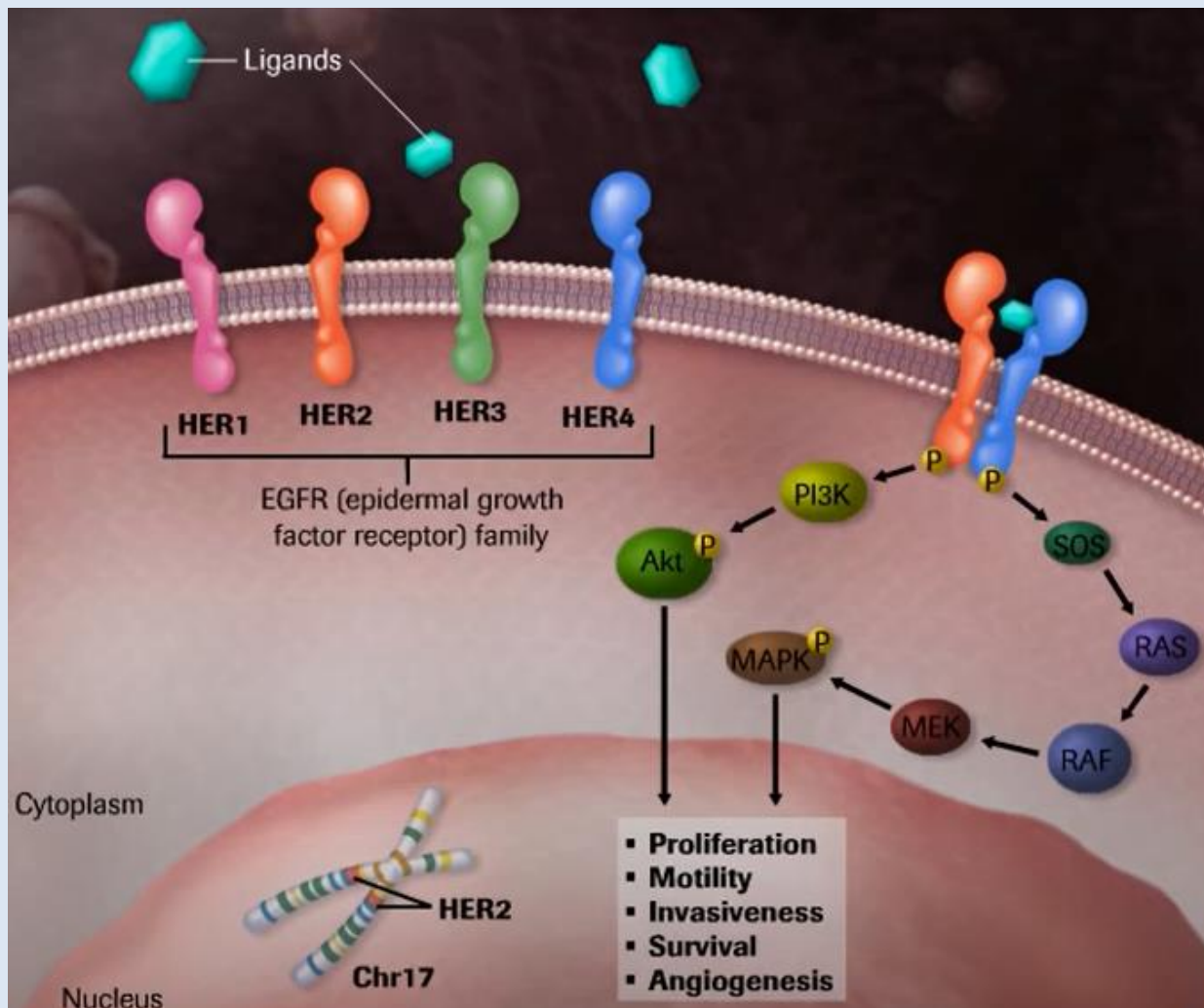


Figure 3  
Adenoid cystic carcinoma of the breast. The cells of the epithelial component are positive for CK7, CK5/6, CK 8/18 and CD117. The myoepithelial /abluminal cells express p63, smooth muscle actin and basal CKs: CK5/6, CK14, CK17.



# Prognostic and predictive biomarkers

The HER2 gene is located on 17q21. and encodes the human epidermal growth factor receptor 2 (HER2), a transmembrane tyrosine kinase receptor



# ASCO CAP guidelines

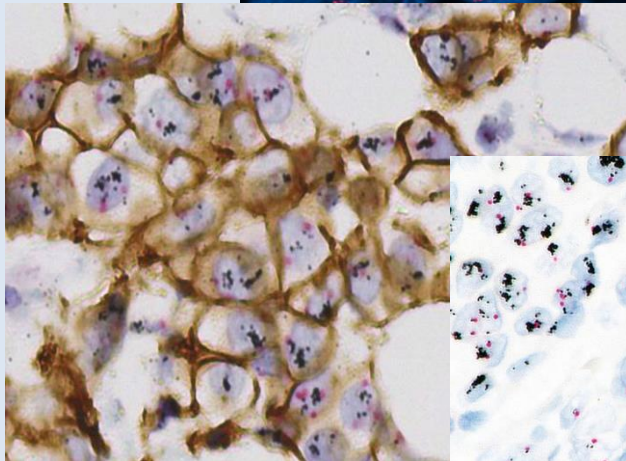
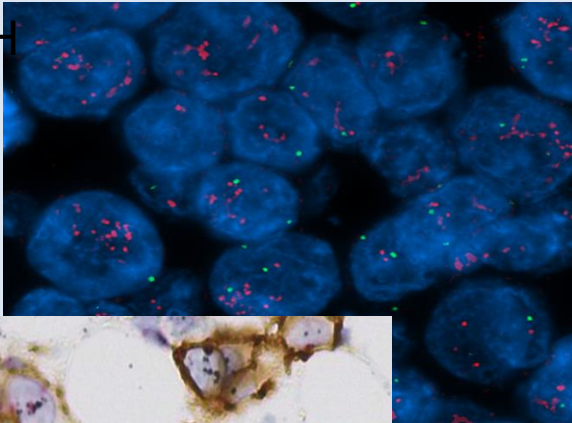
## 2007, 2013, 2018

HER2 SCORE	ASCO/CAP 2007	ASCO/CAP 2013	ASCO/CAP 2018
<b>0</b>	No staining	No staining or $\leq 10\%$ of tumor cells with incomplete, faint or barely perceptible staining.	No staining or $\leq 10\%$ of tumor cells with incomplete, faint or barely perceptible staining.
<b>1+</b>	Weak, incomplete membrane staining in any proportion of tumor cells.	$>10\%$ of tumor cells with incomplete, faint membrane staining.	$>10\%$ of tumor cells with incomplete, faint membrane staining.
<b>2+ (equivocal)</b>	$>10\%$ of tumor cells with non-uniform or weak, circumferential staining or intense membranous staining in $\leq 30\%$ of tumor cells.	$>10\%$ of tumor cells with circumferential, incomplete and/or weak to moderate membranous staining or $\leq 10\%$ of tumor cells with circumferential, intense membranous staining.	$>10\%$ of tumor cells with complete, membranous staining.
<b>3+</b>	$>30\%$ of tumor cells with uniform, intense membranous staining.	$>10\%$ of tumor cells with circumferential, intense membranous staining.	$>10\%$ of tumor cells with circumferential, intense membranous staining.

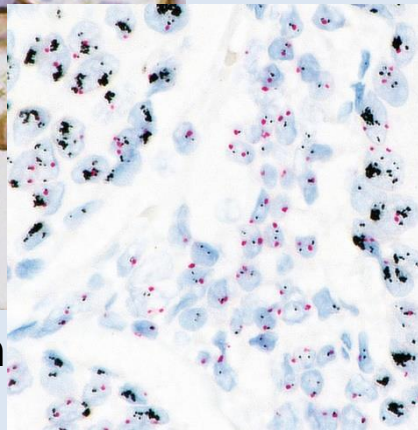


# HER2 interpretation BC

FISH

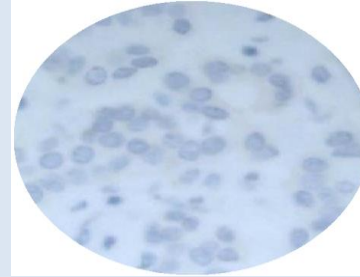


HER2 Gene/Protein

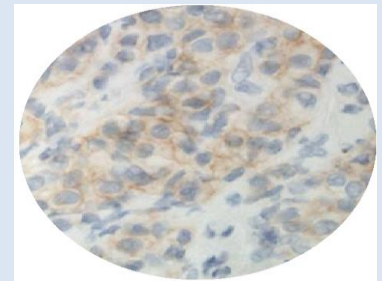


Dual ISH

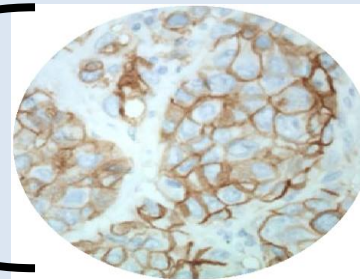
0



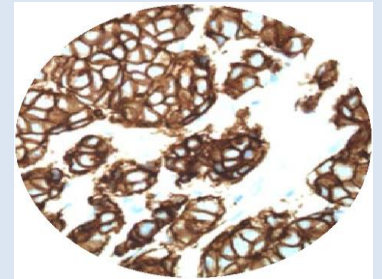
1+



2+



3+



ASCO CAP guidelines 2018  
<https://pubmed.ncbi.nlm.nih.gov/29846122/>

N Engl J Med. 2022 PMID: 35665782

# HER2-low in mBC

## DESTINY-Breast04: First Randomized Phase 3 Study of T-DXd for HER2-low mBC

An open-label, multicenter study (NCT03734029)

### Patients<sup>a</sup>

- HER2-low (IHC 1+ vs IHC 2+/ISH-), unresectable, and/or mBC treated with 1-2 prior lines of chemotherapy in the metastatic setting
- HR+ disease considered endocrine refractory

### Stratification factors

- Centrally assessed HER2 status<sup>d</sup> (IHC 1+ vs IHC 2+/ISH-)
- 1 versus 2 prior lines of chemotherapy
- HR+ (with vs without prior treatment with CDK4/6 inhibitor) versus HR-

R  
2:1

**T-DXd**  
5.4 mg/kg Q3W  
(n = 373)

HR+ ≈ 480  
HR- ≈ 60

**TPC**  
Capecitabine, eribulin,  
gemcitabine, paclitaxel,  
nab-paclitaxel<sup>c</sup>  
(n = 184)

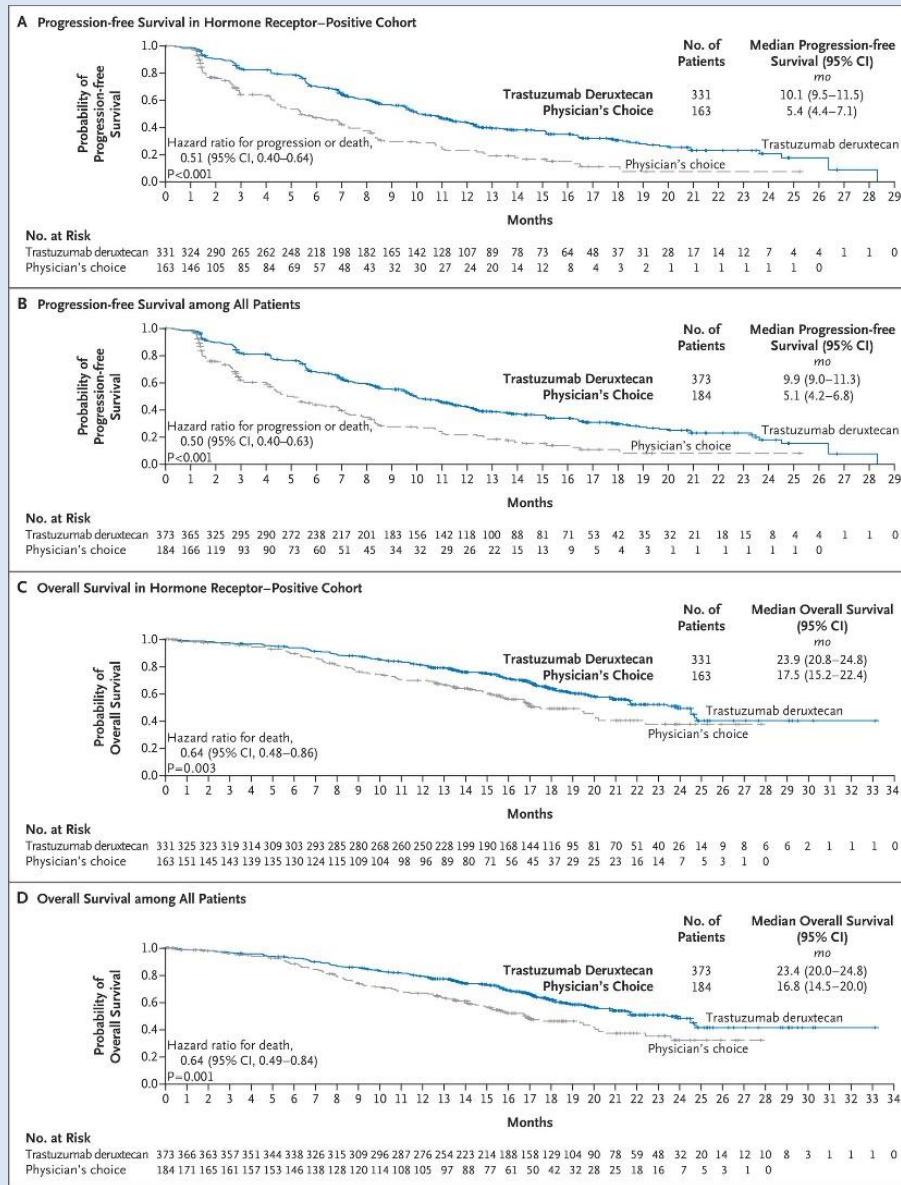
### Primary endpoint

- PFS by BICR (HR+)

### Key secondary endpoints<sup>b</sup>

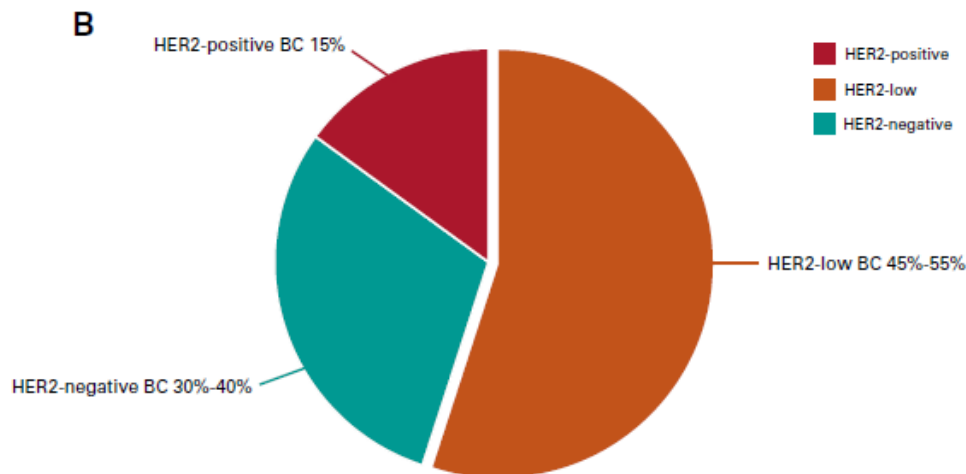
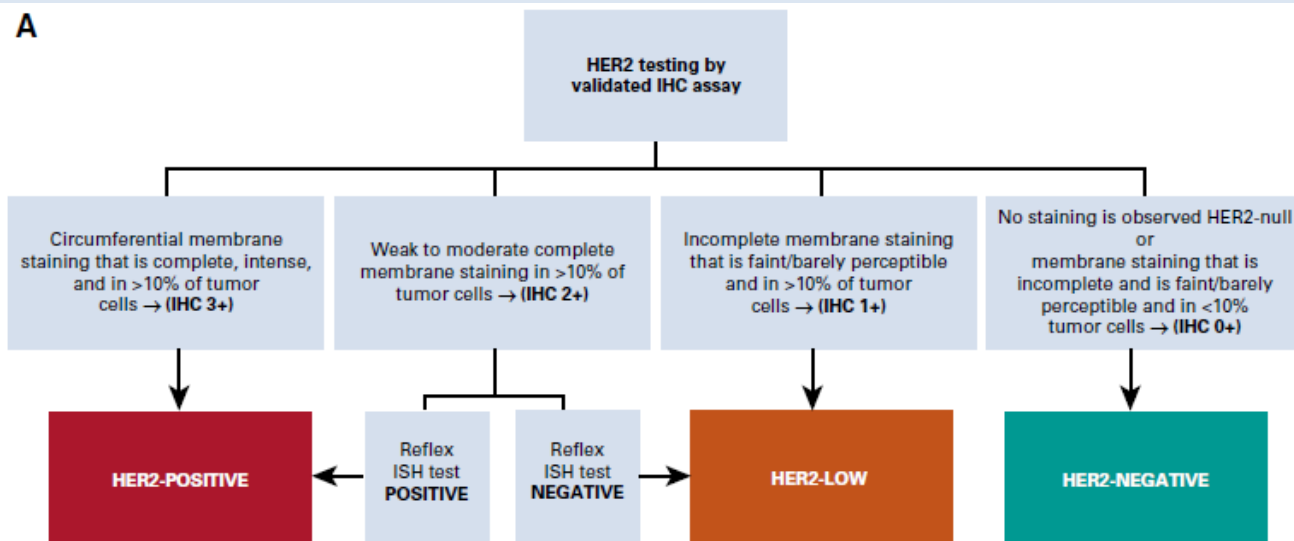
- PFS by BICR (all patients)
- OS (HR+ and all patients)

# Trastuzumab Deruxtecan in Previously Treated HER2-Low Advanced Breast Cancer





# Definition of HER2 Low



**Ultra-Low:**  
**HER2>0% and**  
**≤ 10%**  
**Destiny Breast**  
**06**

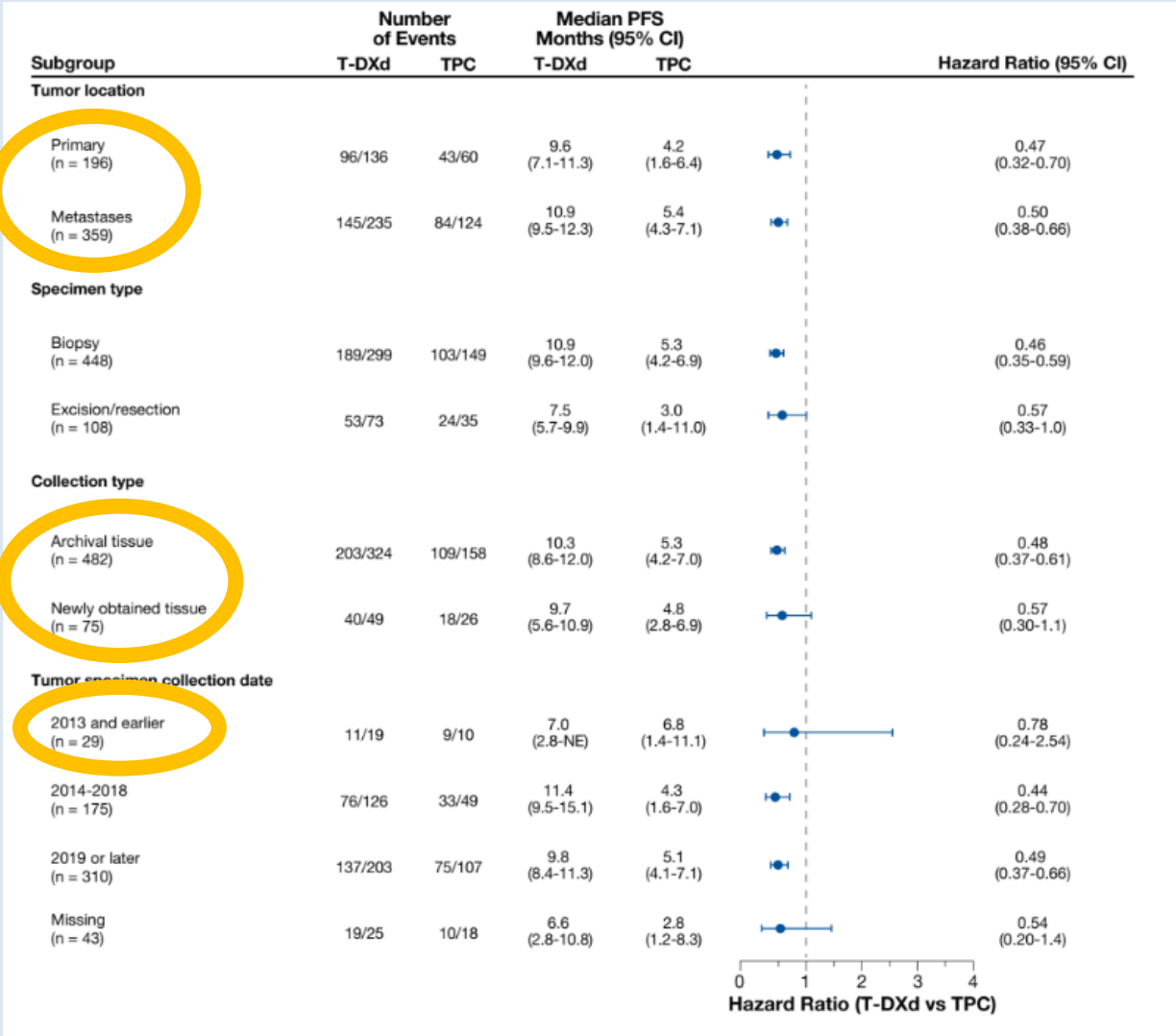
Tarantino et  
al.  
JCO, 2020  
[https://doi.org/  
10.  
1200/JCO.19.  
02488](https://doi.org/10.1200/JCO.19.02488)

# Tumor sample characteristics Destiny Breast04

35% primary tumors,  
65% metastatic lesions  
10% new biopsy

For patients enrolled  
in DESTINY-Breast 04,  
efficacy of T-DXd compared  
with TPC was consistent  
regardless of tumor sample  
characteristics

Cancer Res (2023) 83 (5\_Supplement)



# Assay sensitivity

Comparison of HercepTest™ mAb pharmDx (Dako Omnis, GE001)  
with Ventana PATHWAY anti-HER-2/neu (4B5) in breast cancer:  
correlation with *HER2* amplification and HER2 low status

Josef Rüschoff<sup>1</sup> · Michael Friedrich<sup>1</sup> · Iris Nagelmeier<sup>2</sup> · Matthias Kirchner<sup>2</sup> · Lena M. Andresen<sup>3</sup> · Karin Salomon<sup>3</sup> ·  
Bryce Portier<sup>4</sup> · Simone T. Sredni<sup>4</sup> · Hans Ulrich Schildhaus<sup>1,2</sup> · Bharat Jasani<sup>1</sup> · Marius Grzelinski<sup>1</sup> · Giuseppe Viale<sup>5</sup>

		PATHWAY 4B5				
		0	1+	2+	3+	Total
HercepTest (mAb)	0	35	0	0	0	35
	1+	17	8	0	0	25
	2+	4	* 12	13	1	30
	3+	0	0	2	27	29
	Total	56	20	15	28	119

	% cases categorised as HER2-Low (n=119 cases)
HercepTest	35%
4B5	19%

\* 2 amplified

Rueschoff J, et al. Virchows Arch 2022



# Summary: HER2-Low BC

- Common and usually found in HR-positive disease
- At present, main role is to predict response to ADC (T-DXd) in mBC
- Variable assay sensitivity, concordance, spatial and temporal heterogeneity for HER2-Low category with existing assays
- Ongoing trials expected to determine the lower threshold of HER2 expression required for benefit from T-DXd based on existing assays
- Newer quantitative technologies e.g. quantitative IF, RT-qPCR; digital imaging and machine learning may be more accurate and predictive value will have to be determined
- For now, use of existing assays (and scoring system) is advised with focussed training on the full spectrum of low HER2 expression

# 2023 ESMO Consensus

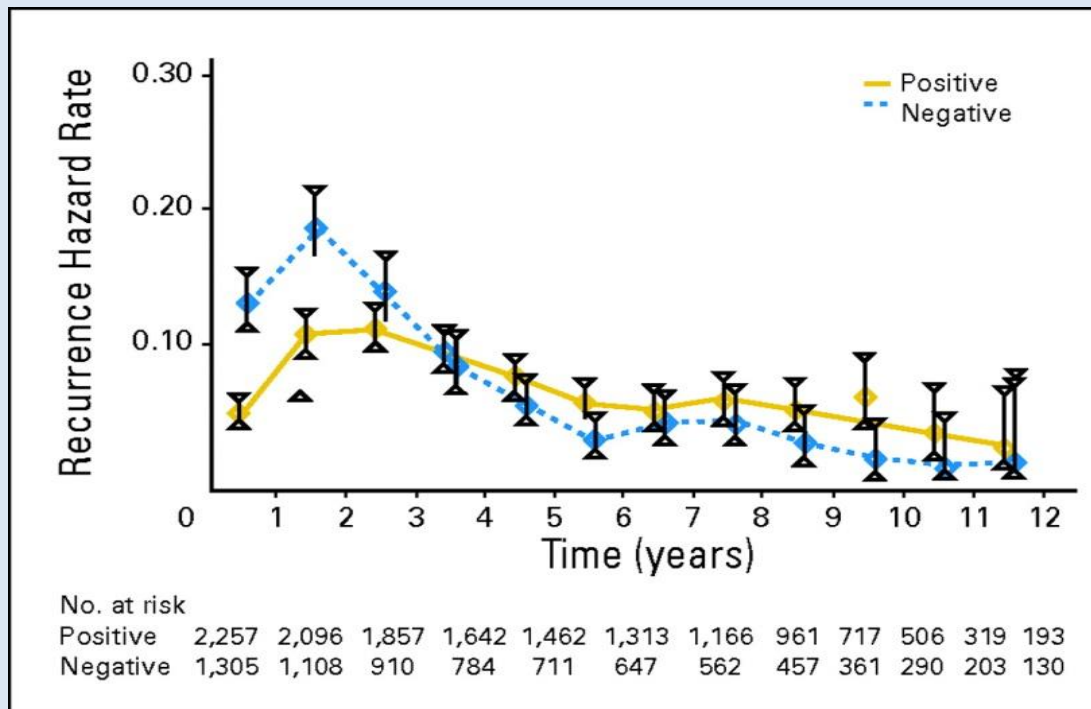
**Table 1.** Interpretation by the ASCO/CAP 2018 Guidelines and by the 2023 ESMO Consensus on HER2-low breast cancer regarding each pattern of HER2 staining

Description of staining	Denomination by 2018 ASCO/CAP Guidelines	Conclusion by 2018 ASCO/CAP Guidelines	Conclusion by 2023 ESMO clinical practice recommendations
- No staining - Incomplete or faint staining in $\leq 10\%$ of invasive tumor cells	HER2-0 HER2-0	HER2-negative HER2-negative	HER2-0 <i>HER2-null<sup>a</sup></i> <i>HER2-ultralow (or &gt;no staining &lt;1+)<sup>a</sup></i>
- Incomplete or faint staining in $>10\%$ of invasive tumor cells	HER2 1+	HER2-negative	HER2-low
- Weak to moderate complete membrane staining in $>10\%$ of invasive tumor cells (ISH-negative)	HER2 2+ nonamplified	HER2-negative	HER2-low
- Weak to moderate complete membrane staining in $>10\%$ of invasive tumor cells (ISH-positive)	HER2 2+ amplified	HER2-positive	HER2-positive
- Intense complete membrane staining in $>10\%$ of invasive tumor cells	HER2 3+	HER2-positive	HER2-positive

<https://doi.org/10.1016/j.annonc.2023.05.008>

# The Estrogen receptor as a prognostic/predictive marker

Risk of recurrence pr. year  
N = 3,562 patients

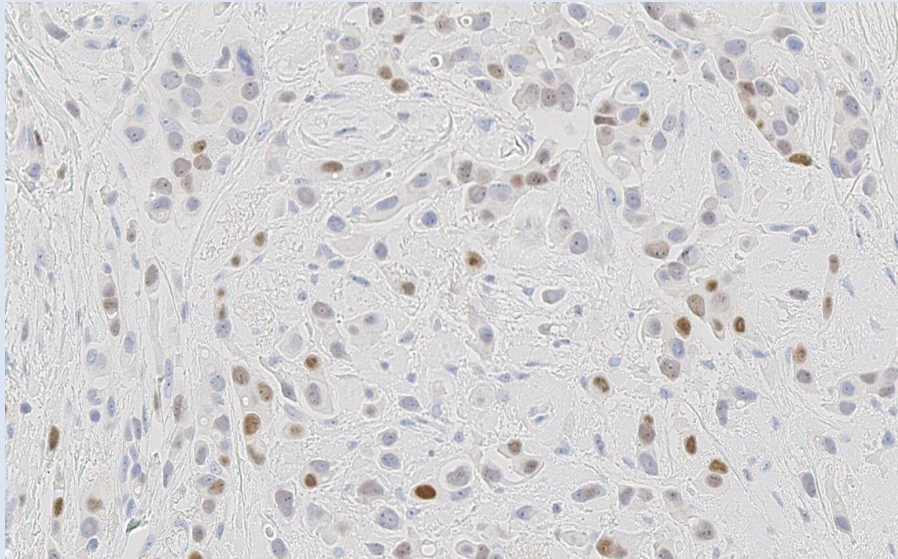


Lin, N. U. et al. J Clin Oncol; 26:798-805 2008



# 2020 – ASCO CAP Update

## Hormone receptors

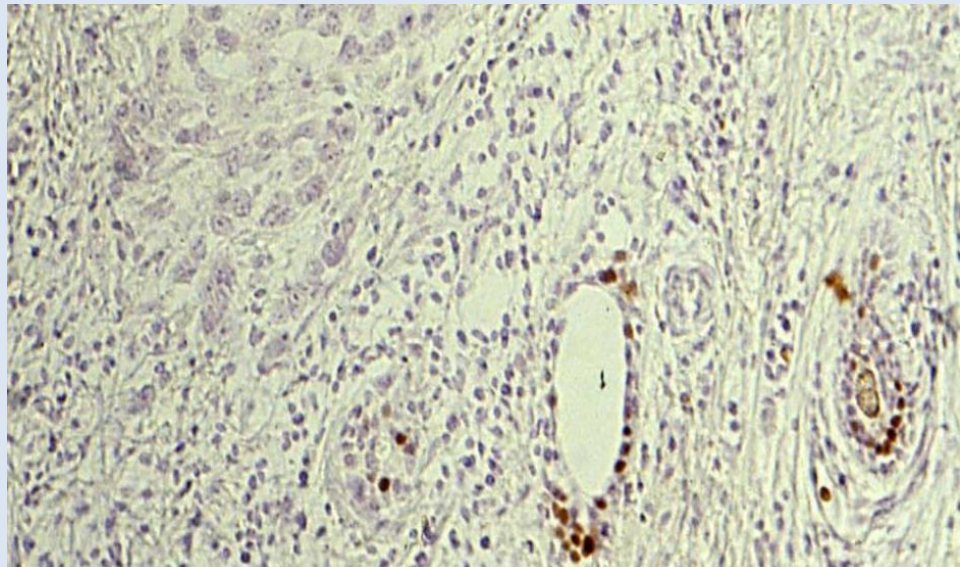
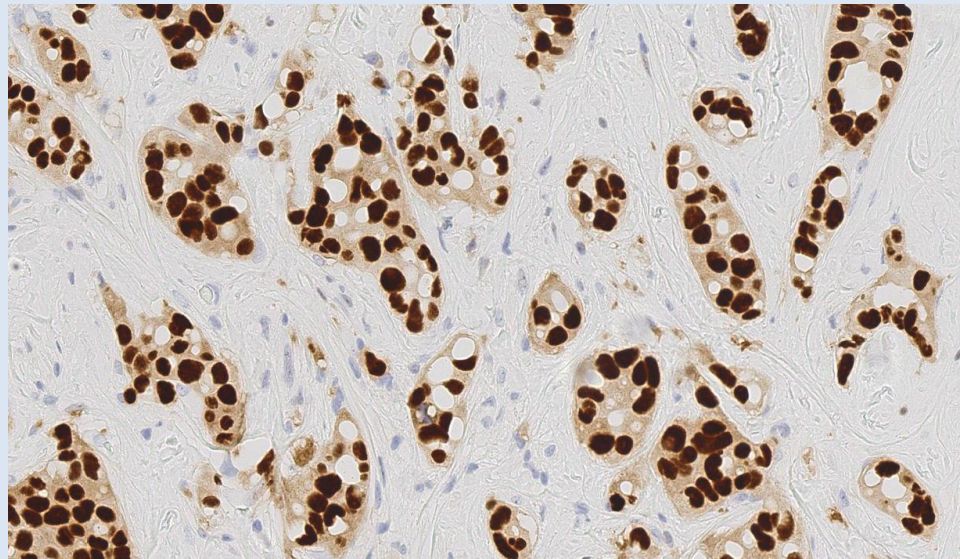


ER positive 86% of breast carcinomas (DK)

Cut off  $\geq 1\%$

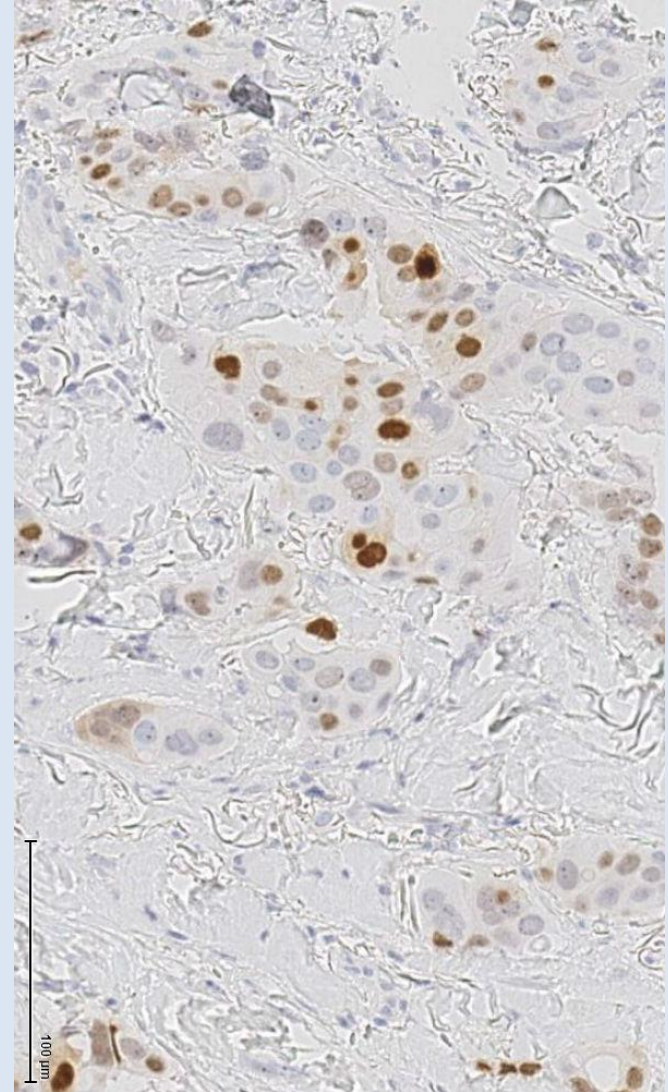
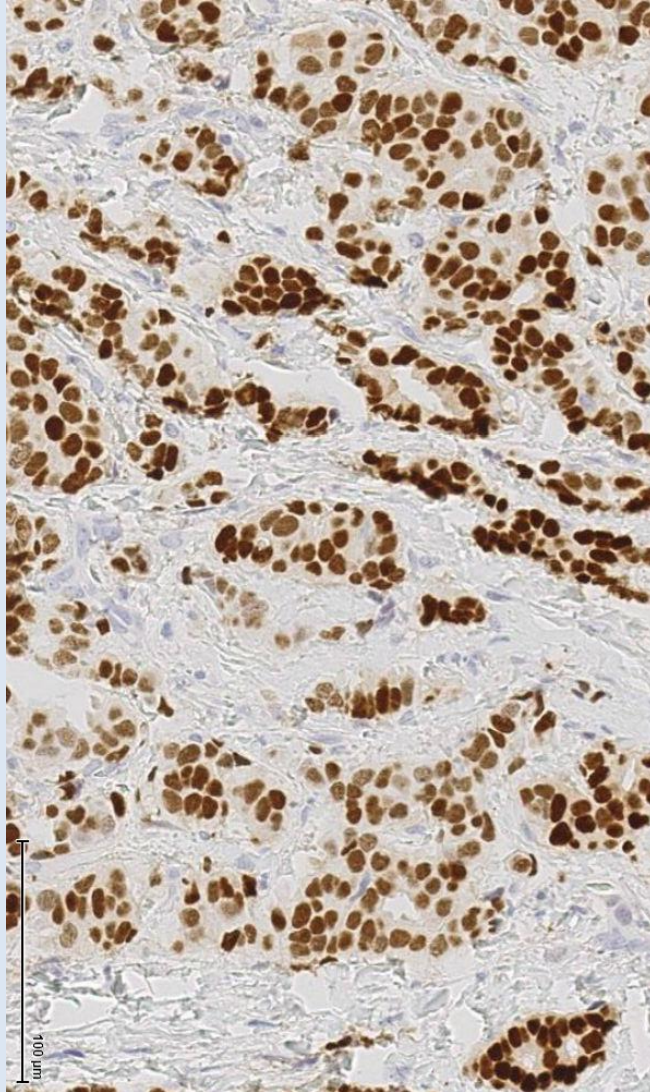
A sample is reported negative for ER or PgR if  $< 1\%$  or 0% of tumor cell nuclei are immunoreactive.

Limited data on the overall benefit of endocrine therapies for patients with low level (1-10%) ER expression.





# Interpretation of PgR

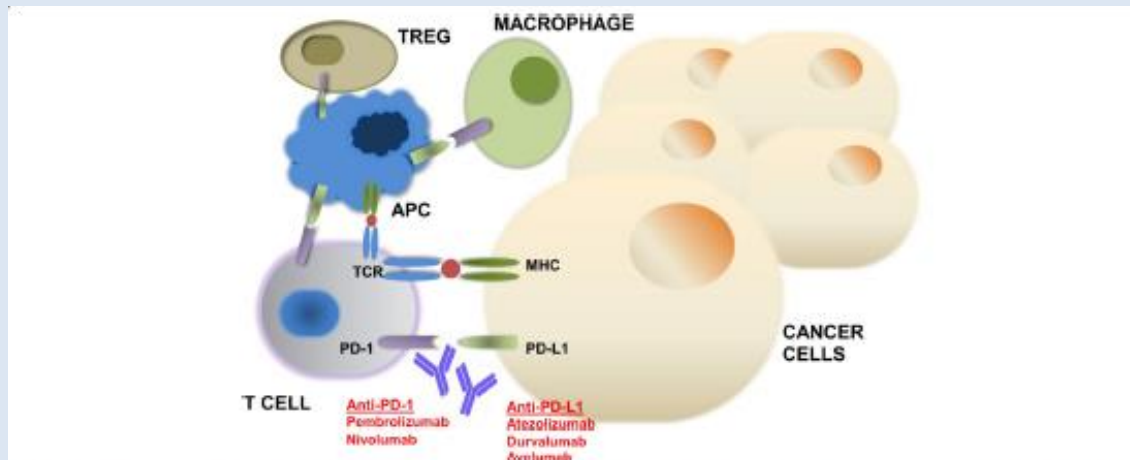


Heterogeneous expression

# PD-L1 in TNBC

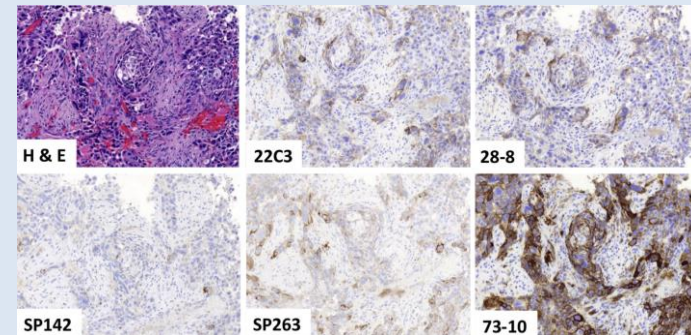


# Mechanism of action of PD-1 and PD-L1 inhibitors



Binding of PD-1 to its ligand PD-L1 results in suppression of proliferation and immune response of T cells. Activation of PD-1/PD-L1 signaling serves as a principal mechanism by which tumors evade antigen-specific T-cell immunologic responses. Antibody blockade of PD-1 or PD-L1 reverses the process and enhances antitumor immune activity

PD-L1 is expressed on lymphocytes, macrophages, fibroblasts, tumour cells.



# PD-L1 scoring system

Which scoring system should be used for PD-L1 staining?

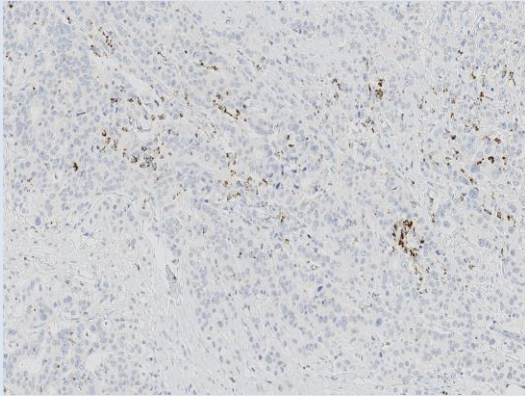
	IVD diagnostic antibodies used in clinical trials	
Drug	Pembro- lizumab (MSD)	Atezo- lizumab (Roche)
AB clone	22C3 Dako	SP-142 Ventana
Score	CPS	IC <sub>A</sub>
cell type	Tumor Immune	Immune
Breast cancer trial	KN-012 KN-522	Impassion -130

**IC<sub>A</sub> score:** percentage of tumor area covered by PD-L1 positive immune cells (designed for Atezolizumab)

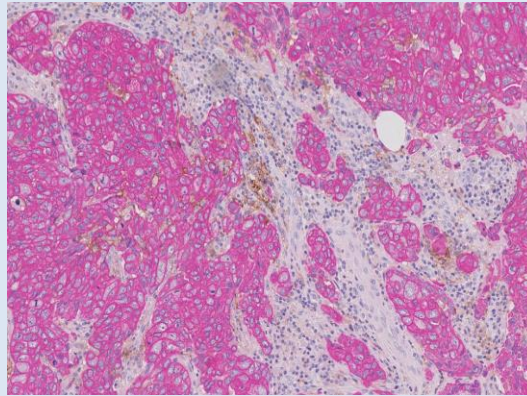
**CPS score:** positive tumor or immune cells as percentage of all tumor cells (designed for Pembrolizumab)



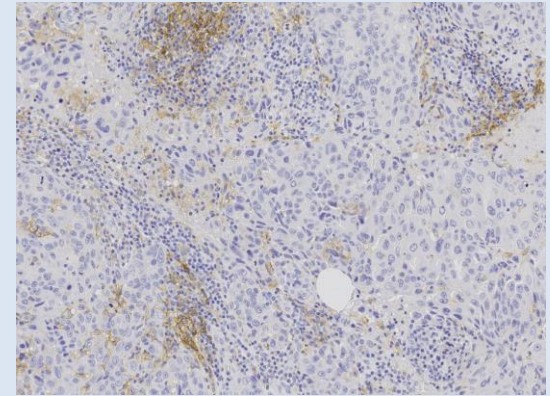
# PD-L1 immunohistochemistry



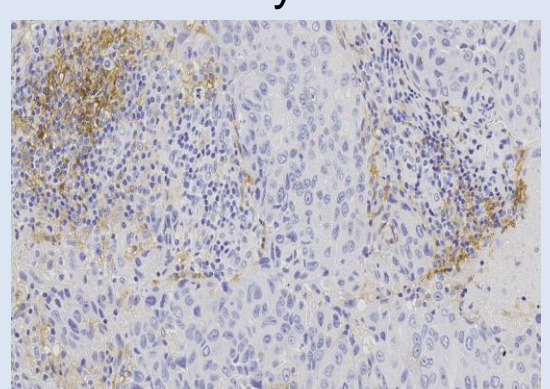
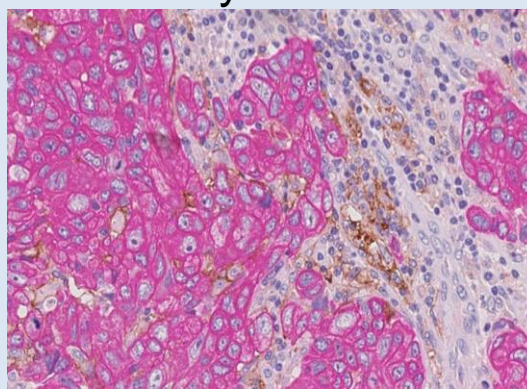
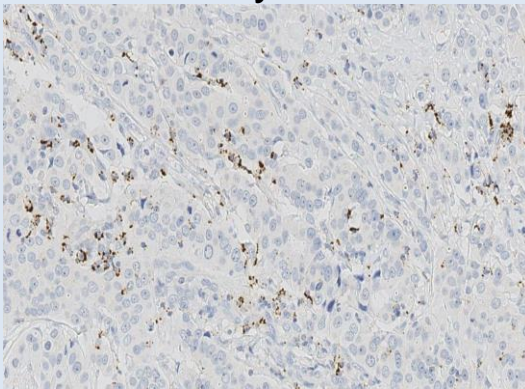
Assay SP142



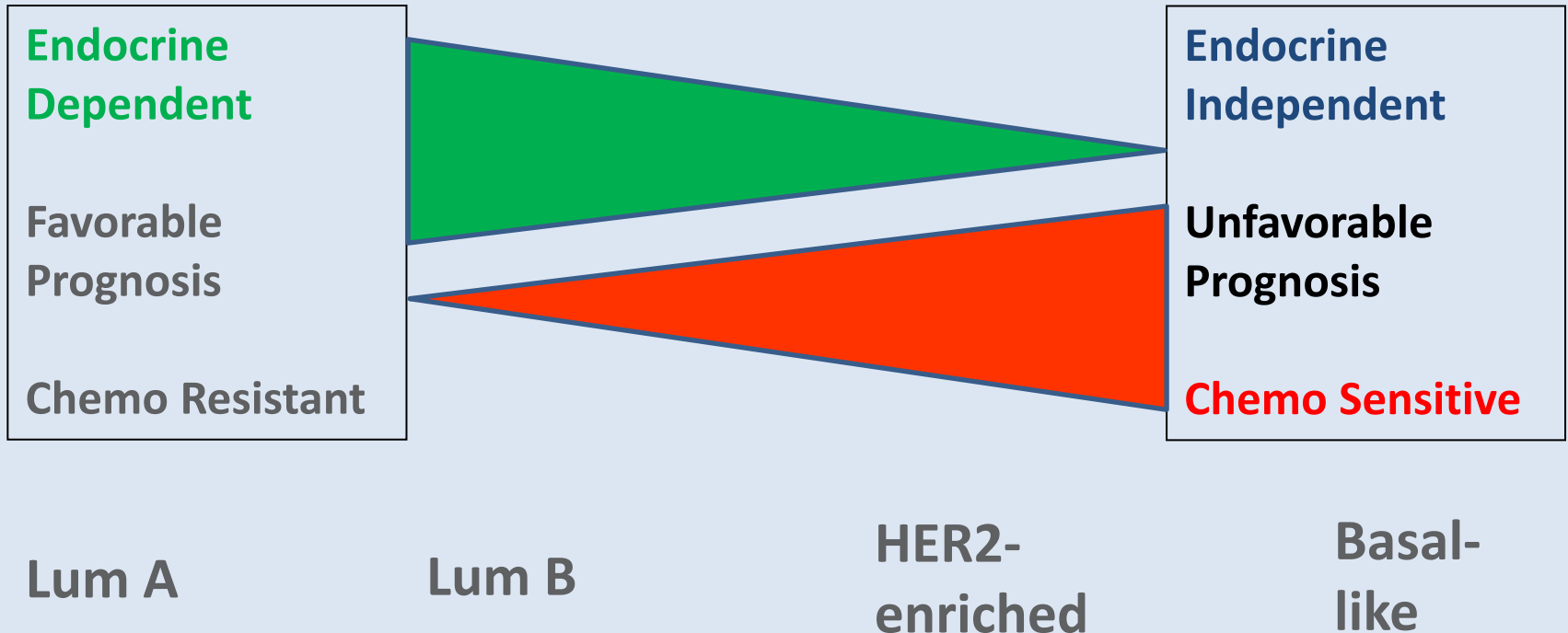
Assay 22C3+CK8



Assay 22C3



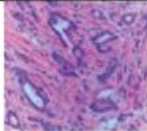
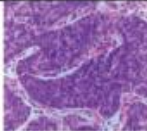
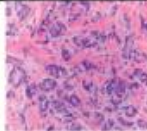
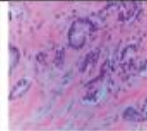
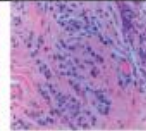
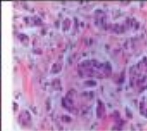
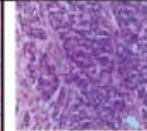
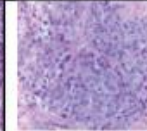

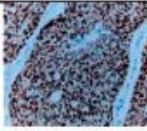

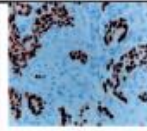
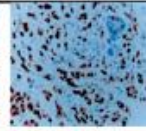
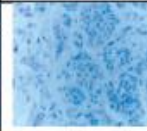
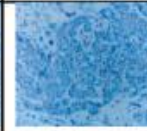

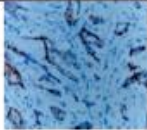


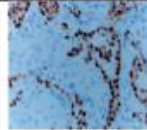




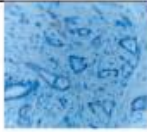


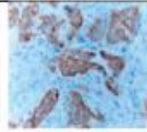
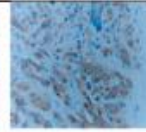
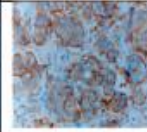


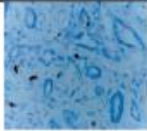




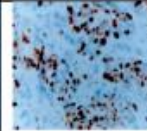

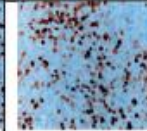



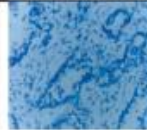
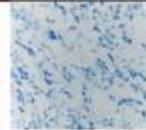
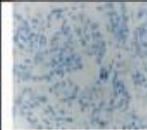
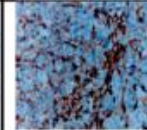





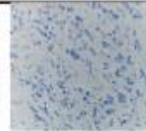
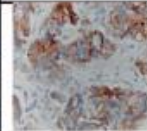


# Breast cancer – Molecular intrinsic subtypes prognostic information





# Immunohistochemical surrogate markers for the molecular intrinsic subtypes

Arch Pathol Lab Med—Vol 140, August 2016

Stains	Luminal BC			HER2 Positive BC			TNBC	
	Luminal A Subtype	Luminal B Subtype (Ki67 $\geq$ 14%)	Luminal B Subtype (PR<20%)	Luminal HER2 PR $\geq$ 1%	Luminal HER2 PR (<1%)	HER2 Enriched	Basal-like subtype	Non-classified subtype
H&E								
ER								
PR								
HER2								
Ki-67								
CK5								
EGFR								

## COMMENTARY

## Assessment of Ki67 in Breast Cancer: Recommendations from the International Ki67 in Breast Cancer Working Group

Mitch Dowsett, Torsten O. Nielsen, Roger A'Hern, John Bartlett, R. Charles Coombes, Jack Cuzick, Matthew Ellis, N. Lynn Henry, Judith C. Hugh, Tracy Lively, Lisa McShane, Soon Paik, Frederique Penault-Llorca, Ljudmila Prudkin, Meredith Regan, Janine Salter, Christos Sotiriou, Ian E. Smith, Giuseppe Viale, Jo Anne Zujewski, Daniel F. Hayes

OXFORD

*JNCI J Natl Cancer Inst* (2021) 113(7): djaa201

doi: 10.1093/jnci/djaa201

First published online December 28, 2020

Commentary

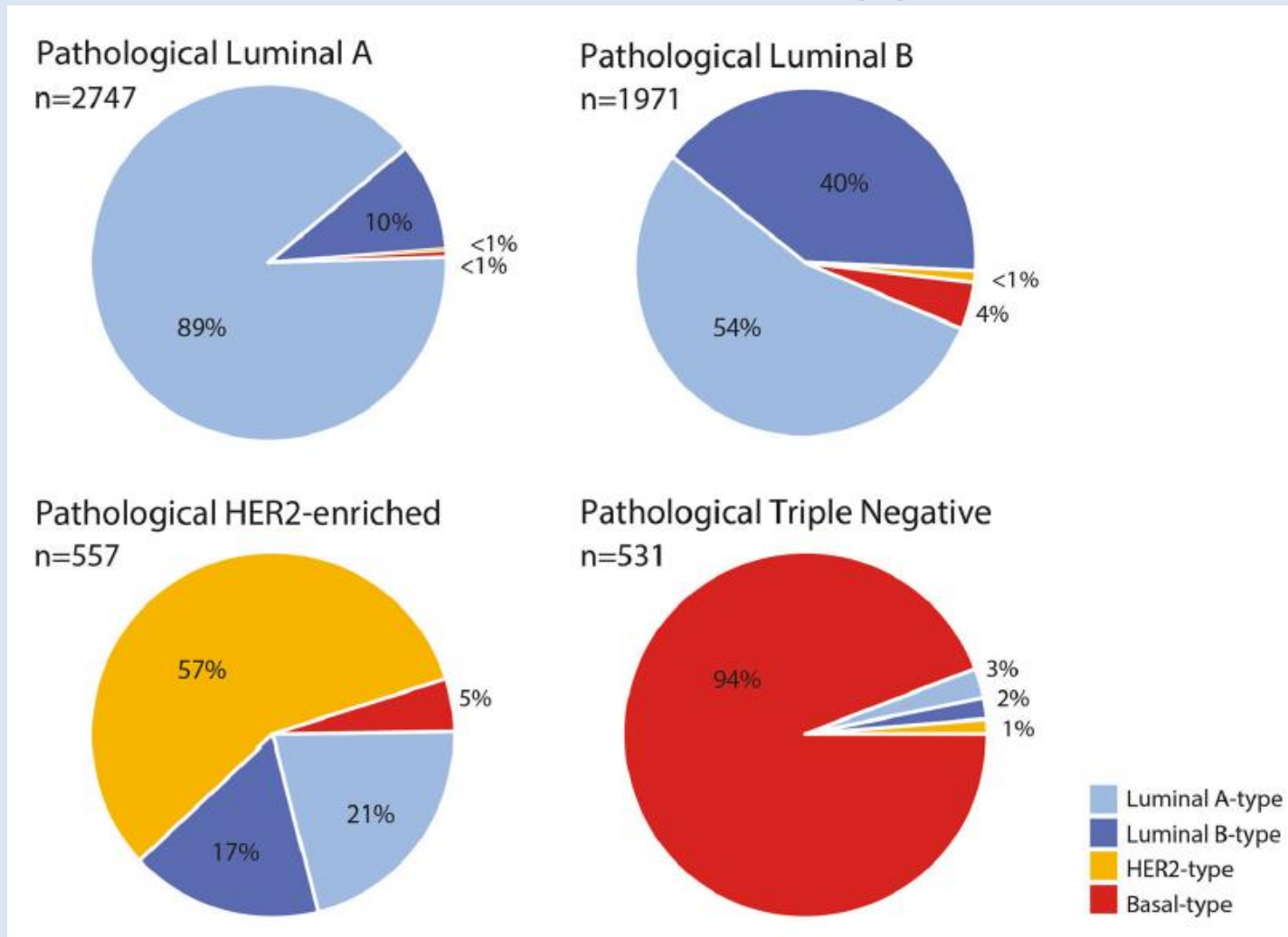
## Assessment of Ki67 in Breast Cancer: Updated Recommendations From the International Ki67 in Breast Cancer Working Group

Torsten O. Nielsen , MD, PhD, FRCPC,<sup>1,\*</sup> Samuel C. Y. Leung , MSc,<sup>1</sup> David L. Rimm , MD, PhD,<sup>2</sup> Andrew Dodson , MPhil, FIBMS, CSci,<sup>3</sup> Balazs Acs , MD, PhD,<sup>4,5</sup> Sunil Badve , MBBS, MD, FRCPath,<sup>6</sup> Carsten Denkert , MD,<sup>7</sup> Matthew J. Ellis , MB, BChir, BSc, PhD, FRCP,<sup>8</sup> Susan Fineberg , MD,<sup>9</sup> Margaret Flowers, PhD,<sup>10</sup> Hans H. Kreipe , MD,<sup>11</sup> Anne-Vibeke Laenkholm, MD,<sup>12</sup> Hongchao Pan , PhD,<sup>13</sup> Frédérique M. Penault-Llorca , MD, PhD,<sup>14</sup> Mei-Yin Polley , PhD,<sup>15</sup> Roberto Salgado, MD, PhD,<sup>16,17</sup> Ian E. Smith, MD, FRCP, FRCPE,<sup>18</sup> Tomoharu Sugie , MD, PhD,<sup>19</sup> John M. S. Bartlett , BSc, PhD, FRCPath,<sup>20,21</sup> Lisa M. McShane , PhD,<sup>22</sup> Mitch Dowsett , BSc, PhD<sup>23</sup>, Daniel F. Hayes MD<sup>24</sup>,

# Immunohistochemical surrogate markers for the molecular intrinsic subtypes

- Limitations
  - No uniform cut off value for Ki67
  - Lack of analytical validity – reproducibility
  - Lack of correlation between molecular subtypes and surrogate IHC subtypes
  - The international KI67 in Breast Cancer working group advice application of gene expression profile in case of KI67 >5% and <30%.

# Correlation between IHC subtype and molecular subtype





# Additional analyses

- Metastatic lesions
  - i.e. CK7, CK8/18 (if TNBC)
  - GCDFP
  - Mammaglobin
  - GATA-3 (obs, only app. 60% of TNBC positive)
  - TRPS-1 (higher positivity rate in TNBC)
  - ER
  - HER2 (re-analysis)
  - If indicated NGS panel
- Diagnostic additional biomarkers
  - Androgen Receptor (diagnostic for apocrine carcinoma – potential target for treatment in the metastatic setting)
  - Synaptophysin + other neuroendocrine markers (neuroendocrine differentiation – no treatment implication)

# In conclusion

## IHC for diagnostic use in breast tumors

- *A valuable supplement for the diagnosis of "benign versus in situ" and "in situ versus invasive"*
- *Histopathological classification of malignant breast tumors*
  - Treatment allocation (IDC vs ILC)
- *Prognostic and predictive factors*
  - Assay, interpretation and treatment
  - Repeat analysis on metastatic lesions
- *Intrinsic molecular subtype / gene expression profile*
  - Identification of patients who can be spared chemotherapy

