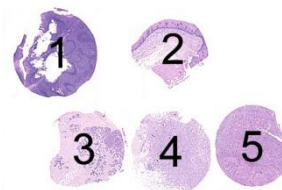


The slide to be stained for p63 comprised:

1. Tonsil, 2. Esophagus, 3. Breast hyperplasia, 4 – 5. Breast ductal carcinoma
All tissues were fixed in 10% neutral buffered formalin.



Criteria for assessing a p63 staining as optimal included:

- A moderate to strong, distinct nuclear staining in almost all the squamous epithelial cells in the tonsil and esophagus and an at least a weak nuclear reaction in scattered lymphocytes in the tonsil.
- A moderate to strong, distinct nuclear staining in the myoepithelial cells in the breast hyperplasia and in the remnants of the normal glands in the two breast ductal carcinomas.
- An at least weak to moderate nuclear staining in scattered neoplastic cells of the breast ductal carcinoma no. 5 in the multi tissue block (basal-like phenotype).
- No or only a weak cytoplasmic reaction (frequently seen in muscle cells).

110 laboratories participated in this assessment. 95 % achieved a sufficient mark. In table 1 the antibodies (Abs) and marks are summarized.

Table 1. **Abs and assessment marks for p63, run B8**

Concentrated Abs	N	Vendor	Optimal	Good	Borderl.	Poor	Suff. ¹	Suff. OPS ²
mAb clone 4A4	71 6	Dako NeoMarkers	37	39	1	0	99 %	98 %
mAb clone BC4A4	3	BioCare	0	2	1	0	-	-
mAb clone 7JUL	4	Novocastra	0	3	1	0	-	-
mAb clone cocktail 4A4+Y4A3	11	NeoMarkers	2	9	0	0	100 %	100 %
Not stated	3		0	2	1	0	-	-
Ready-To-Use Abs								
mAb clone 4A4, 760-4269, 463M-17	6 2	Ventana Cell Marque	2	6	0	0	100 %	100 %
mAb clone BC4A4, PM163AA	3	Biocare	1	1	1	0	-	-
mAb clone 4A4, ZM0406	1	Zhongshan Bio	0	1	0	0	-	-
Total	110		42	63	5	-	-	-
Proportion			38 %	57 %	5 %	-	95 %	-

1) Proportion of sufficient stains (optimal or good)

2) Proportion of sufficient stains with optimal protocol settings only, see below.

The following central protocol parameters were used to obtain an optimal staining:

Concentrated Abs

mAb clone **4A4**: The protocols giving an optimal result were all based on heat induced epitope retrieval (HIER) using either Tris-EDTA/EGTA pH 9 (9/19)*, Target Retrieval Solution pH 9 (EnVision FLEX TRS high pH, Dako), (19/24), Cell Conditioning 1 (BenchMark, Ventana) (7/20) or Citrate pH 6 (2/9) as HIER buffer. The mAb was typically diluted in the range of 1:50– 1:500 depending on the total sensitivity of the protocol employed. With these protocol settings 63 out of 64 (98 %) laboratories produced a sufficient staining (optimal or good).

* (number of optimal results/number of laboratories using this buffer)

mAb clone cocktail **4A4+Y4A3**: The protocols giving an optimal result were all based on heat induced epitope retrieval (HIER) using Tris-EDTA/EGTA pH 9 (2/3) as HIER buffer. The mAb was typically diluted in the range of 1:200– 1:1.600 depending on the total sensitivity of the protocol employed. Using these protocol settings 3 of 3

(100 %) laboratories produced a sufficient staining.

Ready-To-Use Abs

mAb clone **4A4** (prod. no 760-4269/463M-17): The optimal protocols were based on HIER using Cell Conditioning 1 (Benchmark, Ventana), mild or standard, and an incubation time of 32 min. in the primary Ab using UltraView as the detection system. The protocol based on mild CC1 also used amplification kit. With these protocol settings 4 out of 4 (100 %) laboratories produced a sufficient staining.

mAb clone **BC4A4**, (prod. no PM163AA): The optimal protocol was based on HIER using Bond Epitope Retrieval Solution 2 (Bond, Leica) and an incubation time of 15 min in the primary Ab and BOND Polymer Refine Detection (DS9800) as the detection system.

The most frequent causes of insufficient stains were:

- Too low concentration of the primary antibody
- Too high concentration of the primary antibody

In the assessment and in concordance with the previous assessment of p63, run 16 2006, the general module, the prevalent feature of an insufficient staining was a generally too weak or false negative reaction of the cells expected to be demonstrated. Virtually all participants were capable of detecting p63 in the squamous epithelial cells in the tonsil and esophagus, whereas the insufficient results were characterized by a too weak staining in the myoepithelial cells in the normal breast glands and in the scattered neoplastic cells in the basal-like breast carcinoma. An insufficient staining was also seen as a false positive cytoplasmic reaction in virtually all cells and structures. This pattern was typically caused by a too high concentration of the primary Ab.

As control, tonsil displayed the most informative reaction pattern as a critical stain quality indicator for p63. In the optimal protocols virtually all the squamous epithelial cells showed a distinct moderate to strong nuclear reaction, but - more importantly - also scattered lymphocytes showed a distinct nuclear reaction. In the insufficient stains deemed too weak the lymphocytes were negative.

It has to be stressed that the most commonly used mAb clones 4A4 from Dako, NeoMarkers and Cell Margue/Ventana and the mAb clone cocktail 4A4 + Y4A3, NeoMarkers are not IVD labelled and only registered and sold as Research-Use-Only from these vendors. The mAb clone BC4A4 from BioCare was in this test the only IVD labelled product.

This was the second NordiQC assessment of p63 and in both assessments a very high proportion of sufficient results have been obtained as shown in table 2:

Table 2. **Proportion of sufficient results for p63 in the two NordiQC runs performed**

	Run 16 2006	Run B8 2009
Participants, n=	68	113
Sufficient results	83 %	95 %

Conclusion

The mAb clones 4A4, 4A4+Y4A3 and BC4A4 are all robust and recommendable Abs for p63. The clone BC4A4, BioCare is at present the only IVD labelled marker for p63. For all clones HIER is mandatory for an optimal performance. Tonsil is an appropriate control for p63: Virtually all the squamous epithelial cells as well as scattered lymphocytes must show a distinct nuclear staining. No or only a minimal cytoplasmic staining should be seen.

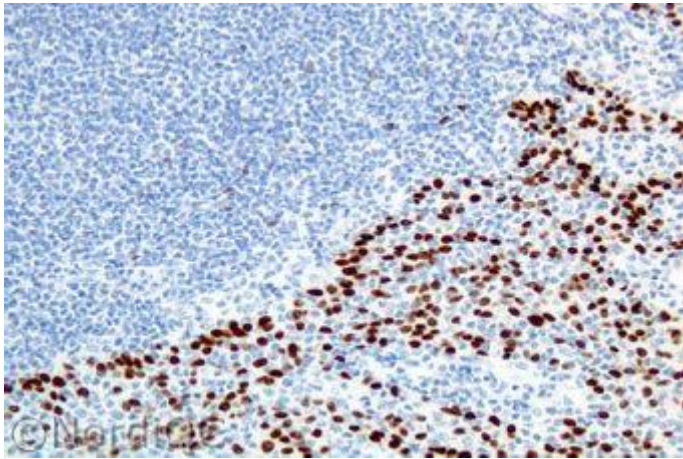


Fig. 1a
Optimal p63 staining of the tonsil using the mAb clone 4A4 correctly calibrated and with HIER in an alkaline buffer (Tris-EDTA pH 9). The majority of the squamous epithelial cells show a distinct moderate to strong nuclear staining. Also note the distinct nuclear reaction in scattered lymphocytes.

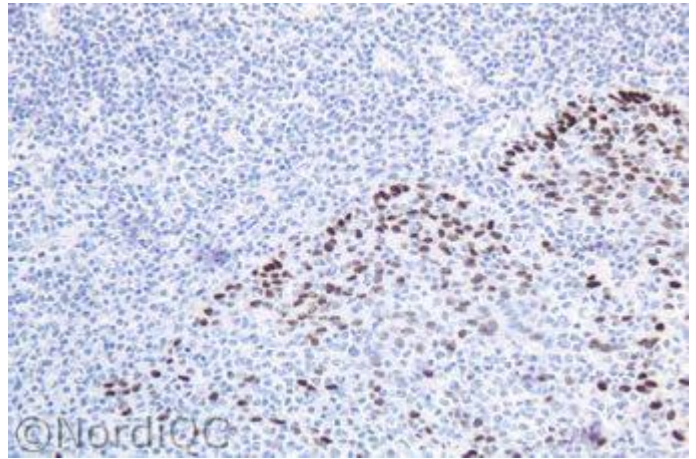


Fig. 1b
Insufficient p63 staining of the tonsil using the mAb clone 4A4 too diluted. The squamous epithelial cells are demonstrated, however the proportion and intensity is reduced compared to the staining in Fig. 1a, and the lymphocytes are virtually negative. Also compare with Figs. 2b & 3b - same protocol.

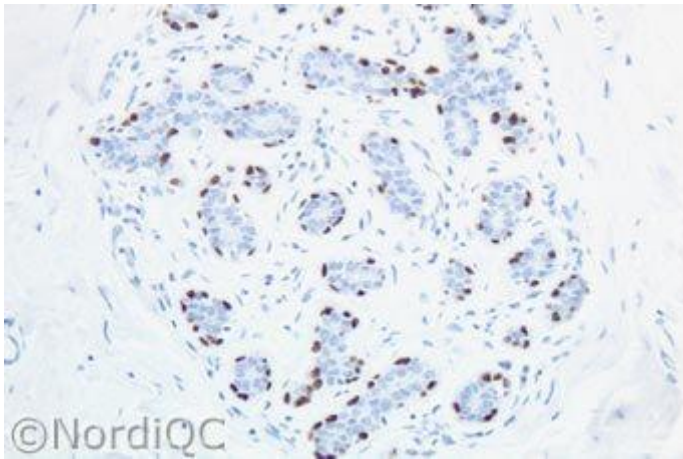


Fig. 2a
Optimal p63 staining of the breast hyperplasia using same protocol as in Fig. 1a. Virtually all the myoepithelial cells of the glands show a moderate to strong nuclear reaction with no background reaction.

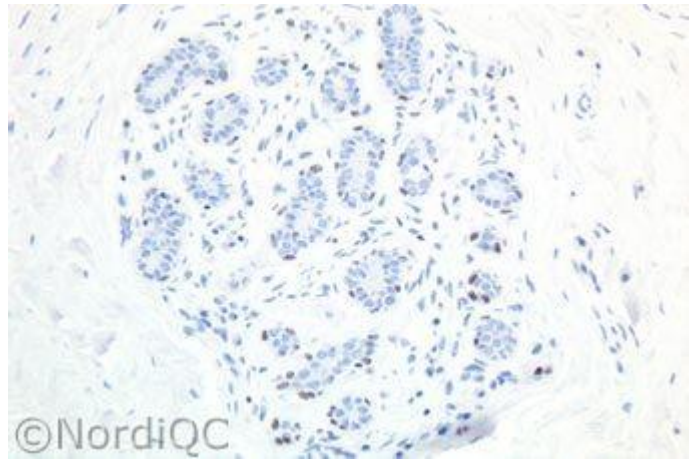


Fig. 2b
Insufficient p63 staining of the breast hyperplasia using same protocol as in Fig. 1b. The myoepithelial cells of the glands only show a weak nuclear staining.

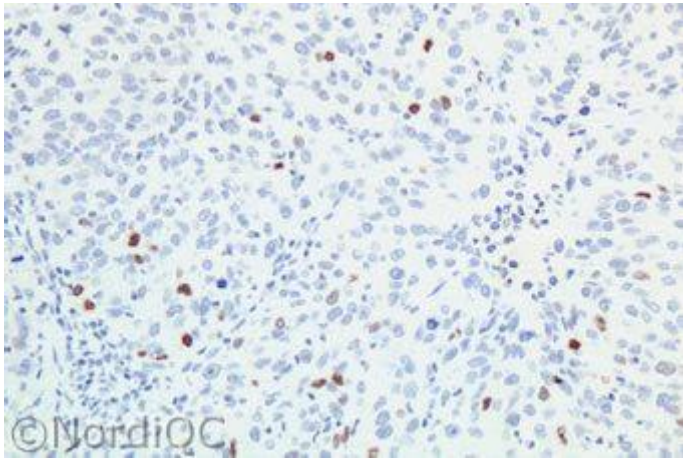


Fig. 3a
Optimal p63 staining of the basal-like breast carcinoma using same protocol as in Figs. 1a & 2a. Scattered neoplastic cells show a distinct nuclear staining.

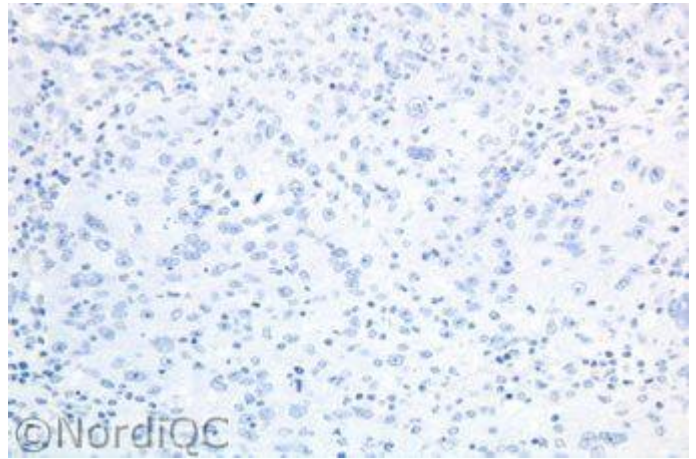


Fig. 3b
Insufficient p63 staining of the basal-like breast carcinoma using same protocol as in Figs. 1b & 2b. No nuclear staining is seen in the neoplastic cells.

SN/HN/MV/LE 4-12-2009